

# Endoscopic full-thickness resection of early colorectal neoplasms using an endoscopic submucosal dissection knife: a retrospective multicenter study



## Authors

Marie-Anne Guillaumot<sup>1</sup>, Maximilien Barret<sup>1</sup>, Jérémie Jacques<sup>2</sup>, Romain Legros<sup>2</sup>, Mathieu Pioche<sup>3</sup>, Jérôme Rivory<sup>3</sup>, Gabriel Rahmi<sup>4</sup>, Vincent Lepilliez<sup>5</sup>, Edouard Chabrun<sup>6</sup>, Sarah Leblanc<sup>1</sup>, Stanislas Chaussade<sup>1</sup>

## Institutions

- 1 Department of Gastroenterology and Digestive Oncology, Cochin Hospital, Assistance Publique – Hôpitaux de Paris, and University of Paris, France
- 2 Department of Gastroenterology, Limoges University Hospital, Limoges, France
- 3 Department of Gastroenterology, Edouard Herriot Hospital, Lyon, France
- 4 Department of Gastroenterology and Digestive Endoscopy, Georges Pompidou European Hospital, Assistance Publique – Hôpitaux de Paris, and University of Paris, France
- 5 Department of Gastroenterology, Ramsay Générale de Santé, Hôpital Privé Jean Mermoz, Lyon, France
- 6 Department of Endoscopy and Gastroenterology, Bordeaux University Hospital, Bordeaux, France

submitted 21.8.2019

accepted after revision 23.1.2020

## Bibliography

DOI <https://doi.org/10.1055/a-1127-3092> |  
Endoscopy International Open 2020; 08: E611–E616  
© Georg Thieme Verlag KG Stuttgart · New York  
eISSN 2196-9736

## Corresponding author

Maximilien Barret, Department of Gastroenterology and Digestive Oncology, Cochin Hospital, 27 Rue du Faubourg St Jacques, 75014 Paris, France  
Fax: +33(1)58411965  
[maximilien.barret@aphp.fr](mailto:maximilien.barret@aphp.fr)

## ABSTRACT

**Background and study aims** Endoscopic full-thickness resection allows resection of early gastrointestinal neoplasms not amenable to conventional endoscopic resection techniques, due to their location, presence of submucosal fibrosis, or suspected deep mural invasion. It is typically achieved using a dedicated over-the-scope device (full-thickness resection device or FTRD). The aim of our study was to evaluate the feasibility, safety, and clinical outcomes of endoscopic full-thickness resection using an endoscopic submucosal dissection (ESD) knife.

**Patients and methods** Consecutive patients who underwent full-thickness endoscopic resection at six tertiary care centers from August 2010 to June 2017 were retrospectively included. We conducted a comparative analysis of patient characteristics, technical success, adverse events, and time to discharge between patients treated by a full-thickness resection using an ESD knife.

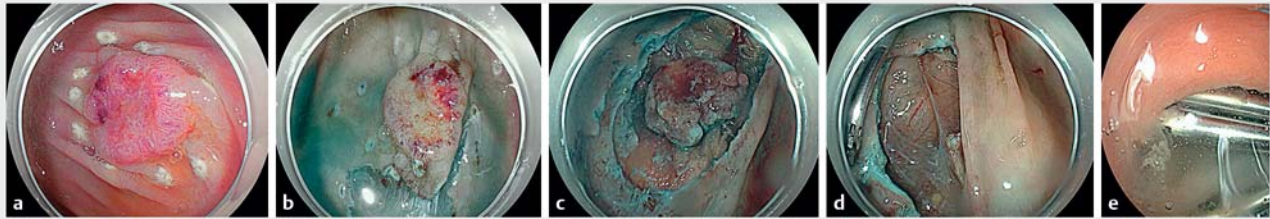
**Results** Twenty-one procedures were performed using an ESD knife. En-bloc resection and R0 resection rates were 95.2% and 65%, respectively. Clinical symptoms of perforation occurred in 66.7%. There was no need for surgery or additional endoscopic procedures.

**Conclusion** Endoscopic full-thickness resection of early colorectal neoplasms using an ESD knife might be feasible and safe. It allows complete resection of lesions with no limitation in size. The technique may be preferable to an other-the-scope resection device in lesions larger than 20 mm, and to surgery in selected cases of low-risk T1 colorectal carcinomas, non-lifting adenomas, submucosal tumors, or technically challenging lesion locations.

## Introduction

Endoscopic submucosal dissection (ESD) and endoscopic mucosal resection (EMR) are effective techniques for removal of early neoplasia of the gastrointestinal tract by separating submucosa and muscular layer [1–4]. In some situations, such as submucosal fibrosis, previous failed resection, or submucosal

invasion, these techniques may not achieve en bloc and histologically complete (R0) resection [5–8]. Endoscopic full-thickness resection could be a valid alternative to conventional surgery. The technique was inspired by the transanal endoscopic microsurgery (TEM) technique used by colorectal surgeons [9]. TEM consists of a full-thickness en bloc excision of a large rectal tumor down to the perirectal fat, with or without suture of the re-



► **Fig. 1** a Endoscopic full-thickness (transperietal) resection procedure. A Paris 0-Is+IIc lesion of the lower rectum was marked with an endoscopic submucosal dissection knife and the submucosal layer was injected (Panel 1A). b Mucosal incision was achieved and c submucosal dissection performed until reaching the muscularis propria. d Transperietal dissection was achieved, allowing en bloc resection of a T2 adenocarcinoma. e The resection bed was finally closed with clips.

section bed. The main advantage of TEM is avoiding risk of impairing rectal and genitourinary function as after proctectomy and complete mesorectal excision [10–15].

A clip-assisted endoscopic full-thickness resection device (FTRD) has been shown to be feasible for such lesions in retrospective studies [16–18] and one prospective study [19], but the technique is limited by its applicability to lesions <20 mm in size. Endoscopic full-thickness resection with an ESD knife performed by gastroenterologists would allow en bloc R0 resection with no limitation in terms of lesion location or size.

The aim of this retrospective multicenter study was to evaluate the feasibility, safety, and clinical outcomes of full-thickness resection with an ESD knife.

## Patients and methods

### Indications for full-thickness endoscopic resection

Indications for full-thickness endoscopic resection were as follows: (1) Invasive pattern on magnification chromoendoscopy and/or endoscopic ultrasound findings suggestive of deep submucosal infiltration; (2) prior endoscopic resection failure due to submucosal fibrosis or difficult lesion location; and (3) carcinoma or other subepithelial lesions.

### Periprocedural management

All procedures were performed in an inpatient setting under deep sedation with propofol or general anesthesia with endotracheal intubation. Patients received a single dose of intravenous prophylactic antibiotics according to local protocols.

All resections were performed by endoscopists with extensive experience in expertise in colonoscopy, EMR and ESD (>30 cases of colonic ESD).

All endoscopic procedures were performed with CO<sub>2</sub> insufflation. Before resection, diagnostic endoscopy was performed to characterize and measure the lesion and search for an invasive pattern. Lesion margins were delineated before beginning resection using coagulation markings or indigo carmine dye spraying. After resection, the specimen was immediately collected and the resection site was assessed to check completeness of resection and search for active bleeding.

All patients were discharged minimally at postoperative day 1 and were monitored clinically for signs of bleeding or perforation.

### Endoscopic full-thickness resection technique

Submucosal lifting was attempted using indigo-carminestained saline, or a lifting solution made of 5% fructose and 10% glycerol mixed with saline. Then, a circumferential mucosal incision was made. Submucosal dissection was started and converted to a full-thickness resection when impossible to complete without opening the muscularis propria (► **Fig. 1**). Bleeding was controlled using hemostatic forceps, such as the Coagrasper (Olympus, Tokyo, Japan) in soft coagulation mode (50 W). Closure of the resection wound was achieved using hemoclips or an over the scope clip in the colon or proximal rectum. Desufflation of the capnoperitoneum was performed using a 14 G needle whenever necessary.

### Clinicopathological characteristics

Lesion locations were divided into six areas: rectum, sigmoid colon, descending colon, transverse colon, ascending colon, or cecum. Macroscopic tumor type was classified according to the Paris classification. The following parameters were collected: age, previous resection, tumor location, submucosal fibrosis, resection area, procedure time, and macroscopic type.

En bloc resection was defined as lesion removal in a single piece with macroscopically lesion-free lateral and vertical margins. R0 resection was defined as an en bloc resection with histologically complete resection, i. e. absence of neoplastic tissue at the lateral or vertical resection margins.

Clinical perforation was defined as abdominal pain, fever (temperature superior to 38.5 °C, and elevated biological inflammation markers (C-reactive protein superior to 5 mg/L and/or leucocytes superior to 10 000/mm<sup>3</sup>) after the procedure. Computed tomography scanning was used to confirm the diagnosis and rule out other complications.

Submucosal fibrosis was defined as a whitish, dense, tissue in the submucosa without any distension or color change after submucosal injection.

## Histopathologic workup evaluation

The specimens were examined to determine histologic type, depth of invasion, lymphovascular invasion, and lateral and vertical resection margins.

Curative resection of an adenocarcinoma was defined when all of the Japanese Classification for Cancer of the Colon and Rectum [20] criteria were met: lateral and vertical resection margins free of tumor, submucosal invasion <1,000 µm from the muscularis mucosae, absence of lymphatic or vascular involvement, or poorly differentiated component. Local pathologists at each center were in charge of the pathologic assessment.

## Statistical analysis

Data were summarized as median and range for discrete variables and as means and standard deviation for continuous variables, unless stated otherwise. Categorical variables are reported as percentages to describe proportions and continuous variables are reported as means. Demographics and outcomes of all patients treated by full-thickness resection with an ESD knife were recorded. Bivariate analysis was performed separately for each variable. *P* values were calculated by the Chi-square or Fisher exact test for discrete variables, by the *t*-test or Wilcoxon test for continuous variables. All patients provided written informed consent for the procedure and the publication of the data.

## Results

### Patients and lesions characteristics

From August 2010 to September 2017, 21 full-thickness endoscopic resections with an ESD knife were performed in six centers. Patient characteristics are presented in ► **Table 1**.

Eight lesions were treated with Triangle Tip knife (Olympus, Tokyo, Japan), three with Hybrid-knife T-type (Erbe, Tübingen, Germany), five with Dual knife (Olympus, Tokyo, Japan), and five lesions with Jet knife (Olympus, Tokyo, Japan). Median procedure time was 126 min (range = 95–270). Median age was 68 years (range = 38–85 years). Two patients were on anticoagulants and three patients were on antiplatelet therapy. Lesions were located in the rectum in 76.2% of patients (16/21), in the sigmoid colon in 14.3% (3/21), and in the right colon in 9.5% (2/21). For lesions located in the rectum, they were respectively located in the distal rectum (<5 cm from the anal verge), in the mid rectum (5–10 cm) and in the proximal rectum (>10 cm) in five, three and one cases; seven cases of rectal lesions were not precisely located.

Overall, 52% of the lesions (11/21) were recurrences occurring following an EMR or an ESD of a colorectal adenoma. Lesions were categorized according to the Paris classification as type 0-Is (2/21) or 0-II lesions (17/21), or as subepithelial lesions (2/21). A macronodule was observed in 38% of lesions (8/21).

Endoscopists considered pit pattern to be invasive in 43% of lesions (9/21). Mean (±SD) size of resected lesions was 35.5 ± 21 mm (range: 10–95 mm).

► **Table 1** Baseline characteristics of 21 neoplastic colorectal lesions in 21 patients treated by endoscopic full-thickness resection using an ESD knife.

	n = 21
Age – mean ± SD (range), years	65.6 ± 10.5 (38–85)
Male/female ratio	11/10
Anticoagulant/Antithrombotic use – n	2/3
Prior therapeutics – n (%)	11 (52)
Location – n	
▪ Appendix/cecum/right/transverse/left/sigmoid/rectum	0/0/2/0/0/3/16
▪ Colon vs. rectum	5 (23.8) vs. 16 (76.2)
Indication for resection – n (%)	
▪ Failed prior resection attempt	15 (71.4)
▪ Invasive pattern	4 (19)
▪ Submucosal lesion	2 (9.5)
▪ Intra diverticular lesion or appendicular lesion	0
Size – Mean ± SD size (range), mm	46.2 ± 2.1 (10–95)
Paris classification subtype – n	
Is/IIa/Is + IIa/IIa + IIb/IIa + IIc/IIb/IIc/ Is + IIc/ Subepithelial tumor	3/3/5/0/3/0/3/3/1

ESD, endoscopic submucosal dissection; SD, standard deviation

### Technical feasibility and en bloc resection rate

Full-thickness resection with an ESD knife was indicated based on signs of deep mural invasion in 57.1% (12/21), prior failed ESD in 33.3% (7/21) and submucosal lesions 9.5% (2/21). In four of seven cases of failed ESD, submucosal fibrosis was attributable to prior endoscopic resection attempts with scarring. Lesions with signs of deep submucosal infiltration were adenocarcinomas in 11 of 12 cases.

Full-thickness resection was achieved in 100% (21/21) and presence of serosa or serous or peritoneal fat was described by the pathologist in three cases. In 23.8% of cases (5/21), the resection bed was closed by conventional hemoclips (4/5) or an over-the-scope clip (Ovesco, Ovesco Endoscopy AG, Tübingen, Germany) (1/5).

En bloc resection was achieved in 90.1% (19/21), piecemeal resection in 9.5% (2/21). Plasma argon or coagulation was used as complementary treatment for macroscopically positive margins in 9.5% (2/21). Details of the endoscopic procedures are listed in ► **Table 2**.

### Histologic and technical outcomes

Histologic analysis showed adenoma in 28.6% (6/21), with low-grade dysplasia and high-grade dysplasia in one and five cases, respectively. Adenocarcinoma was reported in 61.9% (13/21), neuroendocrine tumor in 4.7% (1/21), and no neoplastic tissue

► **Table 2** Therapeutic outcomes after full-thickness resection of 21 early colorectal neoplasms using an ESD knife.

	n=21
Successful resection rate – n (%)	21 (100)
En bloc resection rate – n (%)	19 (95.2)
R0 resection rate – n (%)	13 (65)
Curative resection rate for carcinoma – n (%)	2 (15.4)
Surgery for cancer – n (%)	5 (38.4)
Admission time – Mean ± SD, (range), days	3.1 ± 1.95 (1–8)
Complications – n (%)	
▪ Clinical perforation	14 (66.7) 14 (66.7)
▪ Per-endoscopic desufflation/medical/surgical treatment	2/12/0
▪ Delayed bleeding	0 (0)
ESD, endoscopic submucosal dissection	

was found on the specimen in 4.7% of cases (1/21). The carcinoma was intramucosal or Tis in 9.5% (2/21), submucosal in 23.8% (5/21), T2 in 23.8% (5/21), T3 in 4.7% (1/21). Histology of carcinoma was documented before the resection procedure in only 3 cases.

Resection was histologically complete (R0 resection) in 61.9% of patients (13/21). Positive deep resection margins (for adenocarcinoma) were found in two patients and positive lateral margins (with high grade dysplasia) in six. The two piecemeal resections were classified R1. Finally, among the 13 lesions containing adenocarcinoma, only two resections were considered curative according to the Japanese criteria, as shown in ► **Table 3**.

### Adverse events

Clinical perforation occurred in 66.7% of cases (14/21). All patients improved with conservative treatment, including fasting and antibiotics. The need for per-procedural desufflation was not considered as a clinical perforation if no clinical consequence occurred in the following hours. No delayed bleeding requiring blood transfusion or endoscopic treatment was observed. Mean time to discharge was 3.1 ± 2 days. All complications were managed conservatively and there was no need for surgical intervention. No procedure-related mortality was observed.

### Oncologic outcomes of patients with colorectal adenocarcinomas

In 11 of 13 resected cancers, resection was histologically incomplete and, therefore, found to be oncologically inadequate. Additional surgery or radiotherapy was recommended by the local multidisciplinary meeting. Surgical resection was actually performed in seven patients (4 with en bloc and histologically complete resections of a carcinoma with deep submucosal invasion, 2 with positive deep resection margins, 1 with positive

► **Table 3** Histopathologic findings in 21 neoplastic colorectal lesions managed by full-thickness resection using an ESD knife.

	n=21
Adenoma – n (%)	6 (28.6)
Cancer – n (%)	13 (62)
Tumor infiltration – n (%)	
▪ Tis	2 (9.5)
▪ T1 superficial <sup>1</sup>	1 (4.8)
▪ T1 deep <sup>2</sup>	4 (19)
▪ T2	5 (23.8)
▪ T3	1 (4.8)
Lymphovascular involvement – n (%)	4 (30.7)
Undifferentiated adenocarcinoma – n (%)	1 (7.6)
GIST/NET – n (%)	1 (7.6)
Absence of neoplasia – n (%)	1 (7.6)
ESD, endoscopic submucosal dissection; GIST/NET, gastrointestinal stromal tumor/neuroendocrine tumor	
<sup>1</sup> Superficial submucosal infiltration < 1000 micrometers	
<sup>2</sup> Deep submucosal infiltration > 1000 micrometers	

lateral margin). Overall, six of seven patients were pT0N0, including the three R1 resections, after surgery. Chemoradiotherapy was performed in one patient and in another patient before surgery. Two patients did not undergo surgical resection due to heavy comorbid conditions.

## Discussion

This is the first study on endoscopic full-thickness resection with an ESD knife in the colon and rectum. The study mainly included previously treated lesions in which the submucosal fibrosis caused by the initial resection attempt makes the procedure challenging with low rates of histologically complete resection achieved by endoscopy [5, 21]. Endoscopic full-thickness resection could be an interesting alternative to conventional surgery.

In this retrospective multicenter study, we found that endoscopic full-thickness resection performed using an ESD knife was feasible, achieving an en-bloc resection rate of 95.2% and a R0 resection rate of 65%, without severe complications. The clinical perforation rate of 66.7% is higher than reported after colorectal ESD or TEM. It is extremely high due to our non-restrictive definition of clinical perforation. However, each case was treated conservatively with antibiotics, pain medication and fasting, without any need for surgery or another endoscopy. Local perforation of the colorectal wall is inherent to the technique and clinical manifestations with an inflammatory response should be expected. Also, mean time to discharge of 3 days is similar to other complex endoscopic procedures: mean reported hospital stay after colorectal ESD and TEM is 3 to 5 days [22, 23] and 5 to 8 days, respectively [12, 24, 25], respec-

tively. In the future, use of novel endoscopic techniques of full-thickness suturing could further decrease the rate of complications [26, 27].

R0 resections rates of FTR using an ESD knife were slightly lower than the numbers reported using FTRD, ranging from 79% to 87% [19, 28, 29]. Also, FTRD induces less complications, in particular a lower rate clinical perforation, due to the immediate and safe closure of the colon. However, FTRD has two important limitations: first, the cap limits the maximum size of the lesion that can be resected and the visibility of the lateral margins during the resection, potentially increasing the risk of histologically incomplete resection [19]; second, treatment of a recurrence after use of the FTRD technique could be extremely challenging for an endoscopist because of the clip.

Of note, seven patients had T2 or T3 pathology on the resection specimen. This can be explained by a more difficult optical prediction of deep mural invasion in previously treated lesions. However, because three patients were unfit for surgery, endoscopic resection was the only possible curative treatment for them. Six of seven patients who underwent surgery had a tumor-free (pT0N0) specimen and did not actually benefit from surgical treatment. Full-thickness endoscopic resection could indeed be preferred for patients with contraindications of surgery. The decision for surgical resection was essentially based on risk of lymphatic invasion and the necessity to perform a concomitant lymphadenectomy. Preoperative evaluation of perirectal lymph nodes by endoscopic ultrasound and magnetic resonance imaging is challenging and development of more sensitive tools to detect positive perirectal lymph nodes, such as surgical perirectal lymph node sampling [30] or sentinel lymph node biopsy, could help identify patients who will actually benefit from surgical resection [31]. Larger studies are awaited to help identify indications and determine oncologic outcomes of these procedures.

This study was limited by its retrospective nature, introducing possible selection biases, and the small number of patients. Furthermore, only expert endoscopists were involved, calling into question generalizability of the results. The relatively high rate of secondary surgical indications (47.6%) should be put into perspective with the selection bias towards lesions difficult to treat endoscopically.

## Conclusion

In conclusion, our data support that endoscopic full thickness resection in the colon and rectum using an ESD knife might be a feasible, safe, and promising resection technique. It allows complete resection of neoplastic lesions without limitation in size. The technique may be preferable to FTRD for lesions >20 mm, and to surgery in selected cases of low-risk T1 colorectal carcinomas, non-lifting adenomas with failure of conventional endoscopic resection techniques, subepithelial tumors, and lesions in difficult-to-reach locations. The possible benefit of a full-thickness resection with a knife over the FTRD for large rectal lesions needs to be confirmed by further studies.

## Competing interests

The authors declare that they have no conflict of interest.

## References

- [1] Raju GS, Lum PJ, Ross WA et al. Outcome of EMR as an alternative to surgery in patients with complex colon polyps. *Gastrointest Endosc* 2016; 84: 315–325
- [2] Moss A, Williams SJ, Hourigan LF et al. Long-term adenoma recurrence following wide-field endoscopic mucosal resection (WF-EMR) for advanced colonic mucosal neoplasia is infrequent: results and risk factors in 1000 cases from the Australian Colonic EMR (ACE) study. *Gut* 2015; 64: 57–65
- [3] Oka S, Tanaka S, Saito Y et al. Local recurrence after endoscopic resection for large colorectal neoplasia: a multicenter prospective study in Japan. *Am J Gastroenterol* 2015; 110: 697–707
- [4] Burgess NG, Bourke MJ. Endoscopic resection of colorectal lesions: The narrowing divide between East and West. *Dig Endosc Off J Jpn Gastroenterol Endosc Soc* 2016; 28: 296–305
- [5] Mizushima T, Kato M, Iwanaga I et al. Technical difficulty according to location, and risk factors for perforation, in endoscopic submucosal dissection of colorectal tumors. *Surg Endosc* 2015; 29: 133–139
- [6] Hong SN, Byeon JS, Lee B-I et al. Prediction model and risk score for perforation in patients undergoing colorectal endoscopic submucosal dissection. *Gastrointest Endosc* 2016; 84: 98–108
- [7] Xu J-F, Yang L, Jin P et al. Endoscopic approach for superficial colorectal neoplasms. *Gastrointest Tumors* 2016; 3: 69–80
- [8] Iacopini F, Saito Y, Bella A et al. Colorectal endoscopic submucosal dissection: predictors and neoplasm-related gradients of difficulty. *Endosc Int Open* 2017; 5: E839–E846
- [9] Buess G. Review: transanal endoscopic microsurgery (TEM). *J R Coll Surg Edinb* 1993; 38: 239–245
- [10] Casadesus D. Surgical resection of rectal adenoma: a rapid review. *World J Gastroenterol* 2009; 15: 3851–3854
- [11] Bach SP, Hill J, Monson JRT et al. A predictive model for local recurrence after transanal endoscopic microsurgery for rectal cancer. *Br J Surg* 2009; 96: 280–290
- [12] Allaix ME, Arezzo A, Caldart M et al. Transanal endoscopic microsurgery for rectal neoplasms: experience of 300 consecutive cases. *Dis Colon Rectum* 2009; 52: 1831–1836
- [13] Morino M, Allaix ME, Caldart M et al. Risk factors for recurrence after transanal endoscopic microsurgery for rectal malignant neoplasm. *Surg Endosc* 2011; 25: 3683–3690
- [14] Serra-Aracil X, Mora-Lopez L, Alcantara-Moral M et al. Transanal endoscopic surgery in rectal cancer. *World J Gastroenterol* 2014; 20: 11538–11545
- [15] Allaix ME, Arezzo A, Morino M. Transanal endoscopic microsurgery for rectal cancer: T1 and beyond? An evidence-based review *Surg Endosc* 2016; 30: 4841–4852
- [16] Schmidt A, Bauerfeind P, Gubler C et al. Endoscopic full-thickness resection in the colorectum with a novel over-the-scope device: first experience. *Endoscopy* 2015; 47: 719–725
- [17] Schmidt A, Riecken B, Damm M et al. Endoscopic removal of over-the-scope clips using a novel cutting device: a retrospective case series. *Endoscopy* 2014; 46: 762–766
- [18] Richter-Schrag H-J, Walker C, Thimme R et al. Full thickness resection device (FTRD). Experience and outcome for benign neoplasms of the rectum and colon. *Chir Z Alle Geb Oper Medizin* 2016; 87: 316–325



- [19] Schmidt A, Beyna T, Schumacher B et al. Colonoscopic full-thickness resection using an over-the-scope device: a prospective multicentre study in various indications. *Gut* 2018; 67: 1280–1289
- [20] Watanabe T, Itabashi M, Shimada Y et al. Japanese Society for Cancer of the Colon and Rectum (JSCCR) guidelines 2010 for the treatment of colorectal cancer. *Int J Clin Oncol* 2012; 17: 1–29
- [21] Agapov M, Dvoynikova E. Factors predicting clinical outcomes of endoscopic submucosal dissection in the rectum and sigmoid colon during the learning curve. *Endosc Int Open* 2014; 2: E235–E240
- [22] Youk E-G, Sohn DK, Hong CW et al. Early outcomes of endoscopic submucosal dissection for colorectal neoplasms according to clinical indications. *Dis Colon Rectum* 2016; 59: 403–410
- [23] Tomiki Y, Kawai M, Takehara K et al. Clinical pathway to discharge 3 days after colorectal endoscopic submucosal dissection. *Dig Endosc* 2015; 27: 679–686
- [24] Baatrup G, Borschitz T, Cunningham C et al. Perforation into the peritoneal cavity during transanal endoscopic microsurgery for rectal cancer is not associated with major complications or oncological compromise. *Surg Endosc* 2009; 23: 2680–2683
- [25] Palma P, Horisberger K, Joos A et al. Local excision of early rectal cancer: is transanal endoscopic microsurgery an alternative to radical surgery? *Rev Espanola Enfermedades Dig Organo Of Soc Espanola Patol Dig* 2009; 101: 172–178
- [26] Stavropoulos SN, Modayil R, Friedel D. Current applications of endoscopic suturing. *World J Gastrointest Endosc* 2015; 7: 777–789
- [27] Sharaiha RZ, Kedia P, Kumta N et al. Initial experience with endoscopic sleeve gastropasty: technical success and reproducibility in the bariatric population. *Endoscopy* 2015; 47: 164–166
- [28] Valli PV, Mertens J, Bauerfeind P. Safe and successful resection of difficult GI lesions using a novel single-step full-thickness resection device (FTRD®). *Surg Endosc* 2018; 32: 289–299
- [29] Van der Spek B, Haasnoot K, Meischl C et al. Endoscopic full-thickness resection in the colorectum: a single-center case series evaluating indication, efficacy and safety. *Endosc Int Open* 2018; 6: E1227–E1234
- [30] Zerz A, Müller-Stich BP, Beck J et al. Endoscopic posterior mesorectal resection after transanal local excision of T1 carcinomas of the lower third of the rectum. *Dis Colon Rectum* 2006; 49: 919–924
- [31] Van der Pas MH, Meijer S, Hoekstra OS et al. Sentinel-lymph-node procedure in colon and rectal cancer: a systematic review and meta-analysis. *Lancet Oncol* 2011; 12: 540–550