Article published online: 2020-05-12

Low-Field Magnetic Resonance Imaging

Niederfeld-Magnetresonanztomografie

Author
Hans-Martin Klein

Affiliation
MRI, Medical Center Siegerland Airport, Burbach, Germany

Key words
safety, technical aspects, physics, MR imaging

received 21.11.2019
accepted 23.01.2020

Bibliography
DOI https://doi.org/10.1055/a-1123-7944
Published online: 12.5.2020
Fortschr Röntgenstr 2020; 192: 537–548
© Georg Thieme Verlag KG, Stuttgart · New York
ISSN 1438-9029

Correspondence
Herr Prof. Hans-Martin Klein
MRT, Medizinisches Zentrum Am Siegerlandflughafen,
Flughafenstr. 2a, 57299 Burbach, Germany
Tel.: ++ 49/27 36/4 49 00 10
Fax: ++ 49/27 36/4 49 00 11
mklein@greenscan-imaging.de

ABSTRACT

Background For more than two decades, the focus of technological progress in MRI was restricted to systems with a field strength of 1.5 T and higher. Low- and mid-field MRI systems, which offer some specific advantages, are vanishing from the market. This article is intended to initiate a re-evaluation of the factor 'field strength' in MR imaging.

Method Literature review was carried out using MEDLINE database (via Pubmed) over a time span from 1980 to 2019 using free-text and Medical Subject headings (MeSH). Article selection was based on relevance and evidence.

Results and Conclusion Low-field MR systems are meanwhile rare in clinical imaging. MRI systems with a lower field strength provide a reduced signal-noise ratio (SNR) and spectral differentiation. However, these systems offer a variety of advantages: Shorter T1 relaxation, better T1 contrast, fewer metal artifacts, reduced susceptibility and chemical shift artifacts, fewer dielectric effects, better tissue penetration, less RF-power deposition, fewer 'missile effects', reduced effect on biomedical implants such as shunt valves, less energy and helium consumption. If we free ourselves from the constraints of high-field strength, we are able to offer multiple medical, economic and ecologic advantages to our patients. The development of high-quality low-field MRI is possible and necessary.

Key Points:

- Static magnetic field strength is only one of many parameters influencing image quality in MR imaging.
- Lower field strength results in a lower signal-to-noise ratio (SNR).
- Modern MR systems offer technical tools to improve signal strength and reduce noise. This makes it possible to provide a diagnostic SNR at a lower field strength.
- Low-field MR systems offer important advantages which have to be made available to our patients.

Citation Format

- Klein H-M. Low-Field Magnetic Resonance Imaging. Fortschr Röntgenstr 2020; 192: 537–548

ZUSAMMENFASSUNG

Hintergrund Seit mehr als zwei Dekaden liegt der Schwerpunkt der Entwicklung in der MRT-Tomografie im Bereich von Systemen mit Feldstärken von 1,5 T und mehr. MR-Tomografen mit Feldstärken unter 0,5 T, die eine Reihe von spezifischen Vorteilen bieten, sind aus dem klinischen Alltag nahezu verschwunden. Der Artikel soll eine Neubewertung der Bedeutung des Faktors „Feldstärke" anregen.

Methode Die Literaturrecherche erfolgte in der Datenbank Medline (PubMed) im Suchzeitraum 1980–2019 mittels Freitext- und Schlagwortsuche (MeSH). Die Auswahl der Artikel erfolgte entsprechend der Relevanz und, sofern verfügbar, dem Evidenzgrad.

Ergebnisse und Schlussfolgerung Nachteile von MRT mit geringerer Feldstärke sind ein geringeres Signal-Rausch-Verhältnis (SNR) sowie eine reduzierte spektrale Differenzierung. Dafür bieten diese Systeme eine Vielzahl von Vorteilen, die derzeit nicht oder nicht genügend genutzt werden: Kürzere T1-Relaxationszeit, besserer T1-Kontrast, weniger Metallartefakte, weniger Suszeptibilitätsartefakte, geringere dielektrische Effekte, bessere Gewebetransmission, geringere HF-Energiebelastung, weniger Gefährdung durch Anziehung metallischer Objekte („missile effects"), geringerer Effekt auf biomedizinische Implantate wie Shuntventile etc., geringerer Energieverbrauch, geringerer oder kein Heliumverbrauch. Wenn wir uns von der Vorstellung befreien, dass nur MRT mit mehr als 1,5 T Feldstärke klinisch geeignet sind, können wir eine Vielzahl medizinischer, ökonomischer und ökologischer Vorteile für unsere Patienten verfügbar machen. Die Entwicklung hochwertiger MRT mit geringerer Feldstärke ist möglich und notwendig.

This document was downloaded for personal use only. Unauthorized distribution is strictly prohibited.

Introduction

MRI is based on the resonance absorption of high-frequency electromagnetic waves of protons of body tissue in a strong static magnetic field. This signal has a very low amplitude. It becomes stronger when the strength of the surrounding magnetic field increases.

In the early years of MRI, there were two technical concepts for generating a static magnetic field. The available field strength of both was limited.

One method involved the use of C-shaped permanent magnets with a static field perpendicular to the longitudinal axis of the patient. These were easy to manufacture and had a long service life but were very heavy. The heavy weight made it difficult to use these magnets at higher field strengths. Permanent magnets cannot be switched off or demagnetized. The field is permanently present.

The other method involved the use of electromagnets with the patient positioned in the magnetic coil and the field running along the longitudinal axis of the patient. These magnets were lighter but had high energy consumption.

In the mid-1980 s, the first MRI units with a new generation of superconductive magnets were introduced at hospitals.

Certain materials cooled with liquid helium at temperatures close to absolute zero show a loss of the ohmic resistance. They become superconductive. Superconductive magnets made it possible to generate static fields multiple times the previously possible field strength.

This resulted in a discussion between the proponents of systems with a low field strength and a high field strength. Peter Rinck aptly referred to this as the "field strength war" [1]. Although there were good arguments for lower field strengths [2], the superconductive systems became the new standard due to the better image quality [3]. In the year 2000, the percentage of MRI systems with a field strength < 1.5 T was approximately 30 %, while it is approximately 5 % today. The market share of 3 T systems increased from 0 % to approximately 30 % in this time period.

A number of technical improvements were developed in the following years. Superconductive magnets became more compact and more open. In 2003, field strengths of more than 2 T were classified as safe for humans [4]. In 2009, the limit was increased to 4 T. The FDA currently classifies field strengths of up to 8 T as safe in patients older than 1 year.

Clinical MRI allows field strengths of up to 10.5 T [5, 6]. Preclinical ultra-high-field MRI of up to 21 T is available.

A field strength of 1.5 T to 3 T can be considered the current clinical standard.

The quality of the HF transmit and receive components has been continuously improved. The gradient amplitudes increased greatly. Instead of the linearly polarized or quadrature coils commonly used in the past, array coils with a high number of elements were developed, resulting in a significant improvement in the signal-to-noise ratio [7].

Since the focus was on the development of high-field systems, most of these improvements in low-field systems have not yet or have only partially been applied to date.

Magnetic resonance imaging is similar to a piano: For 25 years, radiologists have been limited to the upper half of the keyboard. Perhaps it is time to turn our attention back to the lower half.

To quote a great radiologist: "It is fun to play the entire piano!" [8].

Physical aspects of low-field imaging

As a rule, it is possible to use the earth's magnetic field for magnetic resonance imaging [9]. The increase in field strength results in a plurality of physical effects that can be advantageous but can also have a negative effect. In particular, the increase in the signal-to-noise ratio and the better spectral separation are advantageous. Among other things, the higher specific absorbed HF dose (SAR), susceptibility artifacts, an extension of the T1 time, and reduced T1 contrast are disadvantageous [2, 10].

Field strength-specific differences between high-field and low-field systems and their use or compensation are addressed in the following.

Magnet

Permanent magnets have a C-shaped iron yoke with two attached magnets positioned vertically one above the other that are typically made of neodymium-doped stainless steel. Magnetic field B_0 runs perpendicular to the longitudinal axis of the patient.

The advantages of permanent magnets include their reliability, minimal energy consumption, and long service life of up to 100 years.

Another advantage of the vertically oriented main field results from the send/receive-coil technique. Primarily solenoid or Helmholtz coils were used until the end of the 1990 s. These coils have the greatest extension of the measurement field perpendicular to the coil plane. Since the measurement coils must be positioned perpendicular to main magnetic field B_0, such loop coils can be optimally positioned around the body part to be examined for most organ regions.

In the case of tunnel-type electromagnets, the patient is positioned in the coil. Magnetic field B_0 runs along the longitudinal axis of the patient. The development of superconductive magnets made significantly higher field strengths possible.

While solenoid coils were suitable for systems with a vertically oriented field, tunnel systems are ideally suited for the multichannel and array coils developed in the late 1990 s [11].

An important image quality parameter is the homogeneity of the magnetic field. For examination of social insured patients in Germany, the provisions of the official Magnetic Resonance Imaging Agreement require a homogeneity of < 5 ppm, measured peak-to-peak, in a 40-cm spherical phantom [12]. This requirement is based on spatial encoding. By using gradient fields, the local field strength is modulated so that every resonance frequency is clearly allocated to one location. An inhomogeneous static field affects the accuracy of the spatial allocation.

Spectral fat suppression is dependent on good homogeneity. At a field strength of 0.35 T with a resonance frequency of

This document was downloaded for personal use only. Unauthorized distribution is strictly prohibited.

14.9 MHz, the difference in the resonance frequency of fat and water protons is only approximately 50 Hz.

Modern open permanent magnets can theoretically fulfill the quality requirements of the Magnetic Resonance Imaging Agreement. However, a 40-cm sphere does not fit in clinically available measurement coils so that the formal requirement cannot be fulfilled even if the homogeneity in the actual measurement field is sufficient.

The system's maximum homogeneity is in the middle of the magnetic field. Since open MRI units allow more flexible positioning of the patient, the peripheral inhomogeneity of the field can be partially compensated by optimized positioning. A shoulder examination is performed in the center of the field in open systems and at the edge of the coil in closed systems.

The attraction of metallic objects increases proportional to the square of the field strength. Therefore, surgical interventions and anesthesiological measures can be conducted more safely and more easily in the case of low-field MRI.

The effect of biomedical implants, such as shunt valves and pain pumps, is also typically significantly lower [13].

Signal and noise

The signal-to-noise ratio (SNR) and the spatial and temporal resolution are the main factors in image quality. The signal increases proportional to the square of the field strength. Therefore, a 1.5 T unit theoretically has approximately nine times the signal strength of a 0.5 T system.

Under otherwise identical conditions, the noise increases linearly with the field strength in the first approximation. The signal-to-noise ratio thus also increases approximately proportional to the field strength.

However, an increase in field strength results in a series of phenomena resulting in a disproportionately low increase in the SNR. High-field systems use stronger gradients. Receiver bandwidth bw_e is proportional to the gradient amplitude. The SNR is proportional to $1/\sqrt{bw_e}$. It decreases as the bandwidth increases.

Moreover, the T1 time increases with the field strength. The SNR is proportional to [1-exp (-TR/T1)]. Thus, an extension of T1 decreases the SNR as long as T1 ≤TR [14].

A number of parameters play a role in the signal-to-noise ratio: Gradient performance, receiver bandwidth, echo spacing, voxel size (spatial resolution, matrix, slice thickness), coil shape and configuration (multichannel coils), signal processing (reduction of noise components with optimized HF transmitter and receiver, A/D conversion close to the coil) and signal cable (optical media), signal optimization with K-space segmentation.

The diameter and conductivity of the examined region are also significant since the attenuation of electromagnetic energy is lower at a lower resonance frequency and thus a greater wavelength. Compared to high-field systems, low-field units therefore have advantages when examining the chest and abdomen [15].

There are numerous ways to improve the SNR, regardless of the field strength.

Relaxation times

At a low field strength, the T1 relaxation (longitudinal or spin-lattice relaxation) accelerates. The T1 difference between different tissues, like gray and white brain matter, is greater at a lower field strength [16]. Fischer et al. found an optimum T1 contrast (1/T1) at a frequency of 10 MHz corresponding to approximately 0.23 T [17].

The effect is comparable to mass absorption in radiography. The mass absorption coefficient decreases at a higher radiation energy. The T1 relaxation time of fluids seems to vary less at different field strengths.

Larmor frequency

The ratio between the resonance frequency of protons, expressed as angular speed ω and field strength B_0, is described in the Larmor equation:

$$\omega = \gamma * B_0.$$

Gyromagnetic constant γ for protons is 42.6 MHz/T. The higher angular speed and the resulting increase in resonance frequency has both a positive and a negative effect on imaging.

The higher angular speed of protons is advantageous for measurement sequences using phase effects, such as the in-phase/opposed phase technique for fat suppression. The correct echo time TE for the phase difference is shorter at a higher field strength (4.6 ms at 1.5 T, 2.3 ms at 3 T).

On the other hand, this effect is disadvantageous for measurements in which exact phase control is necessary, e. g. dynamic contrast-enhanced breast MRI, because the phase difference between in-phase and opposed phase imaging at 3.0 T is only 1.15 ms [18].

A higher resonance frequency requires an HF excitation pulse with a higher frequency. The higher the frequency and the shorter the wave of the HF pulse, the greater the HF energy that is absorbed by the body. Moreover, constructive and destructive superposition, which is facilitated by the shorter wavelength, plays a role [19]. This causes inhomogeneous excitation of the protons (also referred to as B_1-field inhomogeneity) with resulting signal inhomogeneity.

Moreover, there is greater heating of the tissue, and the maximum permissible high-frequency dose (SAR) is reached more quickly, resulting in a reduction of the available SNR [15].

The resonance frequency is minimally affected by the molecular surroundings of the protons. Protons bound in fat have a resonance frequency that deviates by 220 Hz at a field strength of 1.5 T. The effect can be used to suppress the fat component of the tissue by means of a frequency-selective saturation pulse or frequency-selective excitation. Such spectral fat saturation techniques are more robust at higher field strengths given corresponding field homogeneity. At 0.35 T, the spectral difference between fat and water protons is only approximately 51 Hz. However, the lower susceptibility effects resulting in lower field inhomogeneities are advantageous here.

This document was downloaded for personal use only. Unauthorized distribution is strictly prohibited.

An effect referred to as a "chemical shift" describes the formation of line artifacts, e. g. at fat-water interfaces. This effect is also reduced at lower field strengths.

A major advantage of higher field strengths and the resulting resonance frequency differences is seen in MR spectroscopy. However, the better spectral separation of the tissue molecules is partly compensated by broader spectral lines as a consequence of the shorter T2* time.

Contrast agent

The principle of action of contrast agents containing Gd is the shortening of the T1 time. The relaxivity, the degree of T1 shortening, is dependent on the field strength. While the effect between 1.0 T and 5.0 T is relatively constant, the contrast agent effect is significantly smaller at lower field strengths with a shorter primary T1 time. Accordingly, increased contrast enhancement is more visible in high-field MRI than low-field MRI [20].

There are only a few reports on contrast-enhanced MR angiography (CE-MRA) using low-field MRI systems since most systems are not capable of measuring sequences with a sufficiently short echo time. The diagnostic performance was comparable in our own study [21].

Susceptibility

The term "susceptibility" describes the magnetizability of materials or tissues, i. e., the ability to develop a local field in an external magnetic field. The local field of body tissue is superimposed on the external magnetic field with a strength determined by the particular susceptibility.

Most body tissues are diamagnetic, i. e., they slightly weaken the local magnetic field. Paramagnetic substances such as contrast agents containing gadolinium enhance the local magnetic field and thus the local field inhomogeneity.

Both weakening and enhancement of the field result in accelerated T1 signal decay and increased T1 signal intensity (contrast effect). Superparamagnetic substances like hemosiderin or ferrite (iron oxide) increase the local field strength more than paramagnetic substances. Ferromagnetic materials like iron or steel alloys generate a very strong field enhancement and significant image artifacts [22].

The susceptibility measurement can be used to detect small hemorrhages or hemosiderin deposits, e. g. in brain tissue or in the case of endometriosis. These susceptibility effects are greatly reduced at a lower field strength.

In the case of metallic implants, joint endoprostheses, aneurysm clips, etc., significantly better image quality can be achieved at a lower field strength [13]. A minimized TE time, maximum receiver bandwidth, orientation of the frequency encoding gradients along the longitudinal axis of the metal and, in the case of T2 weighting, the greatest possible echo train length (turbo factor) are important.

Dielectric effects

The wavelength of electromagnetic radiation is defined by frequency, speed of light, and the dielectricity constant of the tissue. At 3.0 T, the frequency is 128 MHz The resulting wavelength is 2.4 m in a vacuum. In weakly conductive (dielectric) tissues, the wavelength is lower. It is approximately 26 cm in water. The dielectricity of tissue affects the absorption and reflection of HF radiation in the body and thus the homogeneity of the magnetic conditions.

It can result in focusing of HF energy with much higher local energy deposition inside the body. Moreover, the high-frequency excitation waves can be reflected by structures with higher conductivity, such as the chest wall, abdominal wall, diaphragm, or biomedical implants (dielectric intracorporeal resonance) [19]. The dielectric resistance which increases at a higher field strength is the most important factor with respect to the increase in noise.

High-frequency exposure and specific absorption rate

The most important potentially harmful factor of MRI is high-frequency exposure. This increases approximately quadratically with respect to the field strength [15]. Primarily thermal effects are addressed in the literature [23]. There is evidence but no final assessment regarding DNA damage and genotoxic effects [24].

The maximum permissible HF energy absorbed by the body was 0.4 W/kg in the 1980 s. Following the development of superconductive high-field magnets, this value was changed to 4 W/kg. The goal is to prevent critical heating of body tissue.

In an experimental animal study, pigs were examined on a 3.0 T system for 30 or 60 minutes at 2.5 to 5.2 W/kg. Significant tissue damage occurred with the heat distribution measured in the tissue varying significantly which could be attributed to dielectric effects and insufficient local thermoregulation in the pig [25].

Compensation of low-field-specific problems

Noise

A reduction of the noise results in linear improvement of the SNR.

The room temperature plays an important role here since all electronic components have thermal noise.

The coil design is important as the basis for coil sensitivity. The temperature of the receiver components is also important. These can be cooled thus reducing the percentage of electronic noise.

The coil geometry is crucial. The better it is adapted to the size and shape of the body part to be examined, the better the "filling" of the coil and thus the signal-to-noise ratio.

An image improvement milestone was the introduction of parallel imaging and multi-element or array coils.

As a result of analog-digital conversion of the measured signal as close to the coil as possible or even in the coil, the signal loss and the increase in noise can be reduced significantly.

A frequently used noise reduction technique is to perform multiple measurements (signal averaging). Doubling the number of

This document was downloaded for personal use only. Unauthorized distribution is strictly prohibited.

measurements improves the SNR by the factor √2 with doubling of the measurement time (see below).

Filters that generate images with less noise but are not loss-free are used in image processing. Newer techniques like deep learning-supported reconstruction result in noise reduction without a loss of information [27].

Homogeneity

The homogeneity of the magnetic field is extremely important for image quality. Inhomogeneities result in less precise spatial allocation since the site of signal creation is encoded via the local resonance frequency. Moreover, spectral fat saturation methods are dependent on a homogeneous magnet field.

If homogeneity is not sufficiently ensured, water-excitation sequences can alternatively be used in low-field MRI [26].

Low-field MRI using permanent magnets requires a particularly complicated correction process (shimming). Prior to examinations with high homogeneity requirements (e. g. Dixon sequences), a new individual correction can be performed.

Measurement time

Given otherwise identical conditions, doubling of the field strength from 0.5 T to 1.0 T theoretically results in quadrupling of the signal and doubling of the SNR. Doubling of the measurement time correspondingly improves the SNR by the factor √2. Cutting the field strength in half can thus be compensated by quadrupling the measurement time.

In practice, depending on the sequence being used, an increase in the SNR that is disproportionately small with respect to the field strength can be assumed. As described, this is due to the effects of T1 extension, dielectric effects, and the necessary limitation of HF absorption (SAR) [15]. If the field strength is cut in half, an SNR loss approximately by the factor √2 can be assumed which would be compensated by doubling of the measurement time.

The importance of field strength is qualified by the currently available options for shortening measurement time (partial, half-Fourier, phase resolution, parallel imaging, compressed sensing, etc.), signal improvement as a result of new coil technology (multichannel or matrix coils) and noise reduction as a result of improved signal processing (digital signal path, filter and reconstruction algorithms). Therefore, the diagnostically necessary SNR can be achieved at a lower field strength.

Clinical application

The quality requirements regarding clinical MRI were defined by the National Association of Statutory Health Insurance Funds in the Magnetic Resonance Imaging Agreement as an appendix of the Federal Collective Agreement [12]. While the low-field systems available in the 1990 s could not fulfill these technical requirements, low-field units of the latest generation can.

Head

Other than MR spectroscopy and functional MRI, all imaging techniques are also available on low-field systems (▶ **Fig. 1**). T1 and STIR sequences benefit from the good contrast-to-noise ratio and the shorter T1 time at a lower field strength.

The quality of T2 and FLAIR sequences is comparable with high-field systems at a longer scan time. Diffusion-weighted sequences are also possible.

Neck

Low-field imaging sequences of the cervical spine and soft tissues of the neck correspond largely to high-field MRI. The coil design that is optimized for vertical field orientation allows positioning in a solenoid coil ring resulting in good filling of the coil and optimal orientation of the measurement field.

Spine

The new multi-element (array) coils are highly advantageous for imaging of the spine. To date, only loop coils with multiple elements that have advantages in the case of certain geometries but are inferior to array coils have been available for open low-field MRI. Combining multiple coil elements in a 4-channel system and using an image combination makes it possible to achieve whole spine MRI (▶ **Fig. 2**).

Lee et al. compared 0.25 T MRI with 1.5 T and 3.0 T systems regarding the diagnosis of degenerative changes to the lumbar spine. They found very good agreement among the results, with the low-field system having more motion artifacts due to the extended measurement times [28].

Joints

To date, low-field imaging has been most widely used in joint imaging [29] (▶ **Fig. 3**). While early studies tended to have negative results, more recent studies have sparked renewed interest in low-field applications [30, 31]. Raby et al. achieved good results regarding the diagnosis of scaphoid fractures [32]. Ahn et al. examined cartilage lesions of the femoropatellar joint on a 0.2 T MRI unit and achieved good results for high-grade cartilage lesions [33].

A series of studies analyzed the diagnostic performance of MRI of the knee joint on high-and low-field units. Riel et al. achieved unsatisfactory results at 0.2 T [34]. Cotten et al. achieved comparable results between units with low and high field strength [35]. Kreitner et al. conducted a prospective, arthroscopically guided study on a 0.2 T MRI unit. They emphasized the longer examination time and the dependence on the experience of the examiner [30].

Krampla et al. compared 1.0 T, 1.5 T and 3.0 T MRI systems for the diagnosis of knee problems. They found no significant differences. The number of false-negative findings depended more on the experience of the examiner than on the field strength [36].

Magee examined high-field versus low-field MRI of the shoulder and identified advantages with respect to a higher field strength due to the better spatial resolution [37]. Loew et al. compared MR arthrograms of the shoulder on a 0.2 T and 1.5 T MRI

This document was downloaded for personal use only. Unauthorized distribution is strictly prohibited.

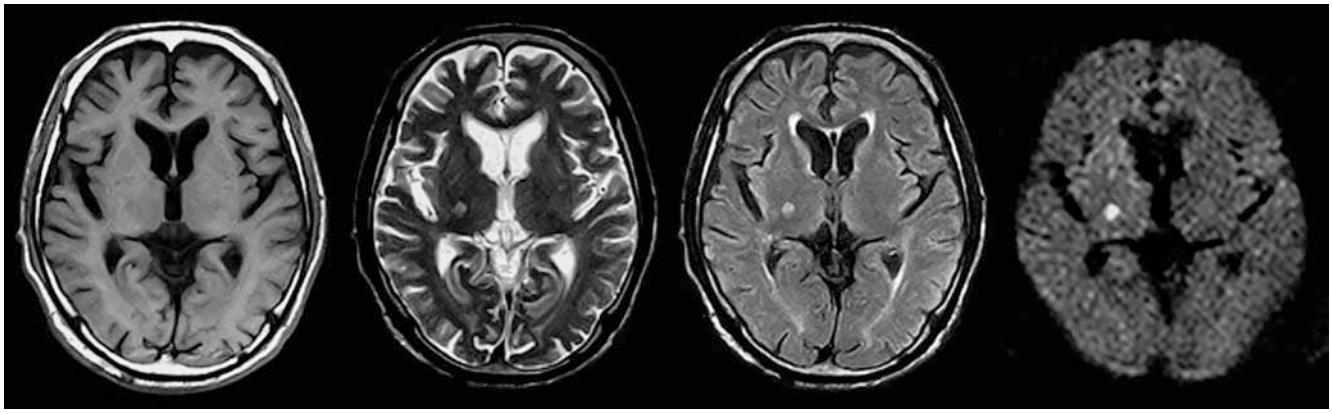

▶ **Fig. 1** Small, acute, ischemic lesion in the right crus posterius capsulae internae. T2- and T1-weighted spin echo, FLAIR and diffusion-weighted EPI sequence.

system. They found comparable results with the better T1 contrast at a lower field strength being evaluated as positive [38].

Tung examined the visualization of labroligamentous lesions on low-field and high-field MRI systems. Labrum defects were able to be detected using low-field MRI with a sensitivity/specificity of 0.67/0.8. 75 % of false-negative lesions under arthroscopic guidance were SLAP 1 defects (frayed labrum) [39].

Thorax

MRI examination of the thoracic organs is challenging.

A current study describes a number of positive effects of imaging at a low field strength on a 0.55 T tunnel system (modified Magnetom AERA, Siemens, Erlangen). The use of a breath-triggered T2-weighted TSE sequence with motion correction (BLADE) allows contrast-enhanced imaging of lung tissue [40]. We used the described technique at 0.35 T (▶ **Fig. 4**).

To date, MRI examination of the breast on a low-field MRI system has been examined in only a few studies. In a histologically correlated study, Pääkko et al. compared MR-mammografies on high-field and low-field MRI systems in breast lesions with a diameter of 8–20 mm. The results were comparable [41].

Sittek et al. reported on preoperative marking of breast lesions on a 0.2 T system [42]. All lesions diagnosed on mammography could be located and marked.

Abdomen

Low-field MRI has a greater HF wavelength due to the lower frequency. The tissue-based attenuation is consequently greatly reduced. The SNR at the center of the body improves accordingly compared to systems with a higher field strength. This effect is advantageous for examination of the abdomen and pelvis when using a low-field system [40].

Combining a RARE sequence with a diffusion-weighted HASTE sequence makes it possible to perform vitality tests of liver metastases [43] (▶ **Fig. 5**).

▶ **Fig. 2** Whole-spine imaging using a 4-channel, 0.35 T system. T2-weighted spin-echo sequences. Images were combined with post-processing software (Magnetom C!, Siemens Healthineers/Erlangen).

This document was downloaded for personal use only. Unauthorized distribution is strictly prohibited.

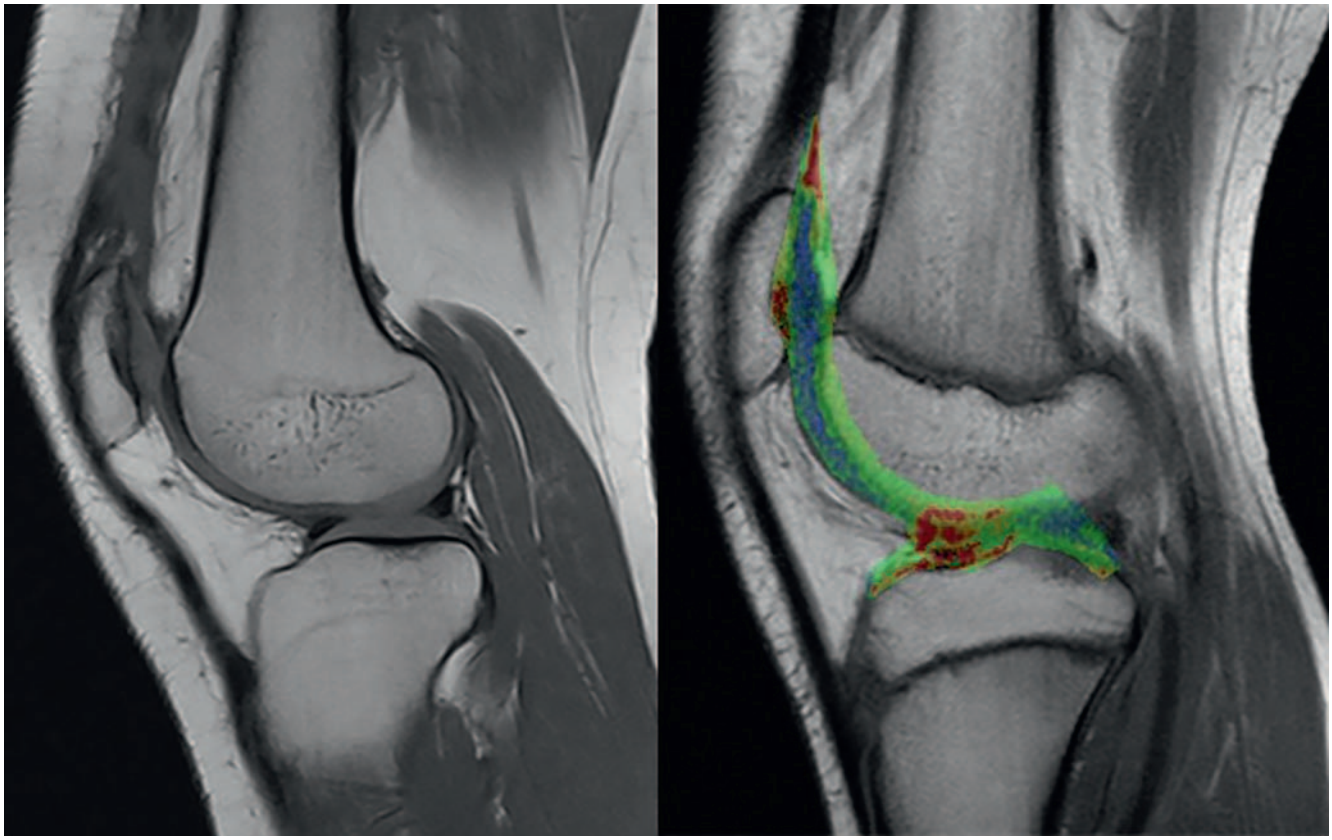

▶ **Fig. 3** MRI of the knee. Left: T1-weighted spin-echo sequence. Good T1-contrast of hyline cartilage, menisci and bone marrow. TE 15 ms, TR 500 ms, SD: 3 mm, matrix: 512 × 640 interpolated, NA 2, scan time 3:50. Right: T2-relaxometry (Magnetom C!, 0.35 T, Siemens Healthineers/Erlangen).

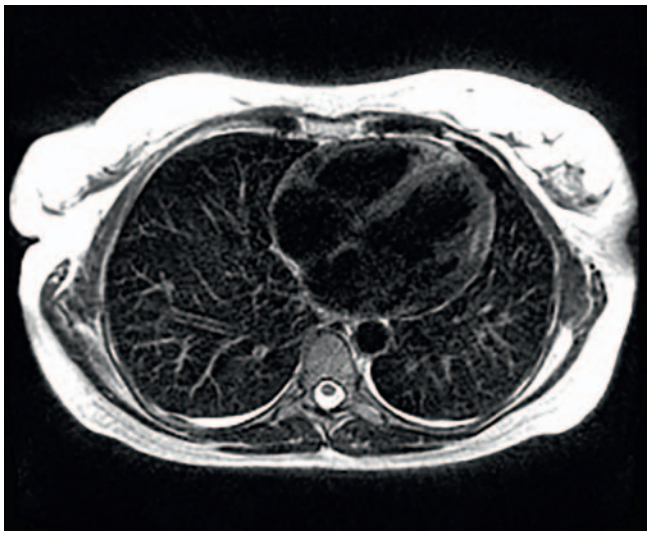

▶ **Fig. 4** Thoracic MRI, 0.35 T (Magnetom C!, Siemens Healthineers/Erlangen), T2-weighted, respiration-triggered TSE-sequence with motion correction (BLADE). Better RF penetration improves signal of lung tissue. TE 114 ms, TR 2510 ms, SD 5 mm, matrix 256, scan time 4:40 min.

Vessels

Both non-contrast and contrast-enhanced MR-angiography techniques can be used on low-field systems.

Contrast-enhanced MR-angiography is characterized by a very good SNR. Modern low-field systems provide the necessary short echo times as a result of high-performance gradient systems.

Although the reduced contrast agent effect could potentially be negative, we found comparable CE-MR angiography quality on MRI systems with high and low field strength [20] (▶ **Fig. 6**).

Functional imaging

The effect of body weight is highly significant for examinations of the musculoskeletal system. It is possible to perform MRI in a standing or sitting position using special systems. An open low-field system facilitates examination of the spine in an inclined or reclined position due to the easier positioning [44].

Cardiac MRI

The first clinical MRI examinations of the heart were performed by Herfkens and Higgins using a superconductive 0.35 T magnet [45].

Cardiac MRI allows visualization of anatomy, quantitative analysis of cardiac function and myocardial perfusion at rest and under stress, and detection of post-ischemic myocardial scars.

This document was downloaded for personal use only. Unauthorized distribution is strictly prohibited.

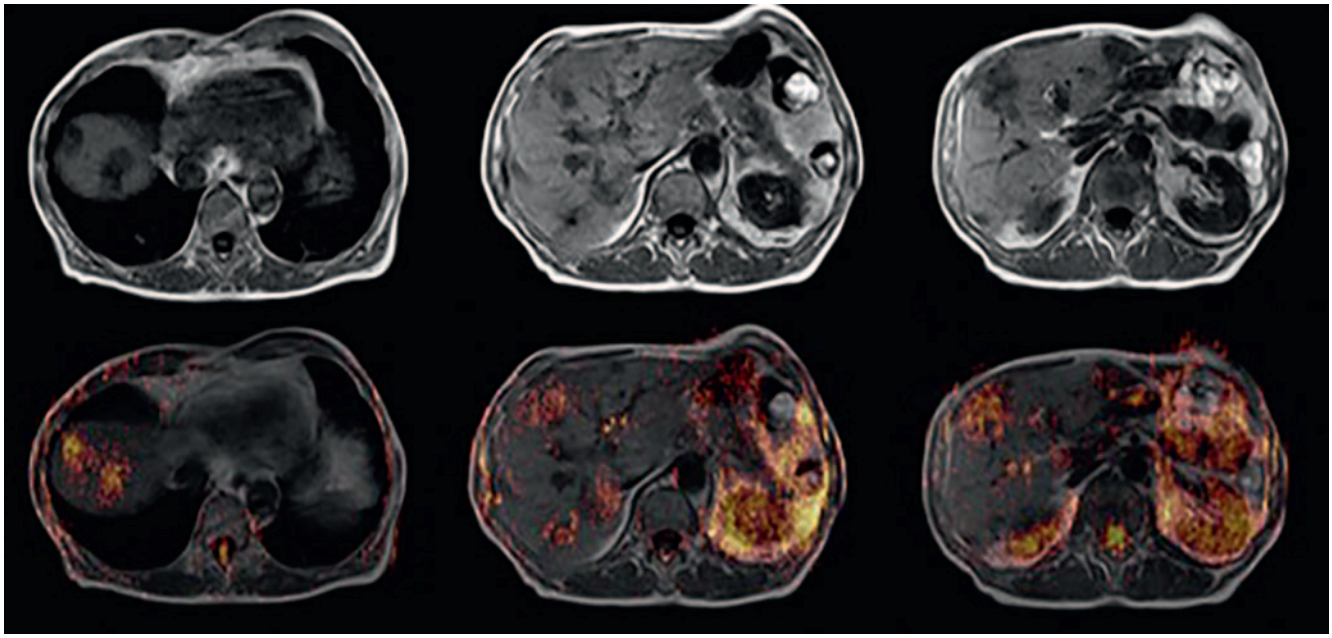

▶ **Fig. 5** Liver metastasis. Upper row: T1-weighted, respiration-triggered RARE sequence with multiple hypointense lesions TE 4.28 ms, TR 155 ms, ST 8 mm, matrix 256, scan time: 3:22. Lower row: Image fusion with a diffusion-weighted HASTE sequence. (Magnetom C!, 0.35 T, Siemens Healthineers/Erlangen).

Although cardiac MRI is currently performed almost exclusively on high-field MRI systems, low-field system also have advantages. Better accessibility to the patient is helpful, particularly in acute situations, and improves patient safety. Patients who have limited mobility or are overweight also benefit from the use of systems with an open magnet [46]. Heating of implanted materials, such as coronary stents, due to HF eddy currents is typically significantly lower.

We performed cardiac MRI on a 0.35 T system (Magnetom C!, Siemens Healthineers, Erlangen) [47]. The gradient system has a strength of 24 mT/m at a slew rate of 55 T/m/s. 3-channel ECG was used for triggering. We used a modified cine-true-FISP sequence for visualizing cardiac anatomy. Cardiac perfusion was visualized with a dynamic SR-prepared FLASH sequence. An IR-prepared T1-weighted turbo gradient echo sequence was used for visualizing myocardial scars (delayed enhancement (DE)).

The image quality, particularly of myocardial scars, was comparable with high-frequency systems due to the shorter T1 times and the better HF penetration (▶ **Fig. 7**).

Metal

Metal artifacts pose a significant challenge in clinical MRI. Material containing iron, e. g. as a result of work accidents or war injuries, can exert mechanical forces at high field strengths that can result in internal injuries. The same is true, for example, for aneurysm clips made of ferromagnetic materials, as can be seen in very old models. These effects barely occur at field strengths of less than 0.5 T.

Metallic implants like joint endoprostheses and osteosynthesis material result in substantial local susceptibility artifacts. These artifacts occur to a significantly lesser degree in low-field MRI (▶ **Fig. 8**). The optimization of sequence parameters with selection of the frequency encoding direction in the longitudinal direction of the implant, maximum bandwidth and selection of a minimal TE are important.

Interventional MRI

The open design of low-field MRI systems with permanent magnets facilitates their use for MRI-guided interventions. The good accessibility is advantageous for both pain therapy and biopsies. Petersilge recommended the use of an open MRI system for MR imaging-guided arthrography [48]. Tunnel systems with a low field strength offer advantages for use in surgical applications, e. g. hybrid ORs (▶ **Fig. 9**) [40].

The combination of low-field MRI and linear accelerators is currently being examined [49].

Energy-efficient MRI

MRI systems with a low field strength, particularly permanent magnets, have low energy consumption. Power consumption is less than 2 kW in stand-by mode and approximately 9 kW in scan mode. By combining the system with a photovoltaic system with an output of 29.8 kWp, we were able to achieve an MRI system installation with a positive energy balance (▶ **Fig. 10**). Projected for the entire year, an energy excess of approximately 50 % can be expected. When using chemical storage concepts (power-to-gas), complete energy self-sufficiency is possible [50].

This document was downloaded for personal use only. Unauthorized distribution is strictly prohibited.

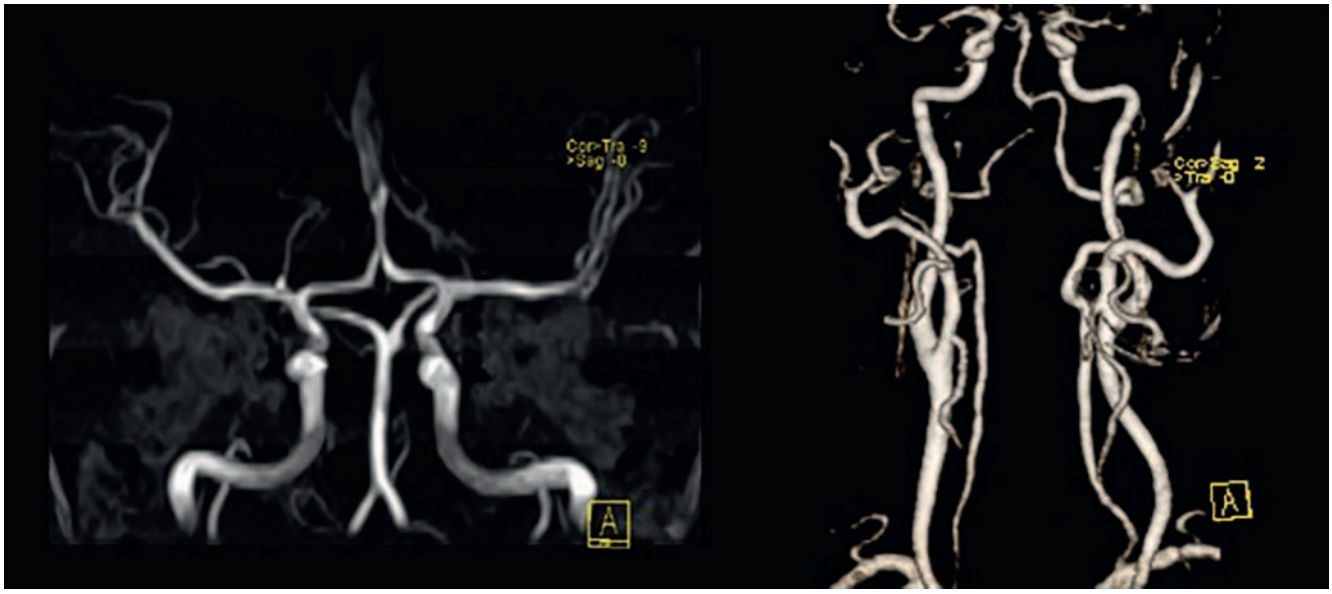

▶ **Fig. 6** MR-angiography. Left: Time-of-flight MR-angiography of the intracranial arteries. Right: CE-MR-angiography of the extracranial cerebral vessels, VRT -reconstruction. TE 2.21 ms, TR 6.52 ms, ST 1.3 mm, matrix 256, scan time: 20 s.

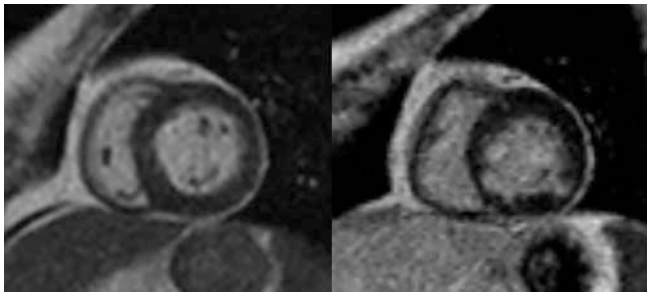

▶ **Fig. 7** Cardiac MRI, 0.35 T. Left: Ventricular function. Short axis. Cine True FISP. Right: Delayed enhancement sequence. IR-prepared FLASH-2 D. TE 5.5, FA 35 degree, max. trigger delay, TI 220 ms, ST 8 mm, matrix 192 × 131, FOV 360 × 300, 1 acquisition. Good delineation of the myocardial scar (Magnetom C!, 0.35 T, Siemens Healthineers/Erlangen).

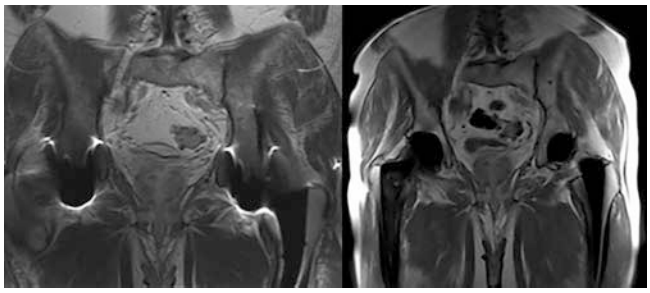

▶ **Fig. 8** Reduced metal artifacts in Low-field MRI. Both examinations were performed using system specific parameter optimization. Frequence encoding gradient along axis of the hip prosthesis.Left: Patient with hip endoprosthesis. 1.5 T (Magnetom Symphony, Siemens Healthineers, Erlangen).Right: Same patient. (Magnetom C!, 0.35 T, Siemens Healthineers/Erlangen). TE 8.9 ms, TR 515 ms, TF 7, ST 5 mm, Matrix 192 × 256 (384 × 512i), bw 260 Hz/Pixel.

▶ **Fig. 9** General anesthesia in open MRI. Reduced “missile effects” improve patient safety and workflow.

Conclusion

MRI systems with a field strength of approximately 0.5 T and less offer a series of important advantages for clinical imaging:

The shorter T1 time and better T1 contrast are advantageous for image quality. Lower susceptibility differences and fat-water shift reduce artifacts and allow imaging even in the case of metal implants. Lower dielectric effects improve HF penetration, noise, and field homogeneity.

Patient safety is improved by quadratic lowering of high-frequency exposure (SAR), lower attraction of metallic objects ("missile effects"), lower interference of bioelectric and biomechanical implants and better access to the patient.

An open design improves patient comfort.

This document was downloaded for personal use only. Unauthorized distribution is strictly prohibited.

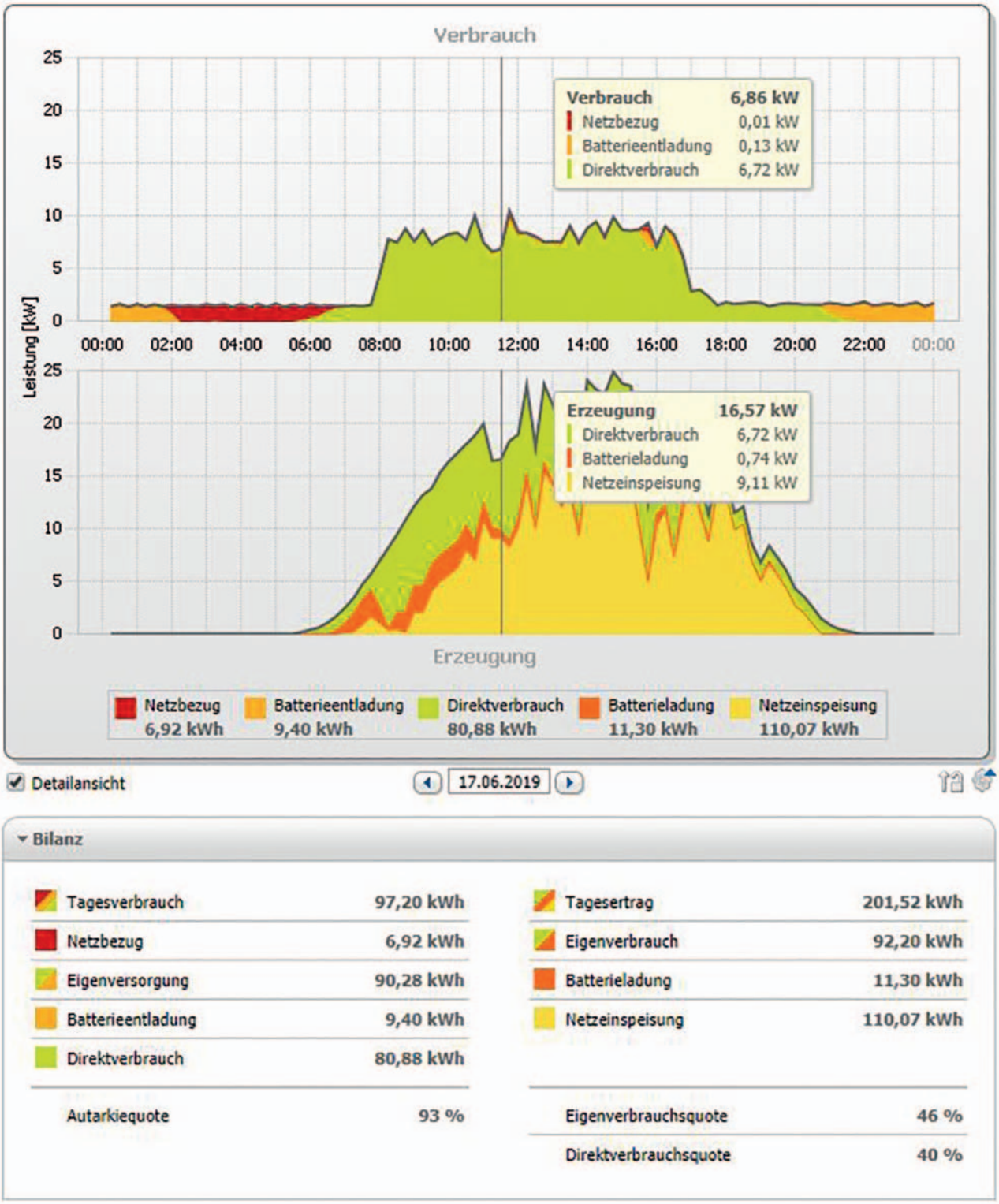

▶ **Fig. 10** Energy profile of a 0.35 T MRI with a permanent magnet (Magnetom C!, 0.35 T, Siemens Healthineers/Erlangen), and a solar panel (29.8 kWp, ENATEK, Hadamer, Germany). A sunny day with some clouds (irregular contour of the profile). Green: Direct use, yellow: net charge (110 kWh), bright red: battery charge, orange: battery retrieval, dark red: net retrieval. 93 % energy autarkicity. 46 % direct use.

This document was downloaded for personal use only. Unauthorized distribution is strictly prohibited.

Permanent magnets have a long service life and require no helium and very little energy.

Differentiated use of different field strengths can be recommended:

- Systems with a field strength of 1.0 T to 1.5 T are the clinical standard.
- For high-resolution examinations, particularly of structures close to the surface, functional imaging (fMRI, BOLD) and spectroscopy, high-field system (> 3.0 T) should be used.
- Systems with lower field strengths have advantages for examinations of the chest, abdomen, and pelvis and in the case of metal implants and in areas of operation (hybrid OR, radiation therapy).

Conflict of Interest

The authors declare that they have no conflict of interest.

References

[1] Rinck P. Magnetic resonance in medicine. Oxford: Blackwell scientific publications; 1993. ISBN: 0-632-03789-4

[2] Kaufman L, Arakawa M, Hale J et al. Accessible magnetic resonance imaging. Magn Reson Q 1989; 5: 283–297

[3] Parizel PM, Dijkstra HA, Geenen GP et al. Low field vs. High field MR imaging of the knee: A comparison of signal behavior and diagnostic performance. Eur J Radiol 1995; 19: 132–138

[4] https://www.fda.gov/regulatory-information/search-fda-guidance-documents/criteria-significant-risk-investigations-magnetic-resonance-diagnostic-devices-guidance-industry-and

[5] Aghaeifar A, Zhou J, Heule R et al. A 32-channel multi-coil setup optimized for human brain shimming at 9.4T. Magn Res Med 2018; 80: 1714–1725

[6] Ertürk MA, Wu X, Eryaman Y et al. Towards body imaging at 10.5 T. Magn Reson Med 2017; 77: 434–443

[7] Edelstein WA, Hayes CE, Souza SP et al. The NMR phased array. Magn Res Med 1990; 16: 192–225

[8] Günther RW. Mündliche Mitteilung.

[9] Blümich B. Virtual special issue: Magnetic resonance at low fields. J Magn Reson 2016; 274: 145–147

[10] Ladd ME, Bachert P, Meyerspeer M et al. Pros and cons of ultra-high-field MRI/MRS for human application. Prog Nucl Magn Reson Spectrosc 2018; 109: 1–50

[11] Guerin B, Villena JF, Polimeridis AG et al. The ultimate signal-to-noise ratio in reallistic body models. Magn Reson Med 2017; 78: 19569–1980

[12] https://www.gkv-spitzenverband.de/media/dokumente/krankenversicherung_1/aerztliche_versorgung/qualitaetssicherung/qualitaetssicherung_1/qs_sonstige_vereinbarungen/OS_Kernspintomografie_1-2015.pdf

[13] Schenck JF. Safety of strong, static magnetic fields. J Magn Reson Imaging 2000; 12: 2–19

[14] Wehrli F. Principles of Magnetic Resonance. In: Stark B Magnetic Resonance Imaging. 14 Mosby; 1992

[15] Kuhl CK et al. Whole Body High-Field Strength (3.0-T) MR imaging in Clinical practice. Radiology 2008; 246: 675–696

[16] Maubon AJ, Feru JM, Berger V et al. Effect of Field Strength on MR Images: Comparison of the Same Subject at 0.5, 1.0, and 1.5 T. Radiographics 1999; 19: 4

[17] Fischer HW, Rinck PA, van Haverbecke Y et al. Nuclear relaxation of human brain gray and white matter: analysis of field dependence and implications for MRI. Magn Res Med 1990; 16: 317–334

[18] Kuhl CK, Kooijman H, Gieseke J et al. Effect of B1 inhomogeneity on breast MR imaging at 3.0 T. Radiology 2007; 244: 929–930

[19] Collins CM, Liu W, Schreiber W et al. Central brightening due to constructive interference with, without, and despite dielectric reonance. J Magn Reson Imaging 2005; 21: 192–196

[20] Rinck PA, Muller RN. Field strength and dose dependence of contrast enhancement by gadolinium-based MR contrast agents. Eur Radiol 1999; 9: 998–1004

[21] Klein HM, Buchal R, Achenbach U et al. Contrast-Enhanced MRA of Carotid and Vertebral Arteries: Open 0.35 vs. 1.5 T MRI. Clin Neuroradiol 2008; 18: 107–113

[22] von Grebmeier J et al. In-vitro-und Patientenuntersuchung mittels MRT: Bedeutung metallischer Implantate. Fortschr Röntgenstr 1991; 154: 484–487

[23] Shellock FG. Radiofrequency energy induced heating during the MR procedures: a review. J Magn Reson Imaging 2000; 12: 30–36

[24] Duan W, Liu C, Zhang L et al. Comparison of the genotoxic effects induced by 50 Hz extremely low-frequency electromagnetic fields and 1800 MHz radiofrequency electromagnetic fields in GC-2 cells. Radiat Res 2015; 183: 305–314

[25] Nadobny J, Klopfleisch R, Brinker G et al. Experimental investigation and histopathological identification of acute thermal damage in skeletal porcine muscle in relation to whole-Body SAR, maximum temperature, and CEM43 _C due to RF irradiation in an MR Body coil of birdcage type at 123 MHz. Int J Hyperthermia 2015; 31: 409–420

[26] Hauger O, Dumont E, Chateil J et al. Water excitation as an alternative to fat saturation in MR imaging: Preliminary results in musculoskeletal imaging. Radiology 2002; 224: 657–663

[27] Hammernik K, Klatzer T, Kobler E et al. Learning a Variational Network for Reconstruction of Accelerated MRI Data. Magn Reson Med 2018; 79: 3055–3071

[28] Lee RK, Griffith JF, Lau YY et al. Diagnostic Capability of low- versus high-field MRI for Lumbar Degenerative Disease. Spine 2015; 40: 382–391

[29] Tavernier T, Cotten A. High- versus low-field MR imaging. Radiol Clin Am 2005; 43: 673–681

[30] Kreitner KF, Hansen M, Schadmand-Fischer S et al. Low-field MRI of the knee joint: results of a prospective, arthroscopically controlled study. RöFo 1999; 170: 35–40

[31] Kreitner KF, Loew R, Runkel M et al. Low field MR arthrography of the shoulder joint: technique, indications, and clinical results. Eur Radiol 2003; 13: 320

[32] Raby N. Magnetic resonance imaging of suspected scaphoid fractures using a low field dedicated extremity MR system. Clin Radiol 2001; 56: 316–320

[33] Ahn JM, Kwak SM, Kang HS et al. Evaluation of patellar cartilage in cadavers with a low field strength extremity-only magnet: Comparison of MR imaging sequences, with macroscopic findings as the standard. Radiology 1998; 208: 57–62

[34] Riel KA, Reinisch M, Kersting-Sommerhoff B et al. 0.2-Tesla magnetic resonance of internal lesions of knee joint: a prospective arthroscopically controlled clinical study. Knee Surgs Sports Traumatol Arthroscop 1997; 7: 37–41

[35] Cotten A, Delfaut E, Demondion X et al. MR imaging of the knee at 0.2 and 1.5 T: Correlation with surgery. Am J Roentgenol 2000; 174: 1093–1097

[36] Krampla W, Roesel M, Svoboda K et al. MRI of the knee: how do field strength and radiologist's experience influence diagnostic accuracy and interobserver correlation in assessing chondral and meniscal lesions and

This document was downloaded for personal use only. Unauthorized distribution is strictly prohibited.

the integrity of the anterior cruciate ligament? Eur Radiol 2009; 19: 1519–1528

[37] Magee T, Shapiro M, Williams D. Comparison of high-field-strength versus low-field-strength MRI of the shoulder. Am J Roentgenol 2003; 181: 1211–1215

[38] Loew R, Kreitner KF, Runkel M et al. MR arthrogaphy of the shoulder: comparison of low field (0.2T) vs. High field (1.5T) imaging. Eur Radiol 2000; 10: 989–996

[39] Tung GA, Entzian D, Green A et al. High-field and low-field MR imaging of superior glenoid labral tears and associated tendon injuries. Am J Roentgenol 2000; 174: 1107–1114

[40] Campbell-Washburn AE et al. Opportunities in interventional and diagnostic imaging by using high performance low field strength MRI. Radiology 2019; 293: 384–393

[41] Pääkkö E, Reinikainen H, Lindholm EL et al. Low-field versus high-field MRI in diagnosing breast disorders. Eur Radiol 2005; 15: 1361–1368

[42] Sittek H, Perlet C, Herrmann K et al. MR mammography. Preoperative marking of non-palpable breast lesions with the Magnetom open at 0.2 T. Radiologe 1997; 37: 685–689

[43] Domalski S, Klein M. MR-Diffusion imaging in liver and other Body areas using HASTE and RARE technique. German patent application. 2006. DE 2006E21415

[44] Harvey SB, Smith FW, Hukins DW. Measurement of lumbar spine flexion-extension using a low-field open-magnet magnetic resonance scanner. Invest Radiol 1998; 33: 439–443

[45] Herfkens RJ, Higgins CB, Hricak H et al. Nuclear magnetic resonance imaging of the cardiovascular system: normal and pathologic findings. Radiology 1983; 147: 749–759

[46] Rothschild PA, Domesek JM, Eastham ME et al. MR imaging of excessively obese patients: the use of an open permanent magnet. Magn Reson Imaging 1992; 9: 151–154

[47] Klein HM, Meyners W, Neeb R et al. Initial Clinical results with Cardiac MRI using an open low-field system. J Comp Ass Tomogr 2007; 31: 430–434

[48] Petersilge CA, Lewin JS, Duerk JL et al. MR Arthrography of the shoulder: Rethinking traditional imaging procedures to meet the technical requirements of MR image guidance. Am J Roentgenol 1997; 169: 1453–1457

[49] Klüter S. Technical design and concept of a 0.35 T MR-Linac. Clinical and Translational Radiation Oncology 2019; 18: 98–101

[50] Klein HM. Clinical Low field strength Magnetic resonance imaging; Springer; 2016. ISBN: 9783319165165 (online)

This document was downloaded for personal use only. Unauthorized distribution is strictly prohibited.