

Endoscopic ultrasound-guided drainage of pancreatic walled-off necrosis using 20-mm versus 15-mm lumen-apposing metal stents: an international, multicenter, case-matched study

Authors

Nasim Parsa¹, Jose M. Nieto², Patrick Powers³, Shuji Mitsuhashi⁴, Abdelhai Abdelqader⁵, George Hadzinakos⁶, Andrea A. Anderloni⁷, Alessandro Fugazza⁷, Theodore W. James⁸, Alexander Arlt⁹, Mark Ellrichmann⁹, Jose Ramon Aparicio¹⁰, Arvind J. Trindade¹¹, Tyler K. Stevens¹², Prabhleen Chahal¹², Shawn L. Shah¹³, Ahmed A. Messallam¹⁴, Gabriel Lang¹⁵, M. Phillip Fejleh¹⁶, Petros C. Benias¹¹, Divyesh V. Sejpal¹¹, Jason Jones¹⁷, Fahad Faisal Mir¹⁸, Mohamad Aghaie Meybodi¹⁹, Yervant Ichkhanian¹⁹, Kia Vosoughi¹⁹, Aleksey A. Novikov⁴, Shayan S. Irani²⁰, Rishi Pawa¹⁷, Ali M. Ahmed²¹, Alireza Sedarat¹⁶, William Hsueh⁵, Jochen Hampe²², Reem Z. Sharaiha¹³, Tyler M. Berzin¹⁸, Field F. Willingham¹⁴, Vladimir M. Kushnir¹⁵, Olaya I. Brewer Gutierrez¹⁹, Saowanee Ngamruengphong¹⁹, Matthew T. Huggett⁶, Todd H. Baron⁸, Alessandro Repici⁷, Douglas G. Adler³, John T. Nasr⁵, Thomas E. Kowalski⁴, Vivek Kumbhari¹⁹, Vikesh K. Singh¹⁹, Mouen A. Khashab¹⁹

Institutions

- 1 University of Missouri Health System, Columbia, Missouri, United States
- 2 Borland Groover Clinic, Jacksonville, Florida, United States
- 3 University of Utah School of Medicine, Huntsman Cancer Hospital, Salt Lake City, Utah, United States
- 4 Thomas Jefferson University Hospital, Philadelphia, Pennsylvania, United States
- 5 West Virginia University Hospital, Morgantown, West Virginia, United States
- 6 St James's University Hospital, Leeds, United Kingdom
- 7 Digestive Endoscopy Unit, Humanitas Research Hospital, Rozzano, Italy
- 8 University of North Carolina, Chapel Hill, North Carolina, United States
- 9 University of Kiel, Kiel, Germany
- 10 Hospital General Universitario de Alicante, Alicante, Spain
- 11 Zucker School of Medicine at Hofstra/Northwell, Northwell Health System, New York, New York, United States
- 12 Cleveland Clinic Foundation, Cleveland, Ohio, United States
- 13 New York-Presbyterian/Weill Cornell Medical Center, New York, New York, United States
- 14 Emory University School of Medicine, Atlanta, Georgia, United States
- 15 Washington University School of Medicine, St Louis, Missouri, United States
- 16 UCLA Medical Center, Los Angeles, California, United States
- 17 Wake Forest Baptist Medical Center, Winston Salem, North Carolina, United States
- 18 Beth Israel Deaconess Medical Center, Boston, Massachusetts, United States

- 19 Johns Hopkins Hospital, Baltimore, Maryland, United States
- 20 Virginia Mason Medical Center, Seattle, Washington, United States
- 21 University of Alabama, Birmingham, Alabama, United States
- 22 University Hospital Carl Gustav Carus Dresden, Dresden, Germany

submitted 31.3.2019

accepted after revision 2.12.2019

Bibliography

DOI <https://doi.org/10.1055/a-1096-3299>

Published online: 31.1.2020 | Endoscopy 2020; 52: 211–219

© Georg Thieme Verlag KG Stuttgart · New York

ISSN 0013-726X


Corresponding author

Mouen A. Khashab, MD, Division of Gastroenterology and Hepatology, Johns Hopkins Hospital, 1800 Orleans Street, Zayed Building, Suite 7125B, Baltimore, Maryland, 21287, United States
 Fax: +1-443-683-8335
mkhasha1@jhmi.edu

 Table 1s–3s

Online content viewable at:

<https://doi.org/10.1055/a-1096-3299>

 Scan this QR-Code for the author commentary.



ABSTRACT

Backgrounds Endoscopic ultrasound (EUS)-guided placement of lumen-apposing metal stents (LAMSs) has gained popularity for the treatment of pancreatic walled-off necrosis (WON). We compared the 20-mm and 15-mm LAMSs for the treatment of symptomatic WON in terms of clinical success and adverse events.

Methods We conducted a retrospective, case-matched study of 306 adults at 22 tertiary centers from 04/2014 to 10/2018. A total of 102 patients with symptomatic WON who underwent drainage with 20-mm LAMS (cases) and 204 patients who underwent drainage with 15-mm LAMS (controls) were matched by age, sex, and drainage approach. Conditional logistic regression analysis was performed to compare clinical success (resolution of WON on follow-up imaging without reintervention) and adverse

events (according to American Society for Gastrointestinal Endoscopy criteria).

Results Clinical success was achieved in 92.2% of patients with 20-mm LAMS and 91.7% of patients with 15-mm LAMS (odds ratio 0.92; $P=0.91$). Patients with 20-mm LAMS underwent fewer direct endoscopic necrosectomy (DEN) sessions (mean 1.3 vs. 2.1; $P<0.001$), despite having larger WON collections (transverse axis 118.2 vs. 101.9 mm, $P=0.003$; anteroposterior axis 95.9 vs. 80.1 mm, $P=0.01$). There was no difference in overall adverse events (21.6% vs. 15.2%; $P=0.72$) and bleeding events (4.9% vs. 3.4%; $P=0.54$) between the 20-mm and 15-mm LAMS groups, respectively.

Conclusions The 20-mm LAMS showed comparable clinical success and safety profile to the 15-mm LAMS, with the need for fewer DEN sessions for WON resolution.

Introduction

Endoscopic ultrasound (EUS)-guided transluminal drainage has evolved to become the treatment of choice for symptomatic pancreatic walled-off necrosis (WON), with higher efficacy and fewer adverse events compared with surgery and percutaneous drainage [1–4]. Traditionally, EUS-guided WON drainage was performed with placement of multiple plastic stents, or biliary or esophageal fully covered self-expandable metal stent [5, 6]. However, these stents have several design deficiencies that result in a high rate of stent migration, occlusion, and inability to perform direct endoscopic necrosectomy (DEN) without stent removal [7–11].

Lumen-apposing metal stents (LAMSs) are specifically designed for the drainage of pancreatic fluid collections. The wider luminal diameter of the LAMS facilitates drainage of WON contents and allows DEN through the stent. The bilateral dumbbell-shaped flanges reduce the risk of migration and leakage by holding two lumens in apposition. In addition, the easy deployment system results in a high technical success rate. Several studies have demonstrated high rates of technical (92.8%–100%) and clinical success (81.0%–97.6%) for EUS-guided WON drainage using LAMSs [12–16]. Until recently, only LAMSs with diameters of 10 mm and 15 mm were available. The 20-mm LAMS (AXIOS; Boston Scientific, Marlborough, Massachusetts, USA) (► **Fig. 1**) was recently released on the market. Its wider luminal diameter provides 300% and 78% greater cross-sectional area compared with the 10-mm and 15-mm LAMSs, respectively. Therefore, it is plausible that the 20-mm LAMS allows enhanced WON drainage and DEN, resulting in higher overall efficacy of WON resolution compared with the 15-mm LAMS. Nonetheless, the larger flanges may theoretically increase the risk of adverse events. Currently, the safety and efficacy of the 20-mm LAMS is not known. In addition, it is unclear how the 20-mm and 15-mm LAMSs compare in terms of efficacy and safety. The aim of this study was to evaluate the ef-

ficacy and safety of the 20-mm LAMS and compare them with the 15-mm LAMS for the treatment of WON.

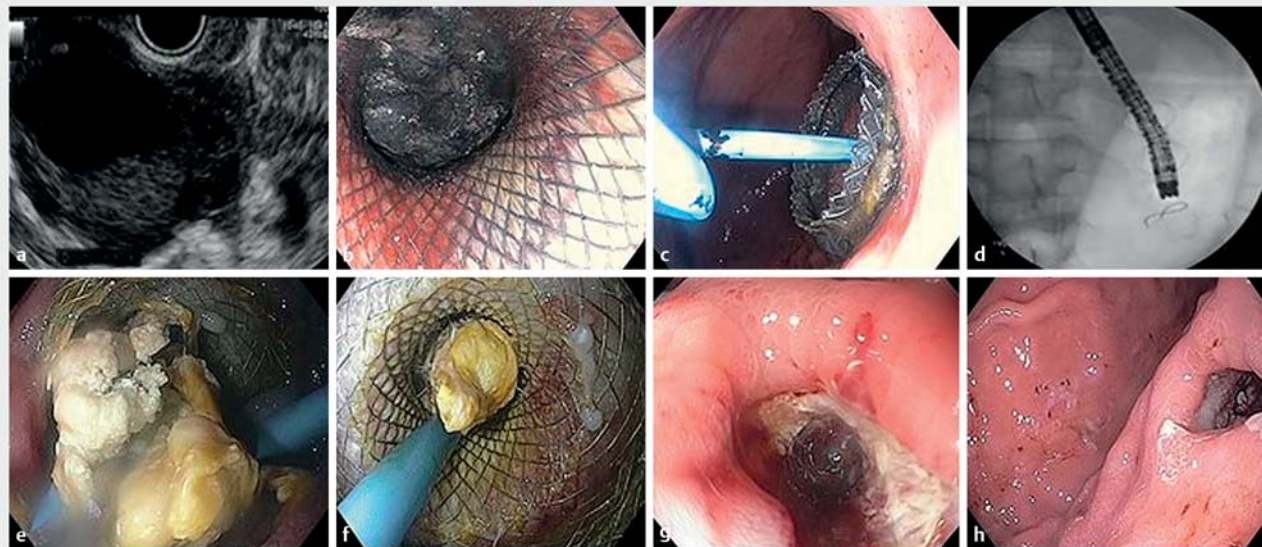Methods

Patient population

This was an international, multicenter, retrospective, case-matched study at 22 tertiary care centers – 17 from the United States and 5 from Europe. Adults with symptomatic WON who underwent EUS-guided drainage with a 20-mm LAMS (March 2017–October 2018) were compared with patients who underwent EUS-guided drainage with a 15-mm LAMS (April 2014–October 2018) (see **Table 1s** in the online-only Supplementary material). WON was defined as an encapsulated collection resulting from pancreatic and/or peripancreatic necrosis confirmed on cross-sectional imaging (per revised Atlanta classification) [17]. Patients were identified using center-specific endoscopic or billing databases. The study was approved by the institutional review board of each center. The authors acknowledge that 42 patients in this study have been included in previously published research; however, no analysis comparing the two stents has been performed [18–20].

Variables of clinical interest

Electronic medical records were reviewed to capture the following variables: demographics, WON characteristics (etiology, location, diameter, estimated necrosis on imaging, extension to paracolic gutter), presence of main pancreatic duct (MPD) disruption or leakage, indications for drainage, drainage approach (transgastric vs. transduodenal), stent type (electrocautery vs. nonelectrocautery), tract dilation, dilation diameter, DEN during index/subsequent procedures, hydrogen peroxide irrigation, nasocystic catheter placement, percutaneous drain insertion, plastic stent placement across the LAMS, endoscopic retrograde cholangiopancreatography (ERCP) performed post-index procedure, MPD stent insertion, length of hospital stay, and duration of follow-up.



► **Fig. 1** Endoscopic ultrasound (EUS)-guided placement of a lumen-apposing metal stent (LAMS) for the management of pancreatic walled-off necrosis (WON) in a 59-year-old man. **a** An adult echoendoscope was advanced to the stomach and revealed a large heterogeneous hypoechoic collection with internal isoechoic debris suggestive of WON. Under EUS guidance, a 20 mm × 10 mm electrocautery-enhanced LAMS was placed through a transgastric approach creating a cystgastrostomy. **b** The echoendoscope was exchanged with a gastroscope and the stent position was examined. A copious amount of necrotic solid component was seen from the proximal end of the stent. **c,d** The gastroscope was advanced through the LAMS and necrosectomy was performed. A 7 Fr × 5 cm double-pigtail plastic stent was then deployed to enhance drainage and prevent occlusion. **e,f** At 10 days following the initial procedure, repeat upper endoscopy showed a partially occluded LAMS with semi-solid necrotic content, which was then partially removed with a raptor forceps and a large amount of lavage with sterile water. The decision was made to leave the LAMS and the plastic stent for another 2 weeks. **g,h** Following the complete resolution of WON, the LAMS and the double-pigtail plastic stent were removed, using a raptor forceps.

Procedure

The procedure was performed by endoscopists who were experienced in the management of WON. Broad-spectrum antibiotics were given before and after the procedure. All procedures were performed under general anesthesia. The LAMS was placed as previously described [21]. Two types of LAMS were used – electrocautery enhanced (“hot”) and nonelectrocautery enhanced (“cold”). The stent type and size were chosen at the discretion of the endoscopist and on the basis of the type of stent available at the time of the procedure. In patients with a suspicion of MPD disruption or stricture, ERCP was performed with MPD stenting whenever feasible. DEN was performed during the index session and/or subsequently at the discretion of the endoscopist whenever there was a lack of radiologic/clinical improvement or when there were signs and symptoms of stent occlusion. DEN was performed by advancing an upper endoscope through the previously placed LAMS into the WON and then performing debridement of the necrotic material by using cap suction, nets, baskets, snares, rat tooth forceps, and/or forceful irrigation [22]. The LAMS was removed if the patient achieved clinical success, or if there was any evidence of LAMS-related adverse events. If WON collection did not resolve by 3–4 weeks and there was no evidence of adverse events, the LAMS remained in place until resolution of the collection, with patients being closely monitored using repeat radiographic imaging.

Outcomes

The primary outcome was the clinical success of the 20-mm and 15-mm LAMSs. Clinical success was defined as the resolution of WON (<2 cm in maximum diameter) on follow-up cross-sectional imaging without the need for further intervention. Secondary outcomes were results of 20-mm versus 15-mm LAMSs for: 1) overall technical success, defined as the correct positioning and deployment of the stent as determined endoscopically and radiographically; 2) overall adverse event rate; 3) adverse event types (bleeding, infection, stent migration, stent occlusion, stent misdeployment, and others); and 4) adverse event severity, as defined by the American Society for Gastrointestinal Endoscopy (ASGE) lexicon severity grading index [23].

Statistical analysis

Patients who underwent drainage with the 20-mm LAMS (cases) were matched in the analysis stage with patients who underwent drainage using the 15-mm LAMS (controls). Each case (20 mm LAMS) was matched with two controls (15-mm LAMS) based on age (± 5 years), sex, and drainage approach (transgastric vs. transduodenal). The control patients were analyzed for matching, starting with the cases performed most recently. Each control patient was used as a match only once (matching without replacement). Therefore, the total number of control patients was exactly double the number of cases.

Baseline and procedural characteristics of the study population were compared using the Mann–Whitney *U* test for continuous variables and chi-squared test for categorical variables. Data were presented as frequencies, mean with standard deviation (SD), or median values (interquartile range). Conditional logistic regression, which is the favored logistic regression in case-matched studies, was performed to compare the study outcomes between the two groups. Results were presented as odds ratios (ORs) and 95% confidence intervals (CIs). Statistical significance was based on two-sided design-based tests and a *P* value of < 0.05. Statistical analyses were conducted using SPSS version 20.0 (IBM Corp., Armonk, New York, USA).

Results

Baseline characteristics

A total of 102 patients who received 20-mm LAMS were matched with 204 patients who underwent 15-mm LAMS placement. Baseline demographics including age (54.9 vs. 55.2 years, *P*=0.94), sex (female 29.4% vs. 31.9%, *P*=0.66), and drainage approach (transgastric 97.1% vs. 97.1%, *P*=0.51) were evenly matched between the two groups (► **Table 1**, **Table 2s**). The distribution of patients' race, WON etiology, location, estimated necrosis on imaging, extension to paracolic gutter, presence of MPD disruption, and indication for drainage were also similar between the two groups (**Table 2s**). The most common etiology of WON was gallstone pancreatitis (39.2%) in

► **Table 1** Procedural characteristics for the placement of 20-mm vs. 15-mm lumen-apposing metal stents.

	Total (n = 306)	20-mm LAMS (n = 102)	15-mm LAMS (n = 204)	<i>P</i> value
Drainage approach, n (%)				0.51
▪ Transgastric	297 (97.1)	99 (97.1)	198 (97.1)	
▪ Transduodenal	9 (2.9)	3 (2.9)	6 (2.9)	
LAMS type, n (%)				<0.001
▪ Electrocautery enhanced	148 (48.4)	102 (100)	158 (77.5)	
▪ Nonelectrocautery enhanced	158 (51.6)	0 (0)	46 (22.6)	
Tract dilation, n (%)	85 (27.7)	25 (24.5)	60 (29.4)	0.37
Dilation diameter, mean, mm	12.2	15.7	10.6	<0.001
DEN on index procedure, n (%)	214 (69.9)	64 (62.7)	150 (73.5)	0.052
Hydrogen peroxide irrigation, n (%)	119 (38.9)	47 (46.1)	72 (35.3)	0.06
Nasocystic catheter placement, n (%)	23 (7.5)	10 (9.8)	13 (6.4)	0.28
Percutaneous catheter placement, n (%)	38 (12.4)	16 (15.7)	22 (10.8)	0.25
Plastic stent placed through the LAMS, n (%)	60 (19.6)	23 (22.5)	37 (18.1)	0.37
ERCP performed, n (%)	99 (32.4)	32 (31.4)	67 (32.8)	0.91
MPD characteristics, n (%)				0.74
▪ No leak	72 (23.5)	24 (23.5)	48 (23.5)	
▪ Leak	19 (6.2)	5 (4.9)	14 (6.9)	
▪ Complete disruption	8 (2.6)	3 (2.9)	5 (2.5)	
MPD stent insertion, %	34.2	40.8	31.2	0.23
Stent bridges site of leak, %	21.0	12.0	25.4	0.16
Procedure duration, minutes				0.45
Mean (SD)	39.1 (26.8)	37.4 (26.5)	40.1 (27.0)	
Median	33	33	34	
IQR	33	23	37	
Range	179	125	179	
Follow-up duration, mean (SD), months	5.8	2.7 (2.6)	7.3 (9.5)	<0.001

LAMS, lumen-apposing metal stent; DEN, direct endoscopic necrosectomy; ERCP, endoscopic retrograde cholangiopancreatography; MPD, main pancreatic duct; SD, standard deviation; IQR, interquartile range.

the 20-mm group and alcoholic pancreatitis (37.7%) in the 15-mm group. The location of WON in the 20-mm LAMS group was head (6.9%), body (53.9%), tail (18.6%), and extra-pancreatic (20.6%), compared with 11.8%, 60.3%, 9.8%, and 18.1%, respectively, in the 15-mm LAMS group. The 20-mm LAMS group had larger WON collections compared with the 15-mm LAMS group (transverse axis 118.2 vs. 101.9 mm, $P=0.003$; and anteroposterior axis 95.9 vs. 80.1 mm, $P=0.01$; respectively). WON extended to the paracolic gutter in 28.4% and 22.1% of cases in the 20-mm and 15-mm LAMS groups, respectively ($P=0.22$), and complete MPD disruption was noted in 12.0% and 8.1%, respectively ($P=0.28$). The most common indication for drainage in both groups was abdominal pain (54.9% vs. 53.9%, $P=0.87$).

Procedure characteristics

► **Table 1** summarizes the procedure characteristics of the two groups. The procedure characteristics were similar between the two groups. All 20-mm LAMSs and 77.5% of the 15-mm LAMSs were placed using the electrocautery-enhanced delivery system ($P<0.001$). Tract dilation prior to stent placement was performed in 24.5% and 29.4% of patients in the 20-mm and 15-mm LAMS groups, respectively ($P=0.37$). DEN was performed on index procedure in 62.7% and 73.5% of patients in the 20-mm and 15-mm LAMS groups, respectively ($P=0.05$). Concomitant therapies in 20-mm and 15-mm LAMS groups included hydrogen peroxide-assisted necrosectomy (46.1% vs. 35.3%, $P=0.06$), nasocystic irrigation (9.8% vs. 6.4%, $P=0.28$), and percutaneous drainage (15.7% vs. 10.8%, $P=0.25$), respectively. Plastic stents were placed through the LAMS in 22.5% of patients

with 20-mm LAMSs vs. 18.1% of patients with 15-mm LAMSs ($P=0.37$). ERCP was performed within 30 days pre- or post-WON drainage in 31.4% and 32.8% of patients with 20-mm and 15-mm LAMS, respectively ($P=0.91$). There was no difference in terms of procedure duration between the 20-mm and 15-mm LAMS groups (37.4 vs. 40.1 minutes, $P=0.45$).

Outcomes

► **Table 2** summarizes the outcomes of WON drainage in the two stent groups. The rate of technical success (99.0% vs. 100%; OR 1.01, $P=0.58$) and clinical success (92.2% vs. 91.7%; OR 0.92, $P=0.91$) was comparable between the 20-mm and 15-mm LAMS groups, respectively. Patients in the 20-mm LAMS group underwent fewer DEN sessions for WON resolution than patients in the 15-mm LAMS group (mean 1.3 vs. 2.1; OR 0.41, $P<0.001$). There was no difference between the 20-mm and 15-mm LAMS groups in terms of WON recurrence requiring re-intervention (7.8% vs. 8.3%; OR 2.04, $P=0.31$) as well as type of re-intervention (surgical necrosectomy 1.0% vs. 0%; endoscopic stent placement 5.9% in both groups; and percutaneous drainage 1.0% vs. 2.5%). The length of hospital stay was comparable between the two groups (15.4 vs. 10.9 days; OR 1.01, $P=0.27$). The overall rate of adverse events was similar between the groups: 22 events (21.6%) in the 20-mm LAMS group and 31 (15.2%) in the 15-mm LAMS group (OR 1.13, $P=0.72$). On logistic regression analysis, there was no association between the stent size and WON recurrence requiring re-intervention, length of hospital stay, and overall adverse event rate.

► **Table 2** Outcomes of walled-off necrosis drainage using 20-mm vs. 15-mm lumen-apposing metal stents.

	Total (n=306)	20-mm LAMS (n=102)	15-mm LAMS (n=204)	OR (95%CI)	P value
Technical success, n (%)	305 (99.7)	101 (99.0)	204 (100)	1.01 (0.001–12.28)	0.58
Clinical success, n (%)	281 (91.8)	94 (92.2)	187 (91.7)	0.92 (0.21–4.01)	0.91
DEN sessions for WON resolution, mean	1.8	1.3	2.1	0.41 (0.28–0.6)	<0.001
WON recurrence requiring re-intervention, n (%)	25 (8.2)	8 (7.8)	17 (8.3)	2.04 (0.51–8.18)	0.31
Type of re-intervention, n (%)					
▪ Surgical necrosectomy	1 (0.3)	1 (1.0)	0		
▪ Endoscopic stent placement	18 (5.9)	6 (5.9)	12 (5.9)		
▪ Percutaneous catheter placement	6 (2.0)	1 (1.0)	5 (2.5)		
Length of hospital stay, days				1.01 (1.01–1.03)	0.27
▪ Mean (SD)	12.5 (25.0)	15.4 (27.6)	10.9 (23.2)		
▪ Median	3	3.5	3		
▪ IQR	13	19	11		
▪ Range	197	197	184		
Total adverse events, n (%)	53 (17.3)	22 (21.6)	31 (15.2)	1.13 (0.56–2.26)	0.72

LAMS, lumen-apposing metal stent; DEN, direct endoscopic necrosectomy; WON, walled-off necrosis; SD, standard deviation; IQR, interquartile range.

Adverse events

► **Table 3** summarizes the adverse events related to WON drainage in the two stent groups. In total, 53 adverse events (17.3%) occurred in the two groups. These included 20 stent migrations, 12 bleeding events, 13 stent occlusions, 4 infections, 1 stent misdeployment, 2 patients with respiratory failure, and 1 with prolonged pain. There were five bleeding events (4.9%) in the 20-mm LAMS group compared with seven (3.4%) in the 15-mm LAMS group ($P=0.54$). Subgroup analysis did not show any difference between the groups for the rate of pseudoaneurysm bleed (2.9% vs. 2.5%; $P>0.99$), as well as nonpseudoaneurysm bleeding events requiring intervention and/or blood transfusion (2.0% vs. 1.0%; $P>0.99$). The rates of infection, stent migration, stent occlusion, and stent misdeployment were similar between the 20-mm and 15-mm LAMS groups (1.0% vs. 1.5%, $P>0.99$; 6.9% vs. 6.4%, $P=0.87$; 4.9% vs. 3.9%, $P>0.99$; 1.0% vs. 0%, $P=0.33$, respectively). The 20-mm and 15-mm groups were similar in terms of adverse event severity according to

the ASGE lexicon grading system (mild 2.0% in both groups; moderate 17.6% vs. 13.2%, $P=0.30$; severe 2.0% vs. 0%, $P=0.11$, respectively). There were no reported deaths in the entire cohort.

Discussion

The complicacy of WON treatment has been simplified by technical advances in the field of interventional EUS. The development of specifically designed, dumbbell-shaped, wide-caliber LAMSs that can be placed endoscopically in one or only a few steps, in combination with the electrocautery-enhanced delivery system, marks the most recent evolution in the endoscopic management of WON. Until recently, only 10-mm and 15-mm LAMSs were available. Lately, a 20-mm LAMS has been released and used for WON treatment, with the idea that the larger luminal diameter may theoretically facilitate WON drainage and DEN.

► **Table 3** Adverse events related to walled-off necrosis drainage using 20-mm vs. 15-mm lumen-apposing metal stents.

	Total (n=306)	20-mm LAMS (n=102)	15-mm LAMS (n=204)	P value
Adverse events, n (%)				
▪ Total	53 (17.3)	22 (21.6)	31 (15.2)	0.72
▪ Stent migration	20 (6.5)	7 (6.9)	13 (6.4)	0.87
▪ Bleeding	12 (3.9)	5 (4.9)	7 (3.4)	0.54
▪ Presumed pseudoaneurysm bleed	8 (2.6)	3 (2.9)	5 (2.5)	>0.99
▪ Other bleeding events requiring transfusion and/or intervention	4 (1.3)	2 (2.0)	2 (0.9)	>0.99
Stent occlusion	13 (4.2)	5 (4.9)	8 (3.9)	>0.99
Infection	4 (1.3)	1 (1.0)	3 (1.5)	>0.99
Stent misdeployment	1 (0.3)	1 (1.0)	0	0.33
Others*	3 (1.0)	3 (2.9)	0	0.03
Management				
▪ Conservative management	1 (0.3)	0	1 (0.5)	>0.99
▪ Medical	7 (2.3)	4 (3.9)	3 (1.5)	0.22
Total reintervention performed	45 (14.7)	18 (17.6)	27 (13.2)	0.30
▪ Endoscopic intervention	37 (12.1)	15 (14.7)	22 (10.8)	0.32
▪ Radiological Interventional	8 (2.6)	3 (2.9)	5 (2.5)	>0.99
▪ Surgical intervention	0	0	0	–
Severity per ASGE lexicon, n (%)				
▪ Mild	6 (2.0)	2 (2.0)	4 (2.0)	>0.99
▪ Moderate	45 (14.7)	18 (17.6)	27 (13.2)	0.30
▪ Severe	2 (0.7)	2 (2.0)	0	0.11
▪ Fatal	0	0	0	–

LAMS, lumen-apposing metal stent; ASGE, American Society for Gastrointestinal Endoscopy.

* Two patients with respiratory failure and one with prolonged pain.

We present the largest reported cohort on the use of LAMSs in the treatment of WON, as well as the first case-matched study to compare the 20-mm and 15-mm LAMSs in terms of efficacy and adverse events. Compared with previous studies, we observed similarly high technical and clinical success rates (99.7% and 91.8%), and a similar overall adverse event rate (17.3%) for the use of LAMSs in EUS-guided WON drainage.

In spite of fewer mean DEN sessions in the 20-mm LAMS group (1.3 vs. 2.1; OR 0.41, $P < 0.001$), the rate of WON resolution on follow-up cross-sectional imaging without the need for further intervention (clinical success) was similar between the two groups (92.2% vs. 91.7%; OR 0.92, $P = 0.91$), supporting the aforementioned idea that larger luminal diameter may facilitate WON drainage and reduce the number of DEN sessions. Notably, our results showed that WON collections in the 20-mm LAMS group were significantly larger than in the 15-mm LAMS group (transverse axis 118.2 vs. 101.9 mm, $P = 0.003$; anteroposterior axis 95.9 vs. 80.1 mm, $P = 0.01$). The reason for this is uncertain; however, it is possible that a larger WON collection on preprocedural imaging could have influenced the endoscopists' decision to use a larger stent (20-mm LAMS). Interestingly, we did not find any significant difference between the WON necrosis percentage and the two stent sizes. Overall, the comparable clinical success rates between the two LAMS groups, along with fewer DEN sessions despite larger WON collections, without increases in adverse events in the 20-mm LAMS group, indicate that patients with larger and more complex WON collections may potentially benefit from placement of a 20-mm LAMS.

Recently, several studies have reported bleeding rates of up to 25% and rates of bleeding due to pseudoaneurysm formation of up to 8.5% in patients after LAMS placement [24–27]. However, several other large cohorts have reported very low bleeding rates (**Table 3s**) [12, 15, 16, 18, 20, 28, 29]. Recently, Zeissig et al. reported their data on a cohort of 93 patients with WON who underwent LAMS placement. Five bleeding events (5.3%) were reported, none of which were fatal (two mild and three severe bleeding events defined as requiring blood transfusion, admission to intensive care or arterial embolization) [28]. To investigate these findings in a larger patient cohort, we conducted a subgroup analysis to evaluate the overall bleeding and pseudoaneurysm bleeding rates, and to compare these between the two LAMS groups. Results from our cohort are in agreement with all those studies that report low bleeding rates associated with LAMS. In our study, among 306 patients who underwent EUS-guided LAMS placement, 12 bleeding events (3.9%) occurred, 8 of which (2.6%) were due to pseudoaneurysm bleed. With regard to nonbleeding adverse events, we report a similar rate for overall post-procedural infection, stent migration, stent occlusion, and stent misdeployment compared with previously reported data, with no difference between the 20-mm and 15-mm LAMS groups.

Several factors should be considered when choosing the type and size of the stent for WON treatment. In general, LAMSs are more expensive than plastic stents. In a cost-effectiveness analysis comparing LAMSs and plastic stents for WON, the LAMS was found to be more efficacious (successful drainage without the need for further interventions) and more expensive [33]. This higher initial cost may be counter-balanced by a lower reintervention rate and shorter procedure time, but direct studies comparing the overall costs of LAMS with other stents for WON are limited [34, 35]. In addition, LAMS may not be the best option for patients who are nonadherent to follow-up, given the reported delay in adverse events.

Although this is a large, international, multicenter, case-matched study, it is limited by its retrospective nature and inherent heterogeneity in various aspects, including data collection, the timing of cross-sectional imaging, different radiographic imaging modalities and interpreting radiologists, different time periods between the two groups, and follow-up after stent placement. Our study did not examine the impact of EUS-guided WON drainage with and without hydrogen peroxide irrigation, nasocystic catheter, percutaneous catheter, and plastic stent placement. In addition, the study included multiple centers that use varied thresholds and personalized approaches for selection of stent type and size, and how and when to perform EUS-guided WON drainage and/or DEN. Admittedly, series of this type are limited by possible selection bias, as there is no standardized algorithm with regard to stent management. It is important to note that the difference in the time period between the two groups is inevitable, as the 20-mm LAMS was not available until February 2017 and was not used for WON drainage until later. In addition, our specific matching criteria resulted in the exclusion of a significant number of control patients during the matching process. Moreover, to minimize bias, matching was done without replacement. Matching without replacement, which is a preferred matching method in control groups with a large sample size (as in this study), improves matching quality by decreasing variance. Using the same control patients for multiple cases (matching with replacement), can result in bias as multiple matched control patients are no longer independent. In addition, the effect estimate will be based on a small number of controls and the number of times each control is matched. To minimize the time difference between the two groups, matching was performed starting with the 15-mm LAMS cases performed most recently (among 204 cases with 15-mm LAMS in 4.5 years, 118 were performed after March 2017 and only 7 were performed during the first year).

In conclusion, we report comparable clinical success and safety between the 20-mm and 15-mm LAMSs, with fewer DEN sessions needed for WON resolution when a 20-mm LAMS is used. There is a need for large, randomized, prospective studies to further evaluate the optimal stent selection for WON treatment.

Competing interests

Drs. Arlt, Ellrichmann, Aparicio, Sejpal, Irani, Pawa, Ahmed, Sedarat, Hampe, Sharaiha, Berzin, Stevens, Willingham, Kushnir, Ngamruengphong, Hugget, Baron, Repici, Adler, Nasr, Kowalski, Kumbhari, and Khashab are consultants for Boston Scientific. Dr. Trindade is a consultant for Pentax Medical and CSA Medical. Dr. Benias is a consultant for Fujifilm, Medtronic, and Apollo. Dr. Sejpal is also a consultant for Olympus America. Dr. Ahmed is also a consultant for Cook Medical. Dr. Hampe is also a consultant for Cook Medical, Olympus America, and B. Braun. Dr. Sharaiha is also a consultant for Olympus America and Apollo. Dr. Chahal is a consultant for Medtronic. Dr. Willingham is also a consultant for RedPath, Cook Medical, Xlumena, Oncolys Biopharma, and has received research funding to the university from Cancer Prevention Pharmaceuticals. Dr. Hugget is also a consultant for Cook Medical. Dr. Repici has also received research funding from Boston Scientific. Dr. Kumbhari is also a consultant for Medtronic, Reshape Lifesciences, and Apollo Endosurgery, and has received research support from ERBE and Apollo Endosurgery. Dr. Singh is a consultant for Abbvie and Novo Nordisk, and is a member of an advisory board for Akcea. Dr. Khashab is also a consultant for Olympus America and Medtronic.

All other authors have no conflict of interest to disclose.

References

- [1] Van Santvoort HC, Besselink MG, Bakker OJ et al. Dutch Pancreatitis Study. Endoscopic necrosectomy in necrotising pancreatitis: indication is the key. *Gut* 2010; 59: 1587
- [2] Ross A, Irani S, Gan I et al. Dual-modality drainage of infected and symptomatic walled-off pancreatic necrosis: long-term clinical outcomes. *Gastrointest Endosc* 2014; 79: 929–935
- [3] Gardner TB, Coelho-Prabhu N, Gordon SR et al. Direct endoscopic necrosectomy for the treatment of walled-off pancreatic necrosis: results from a multicenter U.S. series. *Gastrointest Endosc* 2011; 73: 718–726
- [4] Yasuda I, Nakashima I, Iwai T et al. Japanese multicenter experience of endoscopic necrosectomy for infected walled-off pancreatic necrosis: the JENIPaN study. *Endoscopy* 2013; 45: 627–634
- [5] Baron TH, Harewood GC, Morgan DE et al. Necrosis, acute pancreatic pseudocysts, and chronic pancreatic pseudocysts. *Gastrointest Endosc* 2002; 56: 7–17
- [6] Talreja JP, Shami VM, Ku J et al. Transenteric drainage of pancreatic-fluid collections with fully covered self-expanding metallic stents (with video). *Gastrointest Endosc* 2008; 68: 1199–1203
- [7] Bang JY, Varadarajulu S, Tamhane A et al. Graded dilation technique for EUS-guided drainage of peripancreatic fluid collections: an assessment of outcomes and complications and technical proficiency. *Gastrointest Endosc* 2008; 68: 656–666
- [8] Martins FP, Rossini LG, Ferrari AP et al. Migration of a covered metallic stent following endoscopic ultrasound-guided hepaticogastrostomy: fatal complication. *Endoscopy* 2010; 42: 126–127
- [9] Gardner TB, Chahal P, Papachristou GI et al. A comparison of direct endoscopic necrosectomy with transmural endoscopic drainage for the treatment of walled-off pancreatic necrosis. *Gastrointest Endosc* 2009; 69: 1085–1094
- [10] Varadarajulu S, Bang JY, Phadnis MA et al. Endoscopic transmural drainage of peripancreatic fluid collections: outcomes and predictors of treatment success in 211 consecutive patients. *Gastrointest Surg* 2011; 15: 2080–2088
- [11] Van Brunshot S, Fockens P, Bakker OJ et al. Endoscopic transluminal necrosectomy in necrotising pancreatitis: a systematic review. *Surg Endosc* 2014; 28: 1425–1438
- [12] Rinninella E, Kunda R, Dollhopf M et al. EUS-guided drainage of pancreatic fluid collections using a novel lumen-apposing metal stent on an electrocautery-enhanced delivery system: a large retrospective study (with video). *Gastrointest Endosc* 2015; 82: 1039–1046
- [13] Shah RJ, Shah JN, Waxman I et al. Safety and efficacy of endoscopic ultrasound-guided drainage of pancreatic fluid collections with lumen-apposing covered self-expanding metal stents. *Clin Gastroenterol Hepatol* 2015; 13: 747–752
- [14] Vazquez-Sequeiros E, Baron TH, Perez-Miranda M et al. Evaluation of the short- and long-term effectiveness and safety of fully covered self-expandable metal stents for drainage of pancreatic fluid collections: results of a Spanish nationwide registry. *Gastrointest Endosc* 2016; 84: 450–457
- [15] Siddiqui AA, Adler DG, Nieto J et al. EUS-guided drainage of peripancreatic fluid collections and necrosis by using a novel lumen-apposing stent: a large, retrospective, multicenter U.S. experience. *Gastrointest Endosc* 2016; 83: 699–707
- [16] Sharaiha RZ, Tyberg A, Khashab MA et al. Endoscopic therapy with lumen-apposing metal stents is safe and effective for patients with pancreatic walled-off necrosis. *Clin Gastroenterol Hepatol* 2016; 14: 1797–1803
- [17] Banks PA, Bollen TL, Dervenis C et al. Classification of acute pancreatitis 2012: revision of the Atlanta classification and definitions by international consensus. *Gut* 2013; 62: 102–111
- [18] Siddiqui AA, Kowalski TE, Loren DE et al. Fully covered self-expanding metal stents versus lumen-apposing fully covered self-expanding metal stent versus plastic stents for endoscopic drainage of pancreatic walled-off necrosis: clinical outcomes and success. *Gastrointest Endosc* 2017; 85: 758–765
- [19] Olaiya B, Mekaroonkamol P, Keilin SA et al. Efficacy and safety of self-expandable lumen-apposing fully covered metal stent with an electrocautery-enhanced delivery system in treatment of pancreatic fluid collections. *Am J Gastroenterol* 2017; 112: S437–S438
- [20] Adler D. Single-operator experience with a 20-mm diameter lumen apposing metal stent to treat patients with large pancreatic fluid collections from pancreatic necrosis. *Endosc Ultrasound* 2018; 7: 422–423
- [21] Binmoeller KF, Nett A. The evolution of endoscopic cystgastrostomy. *Gastrointest Endosc Clin N Am* 2018; 28: 143–156
- [22] Sun S, Adler D, Guo J et al. A multi institutional consensus on how to perform endoscopic ultrasound-guided peri-pancreatic fluid collection drainage and endoscopic necrosectomy. *Endosc Ultrasound* 2017; 6: 285
- [23] Cotton PB, Eisen GM, Aabakken L et al. A lexicon for endoscopic adverse events: report of an ASGE workshop. *Gastrointest Endosc* 2010; 71: 446–454
- [24] Varadarajulu S, Bang JY, Hasan M et al. Lumen-apposing metal stents (LAMS) for pancreatic fluid collection (PFC) drainage: may not be business as usual. *Gut* 2017; 66: 2054–2056
- [25] Stecher SS, Simon P, Friessecke S et al. Delayed severe bleeding complications after treatment of pancreatic fluid collections with lumen-apposing metal stents. *Gut* 2017; 66: 1871–1872
- [26] Lang GD, Fritz C, Bhat T et al. EUS-guided drainage of peripancreatic fluid collections with lumen-apposing metal stents and plastic double-pigtail stents: comparison of efficacy and adverse event rates. *Gastrointest Endosc* 2018; 87: 150–157
- [27] Brimhall B, Han S, Tatman PD et al. Increased incidence of pseudoaneurysm bleeding with lumen-apposing metal stents compared to double-pigtail plastic stents in patients with peripancreatic fluid collections. *Clin Gastroenterol Hepatol* 2018; 16: 1521–1528
- [28] Zeissig S, Sulk S, Brueckner S et al. Severe bleeding is a rare event in patients receiving lumen apposing metal stents for the drainage of pancreatic fluid collections. *Gut* 2019; 68: 945–946

- [29] Walter D, Will U, Sanchez-Yague A et al. A novel lumen-apposing metal stent for endoscopic ultrasound-guided drainage of pancreatic fluid collections: a prospective cohort study. *Endoscopy* 2015; 47: 63–67
- [30] Bang JY, Hassan MK, Navaneethan U et al. Lumen-apposing metal stents for drainage of pancreatic fluid collections: When and for whom? *Dig Endosc* 2017; 29: 83–90
- [31] Bang JY, Navaneethan U, Hasan MK et al. Non-superiority of lumen-apposing metal stents over plastic stents for drainage of walled-off necrosis in a randomised trial. *Gut* 2019; 68: 1200–1209
- [32] Law ST, De La Serna Higuera C, Simón PG et al. Comparison of clinical efficacies and safeties of lumen-apposing metal stent and conventional-type metal stent-assisted EUS-guided pancreatic wall-off necrosis drainage: a real-life experience in a tertiary hospital. *Surg Endosc* 2018; 32: 2448–2453
- [33] Chen YI, Barkun AN, Adam V et al. Cost-effectiveness analysis comparing lumen-apposing metal stents with plastic stents in the management of pancreatic walled-off necrosis. *Gastrointest Endosc* 2018; 88: 267–276
- [34] Mukai S, Itoi T, Baron TH et al. Endoscopic ultrasound-guided placement of plastic vs. biflanged metal stents for therapy of walled-off necrosis: a retrospective single-center series. *Endoscopy* 2015; 47: 47–55
- [35] Ang TL, Kongkam P, Kwek AB et al. A two-center comparative study of plastic and lumen-apposing large diameter self-expandable metallic stents in endoscopic ultrasound-guided drainage of pancreatic fluid collections. *Endosc Ultrasound* 2016; 5: 320–327