Published online: 2019-12-20

Severe rectal bleeding caused by a small polypoid lobular capillary hemangioma

A 52-year-old man without comorbidities was admitted to our gastroenterology department after he collapsed while on the toilet and noticed passage of bright red blood per rectum. On clinical examination he appeared to be healthy. Only mild abdominal pain was noticed. He was normotensive but with mild tachycardia (111/min). Laboratory analysis was unremarkable except for normocytic anemia (hemoglobin 78 g/L). He denied medicine consumption.

In order to exclude upper gastrointestinal bleeding, esophagogastroduodenoscopy was performed during which no clinically relevant findings were reported. Colonoscopy was attempted with a gastroscope and without previous purge. Fresh blood with numerous coagula was found in the rectum (▶ **Fig. 1 a**), while the mucosa between the sigmoid and mid-transverse colon was covered with old blood (▶ **Fig. 1 b**). The cecum was not reached. The rectum was carefully re-examined and, after cleansing, a 10-mm 0-Isp polyp was discovered at 12 cm from the anal verge (▶ **Fig. 2 a**). Active oozing of venous-type bleeding was observed from the tip of the polyp.

Resection using a hot snare without submucosal injection was performed (▶ **Fig. 2 b**) and the postpolypectomy defect was closed with two hemoclips (▶ **Fig. 2 c**, ▶ **Video 1**). After an uneventful 24 hours of observation, the patient was discharged home. Histology analysis revealed an 8 × 6 × 5 mm lobular capillary hemangioma with erosion on the mucosal surface.

Also known as pyogenic granuloma, lobular capillary hemangiomas are most common in nasal mucosa and skin [1], and are very rare in the small and large intestine [2]. The typical presentation is gastrointestinal bleeding with or without anemia or abdominal pain. Massive bleeding is rare, although historical literature describes cases of death from exsanguination [3]. We have described a case of massive bleeding from a small polypoid rectal lobular capillary hemangioma in a previously healthy man, which was successfully removed by snare polypectomy with electrocautery.

Endoscopy_UCTN_Code_CCL_1AD_2AJ

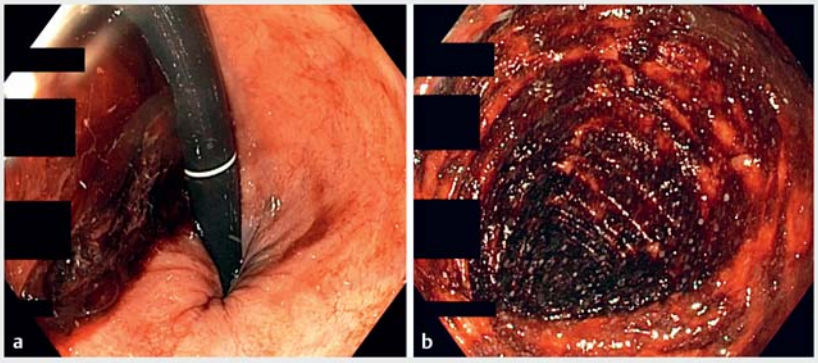

▶ **Fig. 1** Endoscopic images. **a** Fresh blood with coagula in the rectum, as seen in inversion. **b** The mucosa of the mid-transverse colon was covered with old blood and feces.

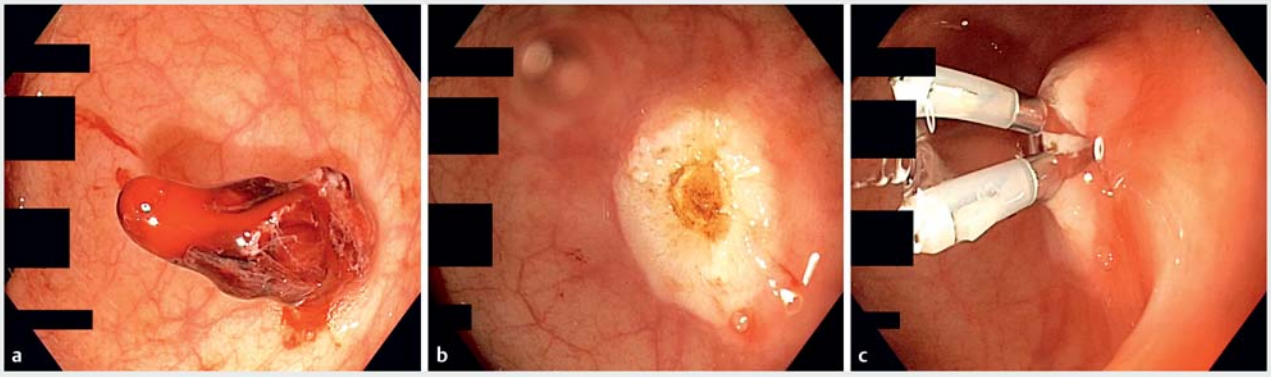

▶ **Fig. 2** Endoscopic images. **a** Active oozing of venous-type bleeding was observed from the eroded polyp surface. The polyp was located in the upper part of the rectum. Histology analysis showed lobular capillary hemangioma. **b** The bleeding polyp was successfully removed by snare polypectomy with electrocautery. **c** Owing to massive bleeding and a potential underlying vessel, the polypectomy defect was closed with two hemoclips despite the small size of the resected polyp.

This document was downloaded for personal use only. Unauthorized distribution is strictly prohibited.

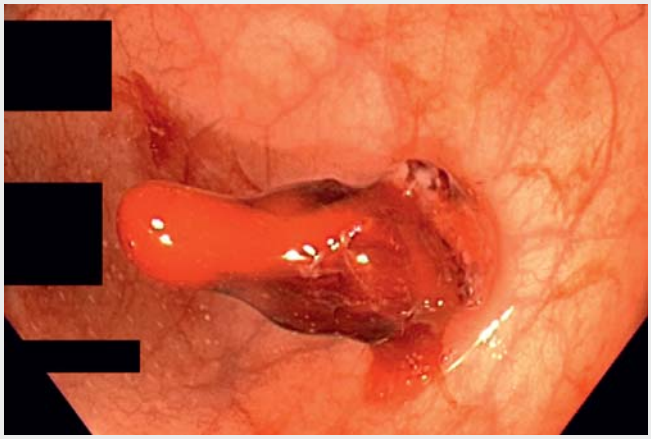

Video 1 A 10-mm lobular capillary hemangioma was the cause of severe rectal bleeding with post-hemorrhagic anemia in a 52-year-old man.

Competing interests

The authors declare that they have no conflict of interest.

The authors

Aleksandar Gavric[1], Jernej Mlakar[2], Samo Plut[1,3]

1 Department of Gastroenterology and Hepatology, University Medical Center Ljubljana, Ljubljana, Slovenia
2 Institute of Pathology, Faculty of Medicine, University of Ljubljana, Ljubljana, Slovenia
3 Medical Faculty, University of Ljubljana, Ljubljana, Slovenia

Corresponding author

Aleksandar Gavric, MD
Department of Gastroenterology and Hepatology, University Medical Center Ljubljana, Japljeva ulica 2, Ljubljana 1000, Slovenia
Fax: +386-1-4334190
aleksandar.gavric@kclj.si

References

[1] Meeks MW, Kamal UM, Hammami MB et al. Gastrointestinal pyogenic granuloma (lobular capillary hemangioma): an underrecognized entity causing iron deficiency anemia. Case Rep Gastrointest Med 2016: 4398401
[2] Meyer-Herbon P, Brugnolaro C, Frei R et al. Pyogenic granuloma of the descending colon: a rare cause of lower gastrointestinal bleeding. ACG Case Rep J 2015; 2: 74–75
[3] Tan MCB, Mutch MG. Hemangiomas of the pelvis. Clin Colon Rectal Surg 2006; 19: 94–101

Bibliography

DOI https://doi.org/10.1055/a-1073-7559
Published online: 20.12.2019
Endoscopy 2020; 52: E225–E226
© Georg Thieme Verlag KG
Stuttgart · New York
ISSN 0013-726X

ENDOSCOPY E-VIDEOS
https://eref.thieme.de/e-videos

Endoscopy E-Videos is a free access online section, reporting on interesting cases and new techniques in gastroenterological endoscopy. All papers include a high quality video and all contributions are freely accessible online.

This section has its own submission website at https://mc.manuscriptcentral.com/e-videos

This document was downloaded for personal use only. Unauthorized distribution is strictly prohibited.