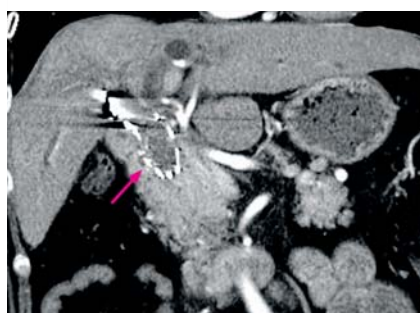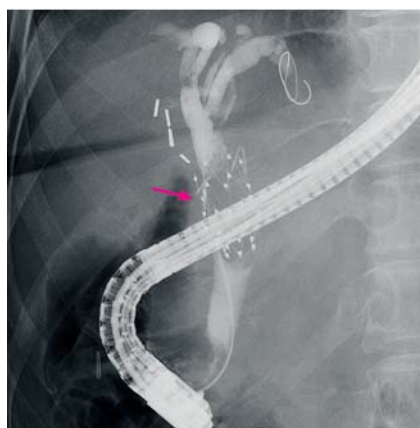


Bile duct stone caused by 25-year placement of metal stent: successful diagnosis and extraction using peroral cholangioscopy



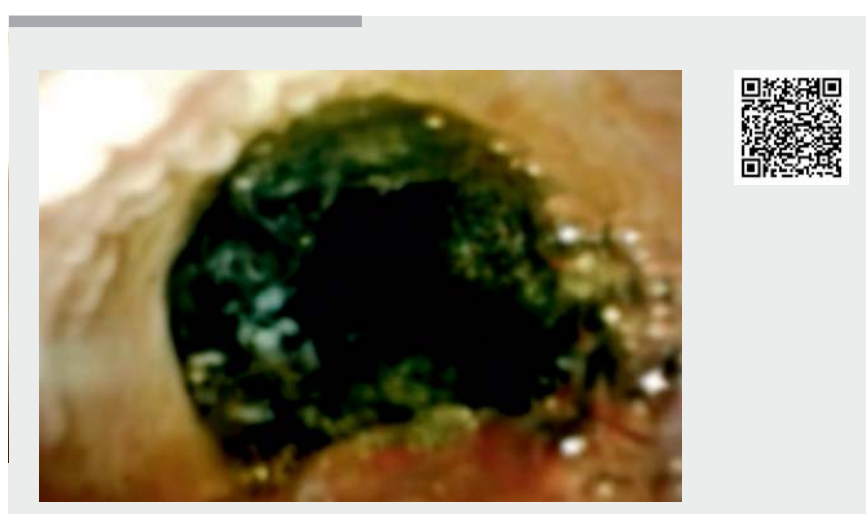
► **Fig. 1** Computed tomography findings. A mass lesion was found inside the metal stent (pink arrow).



► **Fig. 2** Endoscopic retrograde cholangiopancreatography findings. Cholangiography showed a filling defect inside the metal stent (pink arrow).

Bile duct stones can form when a foreign body (e.g. metal stent) is placed for a long period. We report the case of a bile duct stone caused by a metal stent that had been in place for 25 years.

A 61-year-old woman underwent detailed tests for obstructive jaundice at our hospital. Approximately 25 years previously, she had undergone cholecystectomy for a gallbladder stone at a different hospital, followed by percutaneous placement of a metal stent (Gianturco-Rosch biliary Z-stent; Cook Medi-



► **Video 1** A bile duct stone occupying the metal stent was fragmented using a 1.9-Fr electrohydraulic lithotripsy probe. Fragments were removed using a balloon catheter, resulting in resolution of the stenosis inside the metal stent.

cal, Inc., Bloomington, Indiana, USA) for postoperative bile duct stenosis [1]. Contrast-enhanced computed tomography showed a mass lesion inside the metal stent; this was considered to be the cause of the jaundice (► **Fig. 1**). Endoscopic retrograde cholangiopancreatography was then conducted for additional tests and treatment.

Cholangiography showed a filling defect inside the metal stent (► **Fig. 2**). Next, to distinguish between a tumor and bile duct stone, peroral cholangioscopy (POCS) was conducted using SpyGlass DS (Boston Scientific Corp., Marlborough, Massachusetts, USA) (► **Video 1**) [2–4]. A bile duct stone was found to occupy the metal stent, and electrohydraulic lithotripsy (EHL) was conducted using a 1.9-Fr EHL probe, followed by removal of the stone using a balloon catheter (► **Fig. 3**). Removal of the stone resulted in resolution of the stenosis inside the metal stent (► **Fig. 4**), and the patient recovered from jaundice; hence,

this patient is now observed on an outpatient basis.

This report of obstructive jaundice caused by a bile duct stone in a metal stent that had been in place for 25 years, illustrates how POCS can be used to identify the cause of jaundice and aid removal of the stone using EHL. It was possible to visualize the effects of long term metal stent placement directly using POCS.

Endoscopy_UCTN_Code_CPL_1AK_2AH

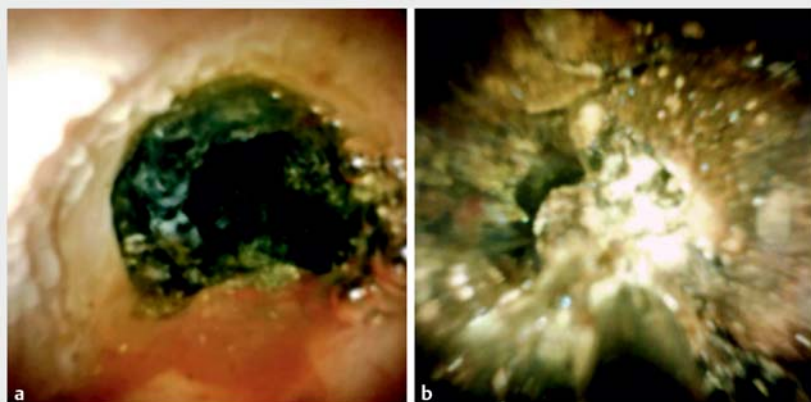
Competing interests

None

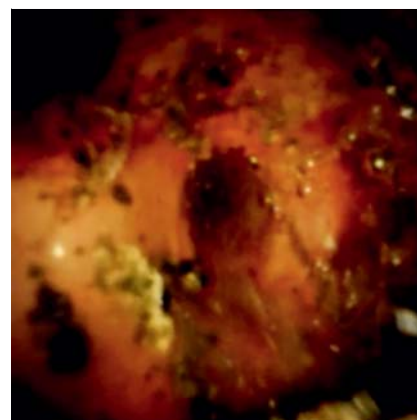The authors

Yuki Tanisaka, Shomei Ryozaawa, Masafumi Mizuide, Akashi Fujita, Tomoya Ogawa

Department of Gastroenterology, Saitama Medical University International Medical Center, Saitama, Japan



► **Fig. 3** Peroral cholangioscopy findings. **a** A bile duct stone was found to occupy the metal stent. **b** Electrohydraulic lithotripsy was carried out.



► **Fig. 4** Peroral cholangioscopy findings. Removal of the stone resulted in resolution of the stenosis inside the metal stent.

Corresponding author

Yuki Tanisaka MD, PhD

Department of Gastroenterology, Saitama Medical University International Medical Center, 1397-1 Yamane, Hidaka, Saitama 350-1298, Japan
Fax: +81-42-9844589
tanisaka1205@gmail.com

center clinical experience (with video). *Gastrointest Endosc* 2016; 84: 649–655

- [3] Shah RJ, Raijman I, Brauer B et al. Performance of a fully disposable, digital, single-operator cholangiopancreatroscope. *Endoscopy* 2017; 49: 651–658
- [4] Ogura T, Imanishi M, Kurisu Y et al. Prospective evaluation of digital single-operator cholangioscope for diagnostic and therapeutic procedures (with videos). *Dig Endosc* 2017; 29: 782–789

References

- [1] Irving JD, Adam A, Dick R et al. Gianturco expandable metallic biliary stents: results of a European clinical trial. *Radiology* 1989; 172: 321–326
- [2] Navaneethan U, Hasan MK, Kommaraju K et al. Digital, single-operator cholangiopancreatography in the diagnosis and management of pancreatobiliary disorders: a multi-

Bibliography

DOI <https://doi.org/10.1055/a-1067-4299>
Published online: 9.12.2019
Endoscopy 2020; 52: E193–E194
© Georg Thieme Verlag KG
Stuttgart · New York
ISSN 0013-726X

ENDOSCOPY E-VIDEOS

<https://eref.thieme.de/e-videos>



Endoscopy E-Videos is a free access online section, reporting on interesting cases and new techniques in gastroenterological endoscopy. All papers include a high quality video and all contributions are freely accessible online.

This section has its own submission website at
<https://mc.manuscriptcentral.com/e-videos>