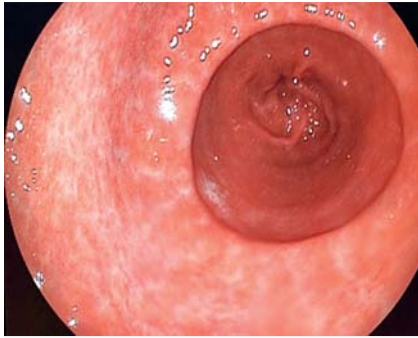


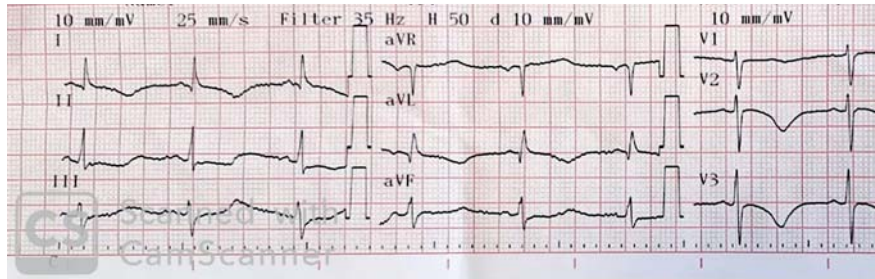
Tako-tsubo cardiomyopathy following gastroscopy: a complication to consider



► **Fig. 1** Gastrointestinal endoscopy revealed gastric atrophy in the antrum.

A 69-year-old woman, who was a former smoker, presented with dysphagia to solids and liquids and epigastric pain over a period of 8 weeks. An upper gastrointestinal endoscopy was performed, without incident, and revealed gastric atrophy in the antrum (► **Fig. 1**). Biopsies were taken according to the Sydney protocol.

After the procedure the patient suffered from chest pain. Electrocardiogram revealed T-wave inversion in precordial leads DI-AVL and V2-V5 (► **Fig. 2**). Troponin level was also elevated (0.53 ng/mL). Urgent coronary angiography was per-



► **Fig. 2** Electrocardiogram: T-wave inversion in leads DI-AVL and V2-V5.

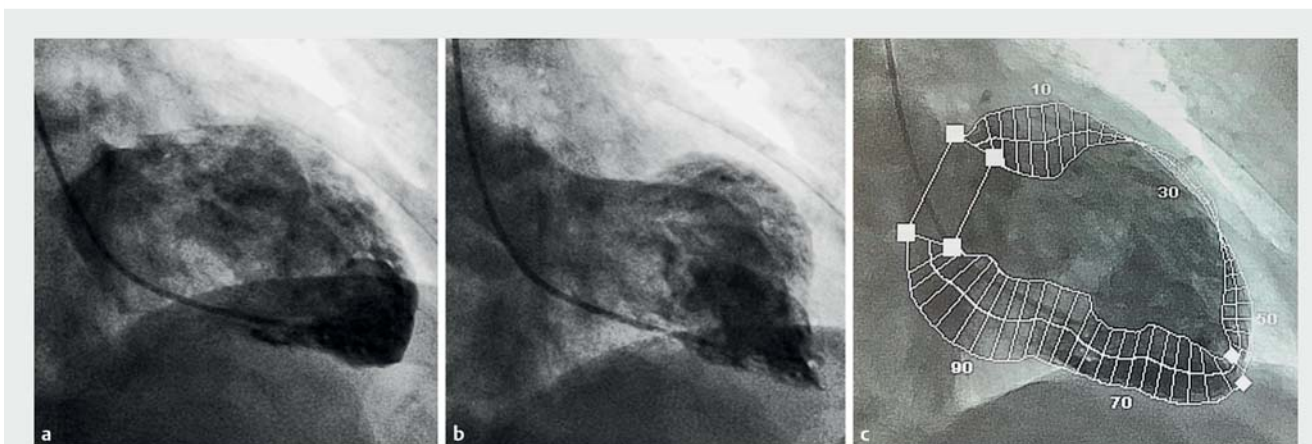
formed and revealed entirely normal coronary vasculature. Left ventriculography demonstrated akinesis of the mid-ventricular anterior segment (► **Fig. 3**, ► **Video 1**).

Echocardiography showed an ejection fraction of 60% and confirmed the akinesis of the mid-ventricular anterior segment. The patient's symptoms improved with aspirin and a beta blocker. There were no complications and the patient was discharged after 72 hours, without any symptoms.

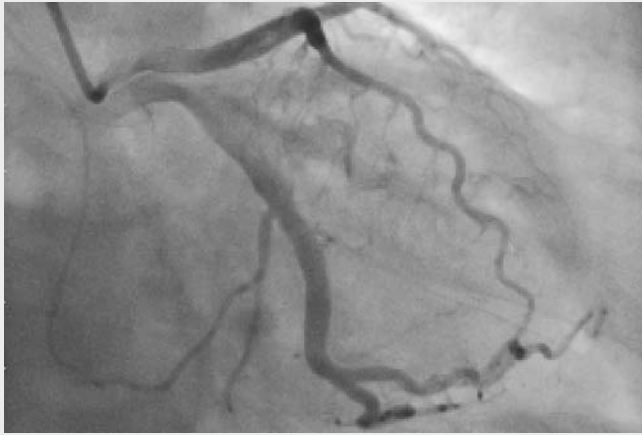
A diagnosis of tako-tsubo cardiomyopathy (TTC) following gastroscopy was made based on the transient and completely reversible wall motion abnormal-

ities and chest pain syndrome without occlusive coronary disease. TTC is a reversible cardiomyopathy that typically occurs in women over the age of 50 years and can mimic an acute coronary syndrome [1]. There are few reports of TTC after gastrointestinal procedures (oral-contrast radiology and colonoscopy) [2]. It has been suggested that catecholamines may play a role in triggering TTC because patients often have preceding emotional or physical stress [3]. Overall the long-term survival is the same as that of the age-matched population and recurrence is possible [4].

Endoscopy_UCTN_Code_CPL_1AN_2AG



► **Fig. 3** Ventriculography. **a** Ventricular diastole. **b** Ventricular systole. Akinesis in the mid-ventricular anterior segment with contractility preserved in the apical and basal segments of the left ventricle. **c** Quantitative analysis of the contractility, showing akinesis in the mid-ventricular anterior segment.



Video 1 Tako-tsubo cardiomyopathy following gastroscopy.

- [2] Mohammad M, Patel A, Koirala A et al. Tako-tsubo cardiomyopathy following colonoscopy: insights on pathogenesis. *Int J Cardiol* 2011; 147: e46–e49
- [3] Kurisu S, Kihara Y. Tako-tsubo cardiomyopathy: clinical presentation and underlying mechanism. *J Cardiol* 2012; 60: 429–437
- [4] Kazakauskaitė K, Jankauskas A, Lapinskas T et al. Tako tsubo cardiomyopathy: the challenging diagnosis in clinical routine. *Medicina (Kaunas)* 2014; 50: 1–7

Bibliography

DOI <https://doi.org/10.1055/a-1028-6899>
Published online: 7.11.2019
Endoscopy 2020; 52: E140–E141
© Georg Thieme Verlag KG
Stuttgart · New York
ISSN 0013-726X

Competing interests

None

The authors

Martín Oricchio¹, Rodrigo Dorelo¹, Juan Pablo Bachini², Daniela Méndez¹, Adrián Canavesi¹

- 1 Clínica de Gastroenterología, Hospital de Clínicas, Montevideo, Uruguay
- 2 Centro Cardiovascular Universitario, Hospital de Clínicas, Montevideo, Uruguay

Corresponding author

Martin Oricchio, MD

Clínica de Gastroenterología, Hospital de Clínicas, Av. Italia S/n CP, 11600, Montevideo, Uruguay
Fax: +598-2-4872572
martinoricchio@hotmail.com

References

- [1] Patel A, Namn Y, Shah S et al. Takotsubo cardiomyopathy after an upper and lower endoscopy: a case report and review of the literature. *J Med Case Rep* 2019; 13: 81

ENDOSCOPY E-VIDEOS

<https://eref.thieme.de/e-videos>



Endoscopy E-Videos is a free access online section, reporting on interesting cases and new techniques in gastroenterological endoscopy. All papers include a high quality video and all contributions are freely accessible online.

This section has its own submission website at <https://mc.manuscriptcentral.com/e-videos>