

Coexistent adenoma and serrated polyps on index colonoscopy and the risk of metachronous advanced colorectal neoplasia



Authors

Soo-Kyung Park¹, Hak-Soo Kim¹, Hyo-Joon Yang¹, Yoon Suk Jung¹, Jung Ho Park¹, Chong Il Sohn¹, Sang Hyun Park¹, Jin Hee Sohn², Mi Yeon Lee³, Dong Il Park¹

Institutions

- 1 Division of Gastroenterology, Department of Internal Medicine and Gastrointestinal Cancer Center, Kangbuk Samsung Hospital, Sungkyunkwan University School of Medicine, Seoul, Republic of Korea
- 2 Division of Pathology, Department of R&D Management, Kangbuk Samsung Hospital, Sungkyunkwan University School of Medicine, Seoul, Republic of Korea
- 3 Division of Biostatistics, Department of R&D Management, Kangbuk Samsung Hospital, Sungkyunkwan University School of Medicine, Seoul, Republic of Korea

submitted 18.12.2018

accepted after revision 23.8.2019

Bibliography

DOI <https://doi.org/10.1055/a-1019-2976> |
Endoscopy International Open 2019; 07: E1748–E1754
© Georg Thieme Verlag KG Stuttgart · New York
eISSN 2196-9736

Corresponding author

Dong Il Park, MD PhD, Division of Gastroenterology, Department of Internal Medicine and Gastrointestinal Cancer, Kangbuk Samsung Hospital, Sungkyunkwan University School of Medicine, 29 Saemunan-ro, Jongno-gu, Seoul 03181, Republic of Korea
Fax: +82-2-20018360
diksmc.park@samsung.com

ABSTRACT

Background and aims The family of serrated polyps (SP) includes hyperplastic polyps (HP), sessile serrated adenomas/polyps, and traditional serrated adenoma. We investigated whether SP synchronous with adenoma at index colonoscopy is associated with metachronous advanced colorectal neoplasia (CRN).

Methods Patients with ≥ 1 adenoma on index colonoscopy and who had undergone a follow-up colonoscopy were included. The patients were divided into four groups according to the presence of SP and advanced adenoma (AA) on index colonoscopy (non-AA, non-AA + SP, AA, AA + SP). The cumulative incidence of metachronous advanced CRN at surveillance colonoscopy was compared between groups.

Results Among a total of 2209 patients, the numbers of patients in the non-AA, non-AA + SP, AA, and AA + SP groups were 922, 441, 625, and 221, respectively. The cumulative incidence of metachronous advanced CRN was higher in patients in the AA + SP group than that in the AA group ($P < 0.001$), and there was no significant difference between the non-AA + SP group and the non-AA group ($P = 0.06$). The cumulative incidence of metachronous advanced CRN at 3 years was 17.9% [95% confidence interval (CI) 8.0–27.6], 10.7% [95%CI 7.7–3.6], 3.5% [95%CI 1.3–5.6], and 3.4% [95%CI 2.0–4.7] in the AA + SP, AA, non-AA + SP, and non-AA group, respectively. In a multivariate analysis, overall SP [hazard ratio (HR) 2.24; 95%CI 1.38–3.64, $P = 0.001$], proximal SP (HR 2.31; 95%CI 1.32–4.08), and HP (HR 2.19; 95%CI 1.35–3.57) were risk factors for metachronous advanced CRN in patients with AA on index colonoscopy.

Conclusions Coexistent AA and SP on index colonoscopy significantly increased the risk of metachronous advanced CRN compared with AA alone. Further large prospective studies are needed to confirm whether more intensive follow-up improves outcomes in these high risk patients.

Introduction

Colorectal cancer (CRC) is the third most common cancer in Western countries and its incidence is increasing in Asian countries [1,2]. Adenoma was the traditional precursor lesion of CRC, but accumulating evidence reports a significant association between serrated polyps (SP) and CRC with the serrated polyp–cancer pathway [3,4]. SP are characterized histologically by a serrated appearance of the crypt epithelium and are classified into three groups of lesions: hyperplastic polyps (HP), sessile serrated adenoma or polyps (SSA/P), and traditional serrated adenoma (TSA) [5,6].

The management and timing of surveillance colonoscopy in individuals with SP are important components of CRC prevention. Thus, the US Multi-Society Task Force on CRC has published guidelines in 2012 for surveillance of SP, and patients with SSA/P of more than 10 mm or SSA/P with dysplasia are recommended to have a colonoscopy within 3 years [7]. However, the guidelines emphasize that their recommendations are based on weak and indirect scientific evidence [8,9]. After 2012, a few studies have evaluated SP as predictors of subsequent metachronous adenomas, but they are limited to a small number of patients [10] or include only SSA/P [11].

In addition, although many patients have coexisting SP and conventional adenoma, previous guidelines did not consider the follow-up period of patients with coexisting SP and conventional adenoma. Although a recent large study from a population-based colonoscopy registry [12] reported that the presence of high risk adenoma (HRA) and synchronous SP on index colonoscopy significantly increased the risk of metachronous HRA, it could not suggest a surveillance interval in these patients. Thus, we aimed to investigate the incidence per 100 person-years and the cumulative incidence of advanced colorectal neoplasia (CRN) according to categorized risk groups by considering both advanced adenoma (AA) and SP, and to investigate the association between metachronous advanced CRN and SP characteristics in patients with AA on index colonoscopy.

Methods

Study sample

This retrospective, single-center cohort study included patients who underwent ≥ 1 polypectomy between January 2009 and November 2012 and who had undergone a follow-up colonoscopy at an interval of ≥ 1 year until December 2016. In our center, the basic strategy for polypectomy is to remove all polyps which are detected and we followed the US colonoscopy surveillance guidelines after polypectomy [7]. In this study, we included patients who had undergone a follow-up colonoscopy for both surveillance and diagnostics. All colonoscopies with polypectomies were performed by six colonoscopists (experience of ≥ 2 years) using high definition colonoscopy (CF-H260AL and CF-H290AL colonoscope, EVIS Lucera Spectrum System, and OEV-191H HDTV monitor, Olympus Optical, Tokyo, Japan), and the median adenoma detection rate was 31.5 (range, 25.2–44.0).

To avoid confusing new CRNs with lesions that had only been missed on the initial colonoscopy, we excluded patients who had undergone a follow-up colonoscopy only within 1 year after the index colonoscopy. Patients were excluded if they had inflammatory bowel disease, or polyposis syndrome (e.g. familial adenomatous polyposis, juvenile polyposis, Peutz-Jeghers syndrome, Cowden syndrome, or serrated polyposis syndrome [SPS]). SPS was defined as (1) at least five serrated polyps proximal to the sigmoid colon, with two or more > 10 mm and/or (2) > 20 SP of any size distributed throughout the colon [6]. In addition, patients with incomplete colonoscopy (did not reach the cecum), inadequate bowel preparation (according to the Boston Bowel Preparation Scale [BBPS], with < 2 segment BBPS score or a total BBPS score of < 6), and CRC in the submucosal layer or with deeper invasion (including Lynch syndrome) or who had undergone surgical resection of the intestines were also excluded.

According to the findings on index colonoscopy, the patients were divided into four groups on the basis of synchronous SP and AAs (non-AA, non-AA + SP, AA, and AA + SP). AA was defined as those adenomas with size > 1 cm or 75% villous component and/or high grade dysplasia (HGD). This study was approved by the institutional review board of Kangbuk Samsung Hospital.

Data collection and outcome measurement

We retrospectively analyzed the patient-, procedure-, and polyp-related data which was obtained from the colonoscopy cohort of Kangbuk Samsung Hospital. Our colonoscopy cohort has been maintained since 2000 using the electronic medical records-based system and was previously described in detail [13,14]. In our colonoscopy cohort, baseline patient demographic and clinical information, polyp findings, and the procedure-related factors have been recorded.

Information on polyp histology was collected from the pathologic results. A total of five expert pathologists reviewed the histological characteristics of the polyps collected between January 2009 and November 2012. In 2008, the Korean Association for the Study of Intestinal Disease released definitions for SSA and TSA after centrally reviewing polyps from 14 tertiary university hospitals [15]. Thus, the pathologic diagnosis of SP as HP, SSA/P, or TSA in our center from 2009 to 2010 followed that consensus. From 2011 to 2012, the diagnosis followed the WHO classification (4th edition) [6], which was very similar to the previous consensus. During the study period, HP was defined as serrated epithelium in the luminal aspects with straight crypts and no distorted crypts, whereas SSA/P with or without cytologic dysplasia had a prominent serration developing near the base of the crypts together with architectural complexity with distorted and dilated crypt bases, with “L-shaped/inverted T-shaped crypts.” TSA was defined as a serrated lesion which possessed dense eosinophilic cytoplasm and concave depression of the surface epithelium and villous projections with ectopic crypts [16–18]. Conventional adenomas were classified as tubular adenoma (TA), tubulovillous adenoma (TVA), or villous adenoma (VA) according to the predominant architecture

► **Table 1** Baseline characteristics of patients at index colonoscopy.

	Non-AA (n = 922)	Non-AA + SP (n = 441)	AA (n = 625)	AA + SP (n = 221)	P value
Age, mean ± SD, years	53.8 ± 10.5	55.2 ± 10.7	55.3 ± 11.3	57.3 ± 10.8	<0.001
Male sex, n (%)	678 (73.5)	372 (84.4)	430 (68.8)	179 (81.0)	<0.001
BMI > 25 kg/m ² ^a , n (%)	347 (41.7)	167 (42.0)	204 (36.7)	197 (43.1)	0.192
Current or ex-smoker ^b , n (%)	332 (46.6)	194 (58.8)	214 (44.0)	93 (57.4)	<0.001
Family history of CRC ^c , n (%)	37 (5.6)	13 (4.2)	26 (5.6)	3 (1.9)	0.223
Aspirin or NSAID use ^d , n (%)	89 (13.0)	33 (10.9)	38 (8.6)	19 (14.0)	0.104

AA, advanced adenoma; BMI, body mass index; CRC, colorectal cancer; NSAID, nonsteroidal anti-inflammatory drug; SP, serrated polyps. Data are available for ^a1984 patients, ^b1691 patients, ^c1581 patients, and ^d1566 patients.

of the dysplastic crypts [19]. Intramucosal carcinoma or carcinoma in situ was considered indicative of HGD.

For the outcome measurements, we analyzed all surveillance examinations if the patients underwent multiple colonoscopies. Advanced CRN was defined as metachronous CRC or AA, and the interval between colonoscopies was calculated based on the follow-up endoscopic date at which advanced CRN was first detected when patients underwent multiple colonoscopies. The incidence of CRN was calculated, and the relative risk of CRN was compared in each group. The 3-year and 5-year cumulative risks of advanced CRN were also compared in each group.

Statistical analysis

The differences in the baseline characteristics on index colonoscopy and the findings from surveillance colonoscopy were compared using the chi-squared test and the analysis of variance test. The crude cumulative incidences of metachronous advanced CRN were calculated using the Kaplan-Meier method, and were not adjusted for possible confounders, and we analyzed the overall and pairwise comparison using the log-rank test. We used the Cox proportional hazard model after adjusting for potentially confounding variables (age, sex, family history of CRC, obesity, smoking status, and aspirin use) to assess the association between metachronous advanced CRN and SP characteristics in patients with AA on index colonoscopy. The results are expressed as hazard ratios (HR) with 95% confidence intervals (CIs). A *P* value of <0.05 was considered statistically significant. All statistical analyses were performed using the Statistical Package for Social Sciences (SPSS) for Windows, Version 18.0 (SPSS Inc., Chicago, IL, United States).

Results

Baseline characteristics of the patients

A total of 4430 patients underwent colonoscopic polypectomy between January 2009 and November 2012 and had undergone a follow-up colonoscopy up to December 2016 at our center. According to the pathologic reports, 1463 patients with non-adenomatous polyps, 356 patients with synchronous CRC, and six patients with inadequate pathologic reports were excluded. In addition, 393 patients were excluded because they had in-

flammatory bowel disease (n = 40), polyposis syndrome (n = 5), a history of bowel resection (n = 79), follow-up colonoscopy only at <1 year (n = 172), inadequate bowel preparation (n = 90), or incomplete examinations (n = 7). Three patients who fulfilled the WHO criteria for SPS were excluded. Finally, 2209 patients were included in this study.

► **Table 1** shows the baseline patient characteristics of the four groups. The numbers of patients were 922, 441, 625, and 221 in the non-AA, non-AA + SP, AA, and AA + SP groups, respectively. The patients in the AA + SP group were older than those in the other groups (*P* < 0.001), and male patients were more frequent in the non-AA + SP group (84.4%) compared with the other groups (*P* < 0.001). There were no statistically significant differences in family history of CRC or use of medications such as aspirin or NSAIDs among the four groups.

► **Table 2** shows the baseline characteristics of polyps among the four groups at index colonoscopy. The mean number of overall adenoma was 4.37 in the AA + SP group, and it was higher than those in the other groups (*P* < 0.001). The patients with AA + SP had a more even distribution of adenoma (*P* < 0.001). The mean number of AA was higher in the AA + SP group than that in the AA group (1.5 vs. 1.3, *P* = 0.03). In the patients with SP, the mean numbers of SP were 1.8 and 1.7 in the non-AA + SP and AA + SP groups, respectively (*P* = 0.12). The characteristics of SP including location, histology, and size did not show any differences between the non-AA + SP group and the AA + SP group. SSA/P or TSA were noted in 34 patients, and their mean size was 9.7 ± 1.0 mm. The locations of SSA/P or TSA were on the proximal side in 17 patients (50%), on the distal side in 16 patients (47.1%), and on both sides in 1 patient (2.8%).

Surveillance colonoscopy findings according to presence of SP

► **Table 3** shows the finding of surveillance colonoscopy. The mean interval duration of surveillance colonoscopy in the patients with AA + SP was 3 years, and it was shorter than those in the other groups (*P* < 0.001). The incidence of advanced CRN at surveillance colonoscopy was 47 (5.1%), 26 (5.9%), 84 (13.4%), and 44 (19.9%) in the non-AA, non-AA + SP, AA, and AA + SP groups, respectively (*P* < 0.001). When we consider the interval duration of surveillance colonoscopy, the incidence per

► **Table 2** Baseline characteristics of polyps at index colonoscopy.

	Non-AA (n=922)	Non-AA+SP (n=441)	AA (n=625)	AA+SP (n=221)	P value
Adenoma character					
▪ Number, mean ± SD	2.1 ± 1.8	2.5 ± 2.0	2.7 ± 2.5	4.3 ± 3.5	<0.001
▪ Location					<0.001
▪ Proximal, n (%)	303 (32.9)	138 (31.3)	150 (24.0)	31 (14.0)	
▪ Distal, n (%)	357 (38.7)	141 (32.0)	231 (37.0)	49 (22.2)	
▪ Both, n (%)	262 (28.4)	162 (16.2)	244 (39.0)	141 (63.8)	
Advanced adenoma					
▪ Number, mean ± SD			1.3 ± 0.7	1.5 ± 1.1	0.03
▪ HGD, n (%)	–	–	155 (24.8)	49 (22.2)	0.43
▪ TVA or VA, n (%)	–	–	64 (10.2)	21 (9.5)	0.75
▪ Size ≥ 10 mm, n (%)	–	–	595 (95.2)	216 (97.7)	0.10
SP character					
▪ Number, mean ± SD		1.8 ± 1.4		1.7 ± 1.3	0.13
▪ Location	–		–		0.60
▪ Distal, n (%)	–	252 (57.1)	–	131 (59.3)	
▪ Proximal, n (%)	–	189 (42.9)	–	90 (40.7)	
▪ Histology	–		–		0.89
▪ HP, n (%)	–	418 (94.8)	–	210 (95.0)	
▪ SSA/P or TSA, n (%)	–	23 (5.2)	–	11 (5.0)	
▪ Size	–		–		0.33
▪ < 10 mm, n (%)	–	375 (85.0)	–	194 (87.8)	
▪ ≥ 10 mm, n (%)	–	66 (15.0)	–	27 (12.2)	

AA, advanced adenoma; HGD, high grade dysplasia; HP, hyperplastic polyp; SP, serrated polyp; SSA/P, sessile serrated adenoma or polyp; TSA, traditional serrated adenoma; VA, villous adenoma.
Distal location is defined as splenic flexure, descending colon, sigmoid, or rectum.

► **Table 3** Findings on surveillance colonoscopy according to the synchronous serrated polyps and advanced adenomas detected on index colonoscopy.

	Non-AA (n=922)	Non-AA+SP (n=441)	AA (n=625)	AA+SP (n=221)
Interval duration of colonoscopy, mean ± SD, years	4.3 ± 0.1	3.6 ± 0.1	3.5 ± 0.7	3.0 ± 0.1
Advanced CRN ¹ , (95%CI)	1.5 (1.2–2.1)	2.1 (1.4–3.0)	4.7 (3.8–5.8)	7.7 (5.7–10.4)
Advanced CRN ²				
▪ 3 years, (95%CI)	3.4 (2.0–4.7)	3.5 (1.3–5.6)	10.7 (7.7–13.6)	17.9 (11.2–24.5)
▪ 5 years, (95%CI)	12.2 (7.6–16.7)	17.8 (8.0–27.6)	28.5 (21.2–35.7)	50 (35.1–65.2)

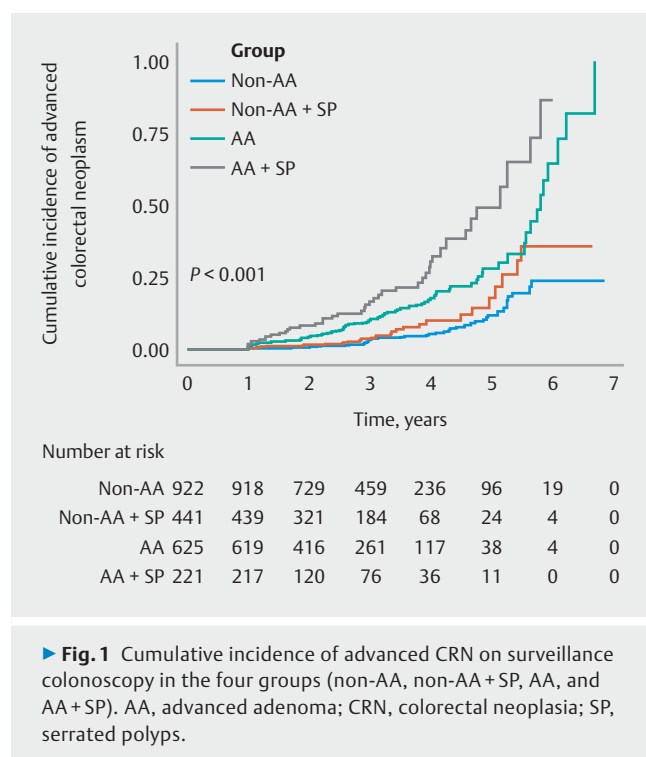
AA, advanced adenoma; CI, confidence interval; CRN, colorectal neoplasia; SP, serrated polyps.

¹ Incidence per 100 person-years (95%CI).

² Cumulative incidence (95%CI).

100 person-years of advanced CRN was 1.5 (95%CI 1.2–2.1), 2.1 (95%CI 1.4–3.0), 4.7 (95%CI 3.8–5.8), and 7.7 (95%CI 5.7–10.4) in the non-AA, non-AA+SP, AA, and AA+SP groups, respectively.

► **Fig. 1** shows the crude cumulative incidences of advanced CRN on surveillance colonoscopy which were not adjusted for possible confounders. The cumulative incidence of advanced CRN differed significantly among the four groups ($P < 0.001$). The cumulative incidence of advanced CRN was significantly



higher in patients in the AA+SP group compared with the AA group ($P < 0.001$). However, there was no difference between the non-AA+SP group and the non-AA group ($P = 0.06$). The cumulative incidences of advanced CRN at 3 years were 17.9% [95%CI 11.2–24.5], 10.7% [95%CI 7.7–13.6], 3.5% [95%CI 1.3–5.6], and 3.4% [95%CI 2.0–4.7] in the AA+SP, AA, non-AA+SP, and non-AA groups, respectively. In the patients with AA+SP, the 2-year cumulative risk of advanced CRN was 8.8% (95%CI 4.6–12.9).

SP characteristics associated with risk of metachronous advanced CRN in patients with AA

To investigate the SP characteristics associated with risk of metachronous advanced CRN in patients with AA, we used the Cox proportional hazards model after adjusting for potentially confounding variables (age, sex, family history of CRC, obesity, smoking status, and aspirin use) (► **Table 4**). In patients with AA on index colonoscopy, synchronous SP was a significant risk factor for metachronous advanced CRN (hazards ratio [HR] 2.24; 95%CI 1.38–3.64, $P = 0.001$). According to the location of SP, distal SP and proximal SP showed HRs of 2.13 (95%CI 1.09–4.19) and 2.31 (95%CI 1.32–4.08), respectively. According to the histology of SP, HP was a significant risk factor for metachronous advanced CRN in patients with AA (HR 2.19; 95%CI 1.35–3.57), and SSA/P or TSA was a risk factor for metachronous advanced CRN with marginal statistical significance (HR 6.47; 95%CI 0.85–49.03, $P = 0.07$). According to the size of SP, an SP < 10 mm had an HR of 2.31 (95%CI 1.39–3.83) in patients with AA. In patients with non-AA on index colonoscopy, synchronous SP and SP characteristics were not associated with risk of metachronous advanced CRN.

Discussion

In this study, we compared the risk of metachronous CRN according to the findings on index colonoscopy, which were divided into four groups, considering both AA and SP. The relative risk of metachronous advanced CRN was higher in patients in the AA+SP group than that in the AA group (19.9% vs. 13.4%, $P < 0.001$), and the 3-year cumulative risk of metachronous advanced CRN in patients with AA+SP was 17.9%, which was higher than that in the AA group (10.7%, $P < 0.001$) (► **Table 3**). These results are consistent with an earlier study which showed that SSA/P patients with synchronous HRA on index colonoscopy presented a higher incidence rate of metachronous advanced neoplastic lesions (12.96 per 1000 person-months) compared with patients with HRA only (5.07 per 1000 person-months) [11]. In that study, the 3-year cumulative risks of advanced neoplastic lesions in patients with HRA+SSA/P and HRA were 35.7% and 17.9%, respectively, and these were higher than those in this study (17.9% and 10.7%, respectively). However, they defined the HRA group as having patients not only with at least one AA but also with three or more adenomas, and they only included patients with SSA/P, not HP or TSA. Another study investigated metachronous advanced CRN in patients with coexistent SP and adenomas [10]. However, the relative risk of advanced CRN was not significantly different between the AA and AA+SP groups (20.7% vs. 18.8%), and the 5-year cumulative risk of advanced CRN was not significantly different between the AA and AA+SP groups (40% vs. 27%, $P = 0.96$). This negative finding may be due to the small cohort size in that study (AA group, $n = 29$, and AA+SP group, $n = 16$).

In the multivariate analysis investigating SP characteristics associated with risk of metachronous advanced CRN, proximal SP was a risk factor for metachronous advanced CRN in the patients with AA (HR 2.31) (► **Table 4**). This result corresponds with those of Schreiner et al. [9] who reported that patients with both AA and proximal non-dysplastic serrated polyps (ND-SP) were more likely to have advanced neoplasia (HR 2.17), although the reference group used in that study was different from that in this study. The reference group in our study was the AA group, and that in the previous study was a group that included AA and AA with distal ND-SP. In our analysis stratified by SP histology, SSA/P or TSA was a risk factor for metachronous advanced CRN with marginal statistical significance (HR 6.47, $P = 0.07$), and the HR of HP was 2.19 in our study (► **Table 4**). A recent study by Anderson et al. [12] reported that patients with HRA and synchronous SSA/P or TSA were four times more likely to have metachronous HRA on follow-up than those with index HRA alone. However, the presence of HRA and synchronous HP was similar in risk to HRA alone for metachronous HRA. This difference might be due to the difference in classification of the baseline group and outcome in which Anderson et al. divided the baseline risk groups based on HRA, and their outcome was also metachronous HRA which included three or more adenomas. Our outcome was metachronous advanced CRN, which did not include three or more adenomas. In the analysis stratified by SP size in our study, an SP < 10 mm had an HR of 2.31 in patients with AA for metachro-

► **Table 4** Association between metachronous advanced colorectal neoplasia and SP characteristics in patients with AA on index colonoscopy (n = 846).

	AA HR ¹ (95%CI)
No SP	Reference
Overall SP	2.24 (1.38–3.64)
Location	
▪ Distal SP	2.13 (1.09–4.19)
▪ Proximal SP	2.31 (1.32–4.08)
Histology	
▪ HP	2.19 (1.35–3.57)
▪ SSA/P or TSA	6.47 (0.85–49.03)
Size	
▪ <10 mm	2.31 (1.39–3.83)
▪ ≥10 mm	1.91 (0.67–5.44)

AA, advanced adenoma; HP, hyperplastic polyps; HR, hazard ratio, CI, confidence interval; SP, serrated polyps; SSA/P, sessile serrated adenoma or polyps; TSA, traditional serrated adenoma.

¹ Adjusting for potentially confounding variables (age, sex, family history of CRC, obesity, smoking status, and aspirin use).

nous advanced CRN. Anderson et al. [12] reported that the HRs for HRA were 5.61, 4.78, and 3.86 in the HRA + SP ≥ 1 cm, HRA + SP < 1 cm, and HRA only groups, respectively. Macaron et al. [10] reported no difference in cumulative incidence of AA between patients with SSP < 10 mm and those with HP or SSP > 10 mm, SSP with dysplasia, or TSA. Pereyra et al. [11] reported that SSA/P > 10 mm was not a risk factor for metachronous advanced neoplastic lesions. These results are different from our expectation that large SP or SSA/P might be a risk factor for metachronous advanced CRN, and this might be due to the small number of large SP or SSA/P in this and previous studies.

In patients with non-AA on index colonoscopy, synchronous SP and SP characteristics were not associated with the risk of metachronous advanced CRN, and this result corresponds with previous studies [9, 11, 12]. SP characteristics including location, histology, and size were not significantly different between the non-AA + SP and AA + SP groups. Aberrant methylation of cytosine-rich promoter regions has been associated with SP and advanced features of conventional adenoma. Thus, genetic factors such as the methylation level of cytosine-rich promoter regions might be different between the two groups. Further genetic studies of SP with synchronous adenoma are needed.

The strength of our study is that we investigated the cumulative incidence of advanced CRN in the high risk group. In patients with both AA and SP, the 3-year cumulative risk of advanced CRN was 17.9% which was higher than that in the AA group (10.7%). In addition, we investigated SP characteristics including location, histology, and size, which are associated with metachronous advanced CRN in patients with AA on index colonoscopy in our large quality-controlled colonoscopy co-

hort. Previous studies only investigated histology and size [12], or location [9].

Our study had several limitations. First, as the number of metachronous SSA/P and TSA was small, we pooled AA, SSA/P, and TSA in the category of metachronous AA for our outcome. Second, we did not consider the number of adenomas (≥ 3) in the baseline risk stratification and outcome. However, patients with 3–4 non-AAs showed a similar risk of metachronous advanced CRN in our previous study [14]. Third, as this study had a retrospective design, follow-up colonoscopy was not performed uniformly. The risk of advanced CRN might be underestimated due to the early use of colonoscopy and exclusion of patients who had not undergone a follow-up colonoscopy. In addition, endoscopists might not remove distal small HP; thus, the number of distal SP or small SP (size < 10 mm) might be underestimated. This may be the reason for our results indicating that distal SP and small SP were also risk factors for metachronous advanced CRN. In addition, it is possible that patients with larger serrated polyps underwent a more careful examination and hence a reduction in metachronous advanced outcomes. Fourth, although the current guidelines are meant for patients undergoing polypectomy during routine screening colonoscopy, we evaluated various indications of colonoscopies. Thus, large prospective studies are needed evaluating the screening colonoscopies with uniformly performed surveillance colonoscopies and investigating SP characteristics associated with metachronous advanced CRN.

In conclusion, coexistent AA and synchronous SP on index colonoscopy significantly increased the risk of metachronous advanced CRN compared with AA alone. Further large prospective studies are needed to confirm whether more intensive follow-up improves outcomes in these high risk patients.

Acknowledgments

This study was supported by a National Research Foundation (NRF) grant funded by the Korea government (NRF-2017R1A2B4A006158).

Competing interests

None

References

- [1] Jemal A, Siegel R, Ward E et al. Cancer statistics, 2008. *CA Cancer J Clin* 2008; 58: 71–96
- [2] Byeon JS, Yang SK, Kim TI et al. Colorectal neoplasm in asymptomatic Asians: a prospective multinational multicenter colonoscopy survey. *Gastrointest Endosc* 2007; 65: 1015–1022
- [3] Hawkins NJ, Ward RL. Sporadic colorectal cancers with microsatellite instability and their possible origin in hyperplastic polyps and serrated adenomas. *J Natl Cancer Inst* 2001; 93: 1307–1313
- [4] O'Brien MJ, Yang S, Mack C et al. Comparison of microsatellite instability, CpG island methylation phenotype, BRAF and KRAS status in serrated polyps and traditional adenomas indicates separate path-

- ways to distinct colorectal carcinoma end points. *Am J Surg Pathol* 2006; 30: 1491–1501
- [5] Rex DK, Ahnen DJ, Baron JA et al. Serrated lesions of the colorectum: review and recommendations from an expert panel. *Am J Gastroenterol* 2012; 107: 1315–1329; quiz 1314, 1330
- [6] Bosman FT. World Health Organization, International Agency for Research on Cancer. WHO classification of tumours of the digestive system. 4th edn. Lyon: International Agency for Research on Cancer; 2010
- [7] Lieberman DA, Rex DK, Winawer SJ et al. Guidelines for colonoscopy surveillance after screening and polypectomy: a consensus update by the US Multi-Society Task Force on Colorectal Cancer. *Gastroenterology* 2012; 143: 844–857
- [8] Laiyemo AO, Murphy G, Sansbury LB et al. Hyperplastic polyps and the risk of adenoma recurrence in the polyp prevention trial. *Clin Gastroenterol Hepatol* 2009; 7: 192–197
- [9] Schreiner MA, Weiss DG, Lieberman DA. Proximal and large hyperplastic and nondysplastic serrated polyps detected by colonoscopy are associated with neoplasia. *Gastroenterology* 2010; 139: 1497–1502
- [10] Macaron C, Vu HT, Lopez R et al. Risk of metachronous polyps in individuals with serrated polyps. *Dis Colon Rectum* 2015; 58: 762–768
- [11] Pereyra L, Zamora R, Gomez EJ et al. Risk of metachronous advanced neoplastic lesions in patients with sporadic sessile serrated adenomas undergoing colonoscopic surveillance. *Am J Gastroenterol* 2016; 111: 871–878
- [12] Anderson JC, Butterly LF, Robinson CM et al. Risk of metachronous high-risk adenomas and large serrated polyps in individuals with serrated polyps on index colonoscopy: Data from the New Hampshire Colonoscopy Registry. *Gastroenterology* 2018; 154: 117–127.e112
- [13] Park SK, Yang HJ, Jung YS et al. Number of advanced adenomas on index colonoscopy: Important risk factor for metachronous advanced colorectal neoplasia. *Dig Liver Dis* 2018; 50: 568–572
- [14] Park SK, Yang HJ, Jung YS et al. Risk of advanced colorectal neoplasm by the proposed combined United States and United Kingdom risk stratification guidelines. *Gastrointest Endosc* 2018; 87: 800–808
- [15] Lee SK, Chang HJ, Kim TI et al. Clinicopathologic findings of colorectal traditional and sessile serrated adenomas in Korea: a multicenter study. *Digestion* 2008; 77: 178–183
- [16] Kim KM, Lee EJ, Ha S et al. Molecular features of colorectal hyperplastic polyps and sessile serrated adenoma/polyps from Korea. *Am J Surg Pathol* 2011; 35: 1274–1286
- [17] Kim MJ, Lee EJ, Suh JP et al. Traditional serrated adenoma of the colorectum: clinicopathologic implications and endoscopic findings of the precursor lesions. *Am J Clin Pathol* 2013; 140: 898–911
- [18] Torlakovic E, Skovlund E, Snover DC et al. Morphologic reappraisal of serrated colorectal polyps. *Am J Surg Pathol* 2003; 27: 65–81
- [19] Robbins SL, Kumar V, Cotran RS. Robbins and Cotran pathologic basis of disease. 8th edn. Philadelphia, PA: Saunders/Elsevier; 2010