Published online: 2019-11-15

A novel endoscopic treatment for giant gastric bezoars: guidewire-based seesaw-type fragmentation using a specific bezoaratom kit

Although gastrointestinal endoscopy is the routine treatment for small gastric bezoars [1], management of massive bezoars is always difficult even with a specific lithotriptor [2], electrohydraulic lithotripsy [3] or laser fragmentation [4]. At present, surgery is the remedy treatment for such massive bezoars. However, contamination of the peritoneal cavity and remnant bezoars are major problems in surgical treatment [5]. To solve these problems, we established a novel endoscopic guidewire-based seesaw-type lithotripsy of massive gastric bezoars using a specific bezoaratom kit (▶ **Fig. 1**, ▶ **Video 1**).

The patient was a 70-year-old woman with a history of epigastric pain, nausea, and vomiting over 3 months. The gastrointestinal endoscopy revealed a giant yellowish bezoar, 10 cm in diameter, in the gastric corpus (▶ **Fig. 2 a**). The giant gastric bezoar was subjected to the novel endoscopic seesaw-type fragmentation with a specific bezoaratom kit.

The guidewire was folded and inserted into the stomach. Under endoscopic guidance, after the giant bezoar was successfully trapped by the guidewire, the lithotriptor sheath was introduced to tightly hold the bezoar (▶ **Fig. 2 b**). Through several seesaw-type motions of the guidewire and counter movements of the sheath, the giant bezoar was successfully cut into small pieces (▶ **Fig. 2 c**) and then extracted using a string bag (▶ **Fig. 2 d**). Complete extraction of the bezoar was achieved in a single endoscopy session (▶ **Fig. 2 e**) without any damage to the gastric mucosa (▶ **Fig. 2 f**). The total procedure time was only 20 minutes and no post-procedural complications were registered.

In this case, we applied guidewire-based seesaw-type lithotripsy using a specific bezoaratom kit to completely remove a giant bezoar. This novel strategy is very safe and effective to break up the bezoar in a short time, is generally economic as it uses regular instruments, and can be easily manipulated by nonexperienced endoscopists.

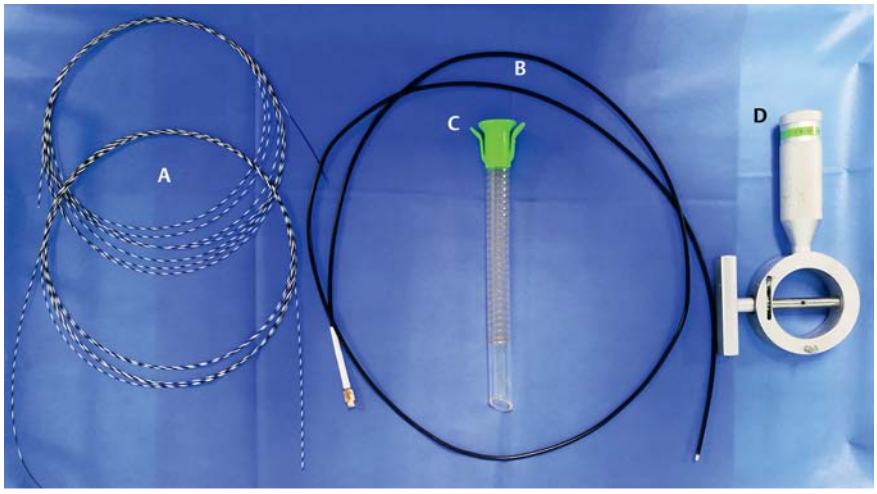

▶ **Fig. 1** The specific bezoaratom kit consists of a regular guidewire (A; Anrui Co., Hangzhou, China), a lithotriptor sheath with metal end (B; Cook Co., Bloomington, Indiana, USA), a flexible overtube (C; Sumitomo Bakelite Co., Tokyo, Japan), and a lithotriptor handle (D; Cook Co.).

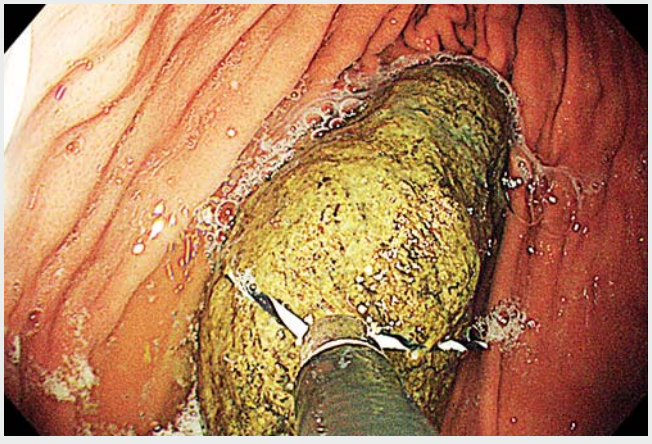

Video 1 Endoscopic treatment for a giant gastric bezoar using guidewire-based seesaw-type fragmentation.

Endoscopy_UCTN_Code_TTT_1AO_2AL

Competing interests

None

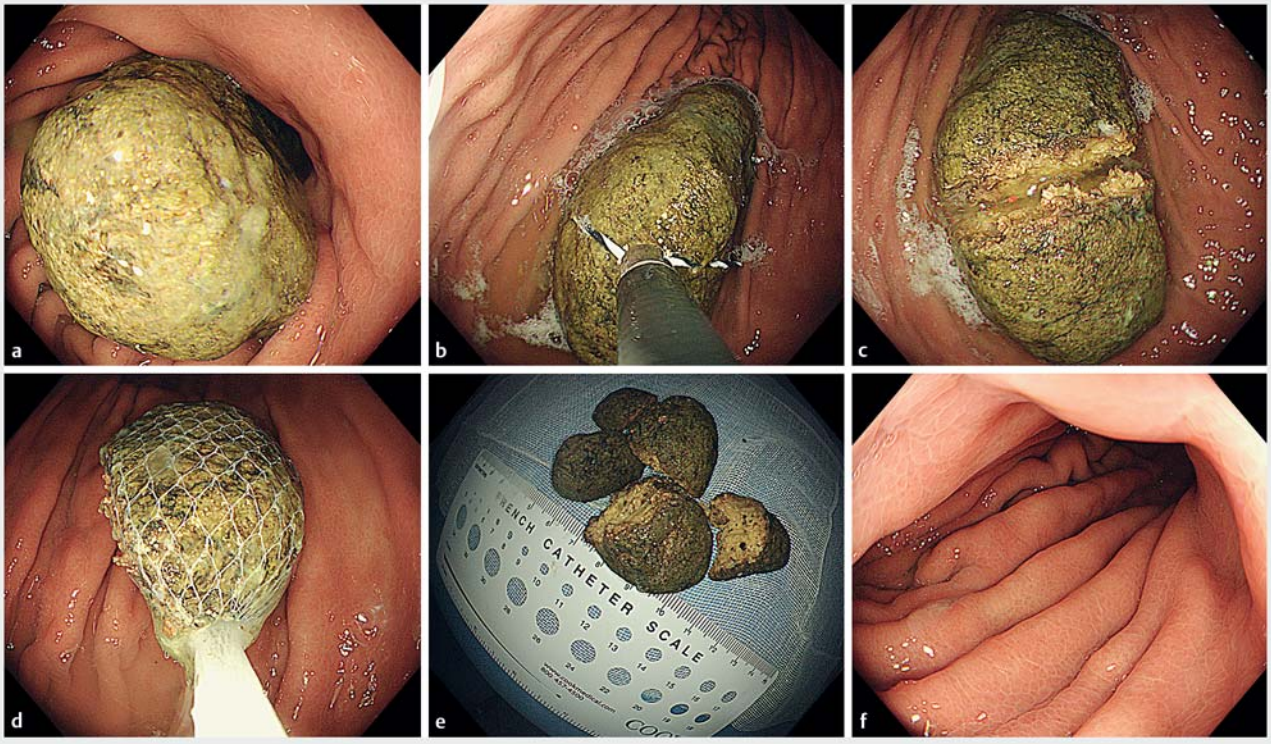

▶ **Fig. 2** The process of removing a giant gastric bezoar using the specific bezoaratom kit. **a** A giant gastric bezoar located in the mid-body of the stomach. **b** The giant bezoar was trapped by the guidewire-formed snare with the help of the sheath. **c** The giant bezoar was successfully fragmented by the specific bezoaratom kit through seesaw-type movements, with or without the lithotriptor handle. **d** The small fragments of the giant bezoar were sequentially extracted using the string bag (Jiuhong Co., Changzhou, China). **e** The bezoar was safely and completely removed under flexible overtube guidance. **f** The gastric mucosa was intact after removal of the bezoar.

The authors

Xiao Hu[1,2,*], Ren-yi Zhang[1,2,*], Wei-hui Liu[1,2]

1 Department of Gastroenterology and Hepatology, Sichuan Academy of Medical Sciences and Sichuan Provincial People's Hospital, Chengdu, China

2 School of Medicine, University of Electronic Science and Technology of China, Chengdu, China

Corresponding author

Wei-hui Liu, MD
Department of Gastroenterology and Hepatology, Sichuan Academy of Medical Sciences and Sichuan Provincial People's Hospital, 32 First Ring Road, Chengdu, Sichuan Province 610072, China
Fax: +86-28-86571251
audiliu12@163.com

* These authors contributed equally to this work.

References

[1] Iwamuro M, Tanaka S, Shiode J et al. Clinical characteristics and treatment outcomes of nineteen Japanese patients with gastrointestinal bezoars. Intern Med 2014; 53: 1099–1105

[2] Kurt M, Posul E, Yilmaz B et al. Endoscopic removal of gastric bezoars: an easy technique. Gastrointest Endosc 2014; 80: 895–896

[3] Kuo JY, Mo LR, Tsai CC et al. Nonoperative treatment of gastric bezoars using electrohydraulic lithotripsy. Endoscopy 1999; 31: 386–388

[4] Grande G, Manno M, Zulli C et al. An alternative endoscopic treatment for massive gastric bezoars: Ho:YAG laser fragmentation. Endoscopy 2016; 48 (Suppl. 01): E217

[5] Ulukent SC, Ozgun YM, Sahbaz NA. A modified technique for the laparoscopic management of large gastric bezoars. Saudi Med J 2016; 37: 1022–1024

Bibliography

DOI https://doi.org/10.1055/a-0982-2661
Published online: 15.11.2019
Endoscopy 2020; 52: E146–E147

ISSN 0013-726X