

The BougieCap – a new method for endoscopic treatment of complex benign esophageal stenosis: results from a multicenter study

Authors

Benjamin Walter¹, Simone Schmidbaur¹, Imdadur Rahman², David Albers³, Brigitte Schumacher³, Alexander Meining¹

Institutions

- 1 InExEn, Klinik für Innere Medizin I, Universitätsklinikum Ulm, Ulm, Germany
- 2 University Hospital of Southampton NHS Foundation Trust, Southampton, United Kingdom
- 3 Klinik für Innere Medizin und Gastroenterologie, Elisabethkrankenhaus, Essen, Germany

submitted 6.12.2018

accepted after revision 16.5.2019

Bibliography

DOI <https://doi.org/10.1055/a-0959-1535>

Published online: 23.7.2019 | Endoscopy 2019; 51: 866–870

© Georg Thieme Verlag KG Stuttgart · New York

ISSN 0013-726X

Corresponding author

Benjamin M. Walter, MD, Klinik für Innere Medizin I, Universitätsklinik Ulm, Albert-Einstein-Allee 23, 89081 Ulm, Germany

Fax: +49-731-50044539

Benjamin.walter@uniklinik-ulm.de

ABSTRACT

Background A major limitation of current treatment strategies for nonmalignant upper gastrointestinal stenoses is the lack of either optical or haptic feedback during dilation. Wire guidance and fluoroscopy is often necessary to control the position.

Methods A novel device for endoscopic dilation, the BougieCap (Ovesco Endoscopy AG, Tübingen, Germany) was evaluated in a prospective multicenter trial. Primary outcome was successful dilation of stenosis and secondary outcome was alteration in dysphagia symptoms in short-term follow-up.

Results 50 patients with benign esophageal strictures were included. Endoscopic bougienage was successful in 96%. Bougienage failed in two cases because of high resistance. Symptoms of dysphagia decreased significantly after bougienage (59.0 points at Day 0 vs. 28.6 points at Day 14; $P < 0.001$). Adverse events were loss of BougieCap into the stomach in two cases; no severe adverse events were reported.

Conclusions Endoscopic treatment of benign stenoses using the BougieCap enabled direct visual control of the bougienage procedure. This might help to adapt treatment more precisely to the stricture. Symptoms of dysphagia were improved in short-term follow-up. Additional wire guidance may be used for selected cases (e.g. narrow lumen, pediatric scope).

Clinical.Trials.gov

NCT03349021

TRIAL REGISTRATION: Multicenter, prospective trial

NCT03349021 at clinicaltrials.gov

Introduction

Nonmalignant strictures in the upper gastrointestinal (GI) tract causing dysphagia have significant impact on patients' quality of life and present challenges to the interventional endoscopist [1, 2]. The underlying pathophysiology of benign strictures of the esophagus is mainly increased production of fibrous tissue following an inflammatory process [3]. Stenotic processes obstructing more than 50% of the esophageal lumen lead to the burdening symptom of dysphagia [4].

Esophageal dilation is the standard procedure for nonmalignant strictures in the upper GI tract. It is effective, providing symptomatic relief in 85%–93% of cases [2, 5, 6]. The ideal technique facilitates a high degree of visibility and control ensuring maximum safety and treatment efficiency.

Dilators include polyvinyl-wire-guided dilators (Savary-Gillard) and balloon dilators (wire-guided and through-the-scope [TTS]) [2]. Bougie dilators rely on tactile perception to determine the amount of resistance encountered with passage through the esophagus under fluoroscopic control. Sequential dilation is performed. The “rule of three” has been generally ac-

cepted but a recent retrospective study found that nonadherence to the rule of three does not increase the risk of adverse events [2, 7]. TTS balloons may be used as an alternative. They are inflated to the desired amount of dilation and then maintained in that position for 30–60 seconds [8]. In a prospective randomized comparison, no clear advantage in the efficiency of using either Savary bougies or balloons could be demonstrated [9].

A major drawback for bougies is the lack of optical feedback. Success or failure can only be evaluated by taking a second look with the endoscope. In addition, complications cannot be prevented but only treated afterwards. TTS balloons allow real-time visualization of the process, but provide no haptic feedback for the endoscopist, and the decision on the appropriate diameter depends on the judgment of the endoscopist [8].


To combine the most desirable aspects of conventional techniques, a clear, tapered cap – the BougieCap – has been developed to be fixed to the front end of an endoscope. The new device may provide optical feedback similarly to TTS balloons and can be used under haptic control. This might help to adjust endoscopic treatment even more precisely to the stricture.

The aim of this prospective multicenter study was to evaluate the feasibility of endoscopic dilation using the BougieCap and improvement of dysphagia-related symptoms in short-term follow-up.


Methods

The BougieCap (Ovesco Endoscopy AG, Tübingen, Germany) is a disposable, clear, conical, over-the-scope cap that can be used for endoscopic treatment of GI stenosis. The endoscope equipped with the cap acts as a mediator for the applied radial and longitudinal force vectors (► Fig. 1, ► Fig. 2). The device is available in several different outer diameters so that the appropriate size can be selected by the endoscopist during first inspection of the stenosis. It can be attached to the tip of standard and pediatric gastroscopes, and secured by circular tape. The endoscope with the BougieCap is inserted into the esophagus and positioned in front of the stenosis. By pushing forward, the scope – cap system is advanced through the stricture under direct vision and bougienage is performed (► Fig. 3). Sequential bougienage can be performed with increasing device diameter, if applicable. If reasonable, the use of a stiff guidewire passed through the working channel and the front hollow core of the attached cap is possible.

A prospective interventional study was conducted at three endoscopy units in Germany (Ulm, Essen) and the United Kingdom (Southampton) between February and July 2018. The patient sample size was 50. Individuals aged > 18 years were enrolled for study participation if the following inclusion criteria applied: benign stenosis of the esophagus with indication for endoscopic dilation, clinical symptoms of dysphagia, written informed consent. Exclusion criteria were lack of agreement by the patient, malignant stenosis or no indication for endoscopic treatment.



► Fig. 1 Longitudinal cut of the BougieCap (Ovesco Endoscopy AG, Tübingen, Germany). Lateral holes allow suction, CO₂ insufflation, and water flushing. The central hole serves as a core for optional insertion of a guidewire. Source: Ovesco



► Fig. 2 Available BougieCap (Ovesco Endoscopy AG, Tübingen, Germany) sizes. a For a standard gastroscope. b For a pediatric gastroscope (10, 8, 7 mm).

The primary end point was success of endoscopic dilation. Success was defined as sufficient dilation of the stenosis in one endoscopic session with endoscopic passage after bougienage.

The secondary end point was improvement of symptoms of dysphagia. Dysphagia-associated symptoms were assessed by the Dysphagia Handicap Index (DHI) questionnaire before treatment (Day 0) and at short-term follow-up 14 days after bougienage (Day 14). DHI is a 25-item patient-reported outcome measurement for assessing the handicapping effect of dysphagia and covers physical, functional, and emotional aspects. A point-rating scale is applied: never (0 points), sometimes (2 points), and always (4 points). Clinical severity groups

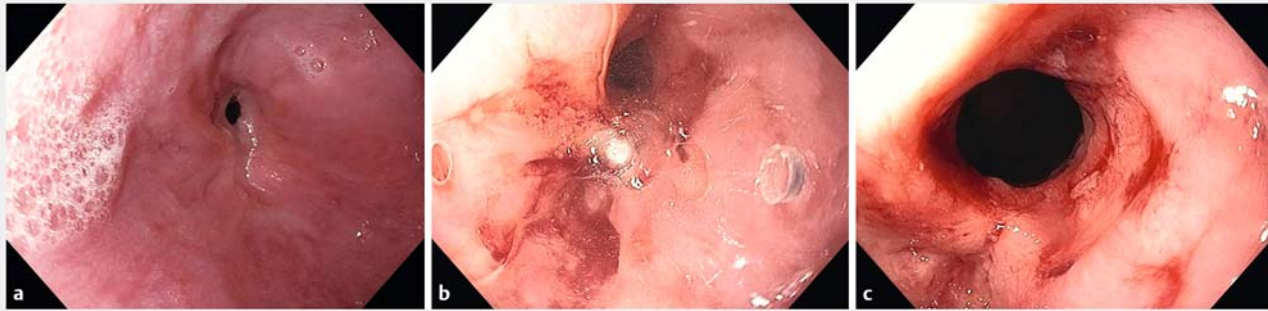


Fig. 3 Endoscopic images. **a** Narrowing esophageal stricture. **b** Dilation with optical control using the BougieCap (Ovesco Endoscopy AG, Tübingen, Germany). **c** Endoscopic aspect after dilation.

(1–4) are defined as normal (no symptoms; <25 points), mild (25–50), moderate (50–75), and severe dysphagia (≥75) [1].

The study was approved by the institutional review board and ethics committee of the University of Ulm (Germany) and was registered at ClinicalTrials.gov (NCT03349021). Written informed consent was obtained from all patients. All authors had access to study data, and they reviewed and approved the final manuscript.

Pentax i10 (9.8 mm), Olympus GIF-H260 (9.8 mm), Olympus GIF-HQ190 or Olympus GIF-XP190N endoscopes were used for endoscopy. The diameter of the BougieCap was chosen by the respective endoscopists. The procedure could be terminated at the discretion of the endoscopist, but particularly if deep tears occurred where the muscle layer was visible or if it was subjectively felt that the resistance was too high.

Statistical tests were performed using SPSS version 24 (IBM Corp., Armonk, New York, USA). Student’s *t* test and Mann-Whitney test were used wherever applicable. A *P* value of <0.05 indicated statistical significance.

Results

A total of 50 patients were recruited across the three centers with a mean age of 67.1 years (range 21–96 years). Further patient and stenosis characteristics are shown in ▶ **Table 1**. The most common cause of stenosis was peptic (46%). According to UK guidelines on esophageal dilation, all strictures were defined before treatment as complex strictures due to narrowed diameter and failed passage with a standard gastroscope. Out of the 50 patients, 32 had undergone previous endoscopic treatment for clinically apparent stenosis.

Endoscopic outcome

Bougienage with the BougieCap, sized accordingly to the diameter of the stenosis, was successfully performed in 48 of the 50 patients (96%) (▶ **Table 2**). In two cases with narrow and longer strictures (one peptic, one post-chemoradiotherapy) located in the lower esophagus (length 40 mm, diameter 2 mm and 3 mm, respectively), bougienage failed due to high resistance, which caused buckling of the endoscope in the pharynx. Bougienage was aborted and balloon dilation was performed successfully.

Table 1 Patient characteristics.

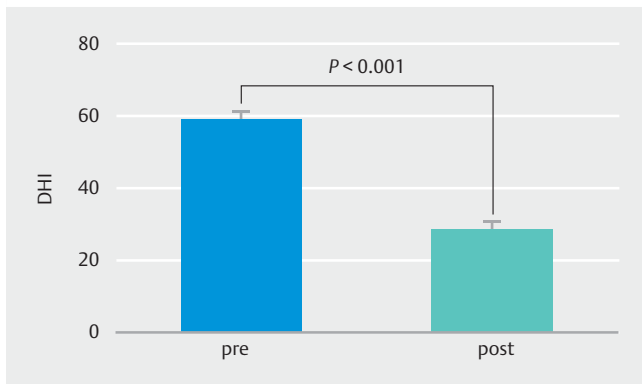
Patient characteristics	
n	50
Sex, m/f, n	25/25
Age, years	
▪ Mean (SD)	67.1 (16.8)
▪ Range	21–96
Origin of stenosis, n (%)	
▪ Peptic	23 (46)
▪ Radiation	13 (26)
▪ Anastomotic	6 (12)
▪ Caustic	4 (8)
▪ Post-ESD	2 (4)
▪ EoE	1 (2)
▪ Unknown	1 (2)
Location, n (%)	
▪ Upper esophagus	7 (14)
▪ Mid-esophagus	14 (28)
▪ Lower esophagus	29 (58)
Diameter of stenosis before intervention, mean (SD), mm	7.5 (2.4)
Length of stenosis, mean (SD), mm	10.7 (8.6)
Previous endoscopic treatment, n	
▪ Yes	32
▪ No	18

ESD, endoscopic submucosal dissection; EoE, eosinophilic esophagitis; SD, standard deviation.

► **Table 2** Endoscopic results of bougienage using the BougieCap¹.

Endoscopic results	
Successful dilation, n	48
No. of BougieCaps used, mean (SD) ²	2.3 (0.7)
Used stiff guidewire, n	
▪ Pediatric gastroscope	8
▪ Standard gastroscope	2
Adverse events (n)	
▪ BougieCap lost	2 (10, 14 mm)

SD, standard deviation.
¹ Ovesco Endoscopy AG, Tübingen, Germany.
² Number of BougieCaps with increasing diameter used in endoscopic session.



► **Fig. 4** The burden of dysphagia assessed by the Dysphagia Handicap Index (DHI) before endoscopic treatment (pre) and in short-term follow-up 14 days after endoscopy (post).

The mean number of sequential bougienages was 2.3. A stabilizing guidewire was used in 10 cases, 8 of which were with a pediatric scope. Reported complications were loss of BougieCaps in two cases. However, in these cases, BougieCaps evacuated spontaneously with the stool. No cases of perforation or prolonged bleedings were reported (► **Table 2**).

Quality-of-life assessment/dysphagia symptoms

Mean dysphagia-associated symptoms, using the DHI, decreased from 59.0 (moderate dysphagia) to 28.6 points (mild dysphagia) over the short-term follow-up period ($P < 0.001$) (► **Fig. 4**).

Discussion

The present multicenter study revealed the technical feasibility of endoscopic treatment of benign esophageal strictures using the BougieCap, with significant reduction in symptoms of dysphagia over short-term follow-up.

Although conventional methods work well in relation to the dilation process, they only provide either haptic or optical pro-

cedural control. With Savary dilators, visual evaluation is not possible until after the treatment and the intervention cannot be adapted to possible major complications such as perforation. With TTS balloons, visual control may be possible, but the examiner does not experience haptic feedback.

A flexible transparent dilator mounted over a standard endoscope, the Optical Dilator (Ethicon, Cincinnati, Ohio, USA), has previously shown successful treatment of strictures using this concept [10]. However, the study was in a smaller select group of patients and its design only enabled a minimum diameter of 14 mm.

The BougieCap guarantees both optical and haptic feedback while being an easy-to-use tool for dilating strictures of various diameters. The direct visual evaluation provides control on endoscopic bougienage procedure and therefore might help to adjust endoscopic treatment even more precisely to the stricture.

Several limitations of the study should be acknowledged. First, the design of the study was a single-arm interventional study, which limits the comparability of the BougieCap and conventional bougienage techniques. Second, the study design only allowed short-term follow-up. It remains unclear whether similar results can be reproduced in a long-term follow-up setting. Third, we acknowledge that the BougieCap may disconnect during intervention, which happened twice in the present study. Nevertheless, the size of the BougieCap allows spontaneous passage through the intestine [11]. Furthermore, to avoid loss of the cap, the circular tape has since been modified to increase stability.

As shown twice in our study, treatment of a complex narrow lumen and longer stricture could be challenging as a result of endoscope buckling. The short tapered design of the BougieCap, compared with the longer tapering of a standard Savary, may not allow for sufficient engagement of the tip within narrower strictures. However, in both cases, no stiff wire was used for additional guidance and straightening of the endoscope. In those cases, the use of wire guidance may be of assistance.

Based on our present experience, we therefore conclude that the newly developed BougieCap enables dilation of esophageal stenosis and improves patients' dysphagia symptoms in short-term follow-up. Hence, it might have the potential to improve conventional endoscopic bougienage.

Competing interests

Dr. Meining is a consultant for Ovesco Endoscopy, Germany

References

- [1] Silbergleit A, Schultz L, Jacobson B et al. The Dysphagia Handicap Index: development and validation. *Dysphagia* 2012; 27: 46–52
- [2] Sami S, Haboubi H, Ang Y et al. UK guidelines on oesophageal dilatation in clinical practice. *Gut* 2018; 67: 1000–1023
- [3] Lew R, Kochman M. A review of endoscopic methods of esophageal dilation. *J Clin Gastroenterol* 2002; 35: 117–126

- [4] Adler D, Siddiqui A. Endoscopic management of esophageal strictures. *Gastrointest Endosc* 2017; 86: 35–43
- [5] Goyal G, Sultania S, Meena B et al. Refractory benign esophageal strictures. *J Dig Endosc* 2016; 7: 1
- [6] Riley S, Attwood S. Guidelines on the use of oesophageal dilatation in clinical practice. *Gut* 2004; 53: (Suppl. 01): i1–6
- [7] Grooteman K, Wong Kee Song L, Vleggaar F et al. Non-adherence to the rule of 3 does not increase the risk of adverse events in esophageal dilation. *Gastrointest Endosc* 2017; 85: 332–337.e1
- [8] Shah P, Kochman M. Alternative techniques for treating benign esophageal strictures. *Tech Gastrointest Endosc* 2016; 12: 225–230
- [9] Saeed Z, Winchester C, Ferro P et al. Prospective randomized comparison of polyvinyl bougies and through-the-scope balloons for dilation of peptic strictures of the esophagus. *Gastrointest Endosc* 1995; 41: 189–195
- [10] Jones M, Bratten J, McClave S. The Optical Dilator: a clear, over-the-scope bougie with sequential dilating segments. *Gastrointest Endosc* 2006; 63: 840–845
- [11] Birk M, Bauerfeind P, Deprez P et al. Removal of foreign bodies in the upper gastrointestinal tract in adults: European Society of Gastrointestinal Endoscopy (ESGE) Clinical Guideline. *Endoscopy* 2016; 48: 489–496