

Gastric mucosal devitalization (GMD): translation to a novel endoscopic metabolic therapy



Authors

Lea Fayad¹, Andreas Oberbach^{1,2}, Michael Schweitzer¹, Frederic Askin¹, Lysandra Voltaggio¹, Tatianna Larman¹, Markus Enderle³, Hartmut Hahn³, Mouen A. Khashab¹, Anthony N. Kalloo¹, Vivek Kumbhari¹

Institutions

- 1 Johns Hopkins Medical Institutions, Baltimore, Maryland, United States
- 2 Fraunhofer Institute for Cell Therapy and Immunology, Leipzig, Germany
- 3 Erbe GmbH, Tübingen, Germany

submitted 14.5.2019

accepted after revision 27.5.2019

Bibliography

DOI <https://doi.org/10.1055/a-0957-3067> |
Endoscopy International Open 2019; 07: E1640–E1645
© Georg Thieme Verlag KG Stuttgart · New York
eISSN 2196-9736

Corresponding author

Vivek Kumbhari, Associate Professor of Medicine, Division of Gastroenterology and Hepatology, Director of Bariatric Endoscopy, Johns Hopkins Medical Institutions, Sheikh Zayed Building, 1800 Orleans Street, Suite 7125G, Baltimore, MD 21287
vkumbhari@gmail.com

ABSTRACT

Background and study aims The metabolic effects of bariatric surgery may partially result from removal of the gastric mucosa, an often underappreciated endocrine organ. Using argon plasma coagulation (APC), we may be able to selectively devitalize (ablate) the mucosa. The aim of this study was to identify the optimal tissue color that would

correspond to selective gastric mucosal devitalization (GMD) using ex-vivo human stomach specimens.

Patients and methods Stomach specimens were obtained at sleeve gastrectomy. Prior to APC application, a submucosal fluid cushion was created. APC was then applied over a 2×2-cm area to the fundus and body, aiming for the three indicator colors (white, golden, brown). Pathological analysis was then performed independently and in a blinded fashion by two pathologists to determine the depth of mucosal and submucosal percent thermal injury and mucosal percent cell death.

Results Six patients were enrolled. There was a significant correlation between tissue color and mucosal percent thermal injury. The highest percent mucosal thermal injury was seen with brown (99.6%, 95% CI: 98.7, 100), followed by golden (92.5%, 95% CI: 85.5, 99.5), and then white (75.2%, 95% CI: 58.3, 92.1, $P < 0.01$). Submucosal thermal injury was seen in 88.9% of the slides. Greater than minimal submucosal injury (>10% depth) was found significantly more with brown tissue color (91.6%) than golden (75%) or white (33.3%, $P < 0.05$). However, 91.7% of the entire sample set <50% injury.

Conclusion GMD is achievable using APC without thermal injury to muscularis propria. A golden color results in sufficient mucosal injury with only superficial injury to the submucosa.

Clinical.Trials.gov

NCT03526263

TRIAL REGISTRATION: Single arm, interventional clinical trial NCT03526263 at clinicaltrials.gov

Introduction

Obesity is a major global health concern and growing epidemic, associated with serious obesity-related comorbidities such as diabetes, metabolic syndrome, hypertension, and tremendous financial impact [1–4]. In the armamentarium of obesity therapies, laparoscopic sleeve gastrectomy (SG) has taken a central

role in the fight against obesity and its related comorbidities. SG was the most commonly performed bariatric surgery in the United States from 2013 to 2017, with a trend of increasing utilization to almost 60% of all bariatric procedures [5]. The physiological, hormonal, and structural changes that contribute to SG-induced weight loss, if well understood, can be manipulated to achieve targeted, minimally invasive strategies for treating obesity.

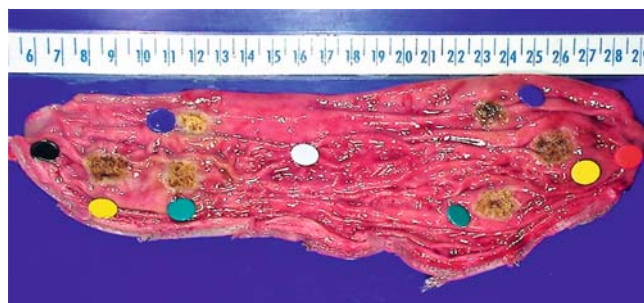
Endoscopic sleeve gastropasty (ESG) uses endoscopic suturing to reduce the lumen of the stomach, resulting in a size similar to that achievable during SG [6, 7]. This procedure achieves the restrictive component of the SG in a minimally invasive manner. However, comparative studies have shown superior weight loss outcomes with SG as compared to ESG [8, 9]. The explanation for this difference may lie in the main anatomical difference between the two procedures. During SG, a significant portion of the stomach is excised, completely removing with it an important and often underappreciated endocrine organ, the gastric mucosa. The gastric mucosa has a potentially large role to play when seeking to create more targeted, safer and minimally invasive weight loss therapies.

One method of targeting the mucosa is use of argon plasma coagulation (APC), an ablation technique that uses thermal energy from ionized argon gas to coagulate or ablate gastrointestinal tissue, which has been used safely and successfully for various indications in the gastrointestinal tract [10, 11]. To minimize risk of deep thermal injury, experiments have attempted submucosal injection of normal saline prior to devitalization [12–14]. In an ex vivo porcine study, this resulted in tissue damage confined to the submucosa [13]. In vivo, damage extended to the muscularis propria 1 week post-ablation if no injection was performed and was limited to the submucosa with prior injection at 1 week [12]. Finally, ex-vivo human studies have confirmed that submucosal injection is protective of the muscularis propria in the stomach and esophagus [14, 15]. These findings indicate that submucosal injection may be a useful method of reducing risk of muscularis propria damage from APC but in these studies, selective ablation of mucosa was not attempted.

Gastric mucosal devitalization (GMD) is an endoscopic procedure that uses APC to selectively ablate the gastric mucosa while using submucosal fluid injection to keep the deeper layers intact [16, 17]. GMD has been validated by our group in rat and porcine models of obesity with very promising metabolic and weight outcomes. After the success of GMD in animal models, it was time to translate this procedure to humans, ex vivo. The objective was to determine what dosage of APC with submucosal injection can selectively devitalize the human gastric mucosa, without injuring the deep submucosa or any portion of the muscularis propria. There is a known progression of tissue color from white to golden to brown and eventually black with increasing doses of APC. This study's primary aim was to identify the optimal tissue color (white, golden, brown) that would correspond to selective GMD without damage to the deep submucosa or muscularis propria using ex vivo human stomach specimens. Secondary aims included identifying optimal technical parameters (submucosal injection volume and energy settings) to facilitate selective mucosal devitalization.

Patients and methods

This study was performed under IRB00089675 at the Johns Hopkins Medicine Institutional Review Board and registered on clinicaltrials.gov under NCT03526263. Patients were enrolled in the study after being scheduled to undergo laparoscopic SG



► **Fig. 1** Excised SG specimen after submucosal injection and gastric mucosal devitalization (GMD) by means of submucosal injection and argon plasma coagulation of three areas in the body and three areas in the fundus. Each gastric fundus and each gastric body had three ablated areas (one white, one golden and one brown) representing the three different devitalization dosages. The black pin indicates the body and the red pin indicates the fundus. The white pin was placed to indicate an area that was treated only with submucosal injection as control for histological analysis. A colored pin (green, blue or yellow) was placed near each ablated area and was used by the pathologist to label the tissue slides (for example, a section taken from the fundus and labeled with a blue pin would be titled “fundus blue”). From each area, microscopic sections were made for analysis.

as part of routine clinical care at Johns Hopkins Bayview Medical Center.


Patients were consented for the research study at the time of obtaining their consent for surgery. As this was an ex vivo study on a resected SG specimen, no compensation was offered to patients. The cost of surgery was covered by a patient's insurance and there was no extra procedural element that added time to surgery. During routine surgery, after the greater curvature of the stomach was excised as per normal surgical technique, the specimen was taken from the operating room into the laboratory where experimentation was performed.

SG specimen preparation

The SG specimen was taken immediately from the operating room (within 10 minutes of excision) and immersed in warmed normal saline. Then, the specimen was cut along the suture line to expose the body and fundus. It was washed using warm saline to remove any residual clotted blood. The SG specimen was then flattened onto the neutral electrode (NessyPlate 170 cm²) to avoid folds on the serosal side and to improve conduction. The neutral electrode was connected to the electrosurgical unit (ESU) and wrapped in aluminum foil to further improve conductivity.

Specimen treatment

In each SG specimen, the protocol called for six areas of devitalization, three in the fundus and three in the body (► **Fig. 1**). Prior to each devitalization, a submucosal injection using normal saline (0.9% NaCl) mixed with methylene blue was first performed with a flexible waterjet probe connected to an ERBEJET2 (ERBE Elektromedizin GmbH, Tübingen, Germany). The ERBEJET is a needleless waterjet injection system that is used to create a submucosal fluid cushion underneath the mucosa to protect



► **Fig. 2** **a** Flexible APC filter integrated probe for mucosal ablation with axial probe tip. **b** The 3.6 FiAPC has an outer diameter (OD) of 3.6 mm/ 10.8 FR, a length of 2.2 m/7.2 ft, with an axial (straight fire) beam. The FiAPC 3.6 is a modified version of the commercially available 2.3 FiAPC Probe. The probe tip OD is 3.6 mm instead of 2.3 mm. An integrated ceramic tip has been added for higher thermal stability. Both FiAPC probes work in conjunction with the APC 2-Module and the VIO 300 D to ablate tissue. **c, d** Ablation track on pig stomach tissue (body). **d** The track of the 3.6 mm probe is approximately 20% wider than the track of 2.3 probe **c** allowing for more efficient area ablation.

the muscularis propria from thermal damage of APC during interventional endoscopic procedures of the gastrointestinal tract. An additional advantage of injection in this study was to flatten out, stretch, and thin out the mucosa for more efficient and complete ablation of larger surface areas. In all specimens, submucosal injection was performed with the effect setting 50. Volume of injection (mL) varied in each devitalization, depending on the amount needed to create an appropriate cushion.

Once the cushion was created, APC was applied using the ERBE VIO 300D ESU in combination with the APC2 module and a 3.6-mm FiAPC probe (► **Fig. 2**), with a larger outer diameter of the distal tip than the 2.3-mm catheter, for better efficiency of devitalization of a larger surface area. The APC settings applied were Pulsed APC, Effect 2, flow rate 1 L/minutes, 60 to 75 W. Three areas of the fundus and three areas of the body were ablated in each stomach specimen aimed to be a size of 1 × 1 cm. Devitalization with APC was performed at a 90-degree angle, at a distance of 2 to 4 mm from the tissue. Indicator colors used were white, golden, and brown as assessed visually by the proceduralist. Therefore, each gastric fundus and gastric body had three ablated areas (one white, one golden and one brown).

The SG specimen was then taken to the Johns Hopkins pathology lab for gross and histopathological analysis to determine depth of devitalization. Only a small portion of the resected SG specimen was treated with APC, such that the remainder was suitable for routine pathological analysis as per the standard of care. A colored pin (green, blue or yellow) was placed near each ablated area and used by the pathologist to label the tissue slides (for example, a slide taken from the fundus and labeled with a blue pin would be titled “fundus blue”) (► **Fig. 1**). A black pin was placed to indicate the body and a red pin to indicate the fundus. Each slide was reviewed by two independent pathologists and results were aggregated into an average. The pathologist who carried out the histopathological examination did not participate in tissue slide preparation. The pins were placed randomly to keep the reading pathologist unaware of the color of the tissue and the devitalization settings. In every patient, two random biopsy samples were also included as a control. Two sections

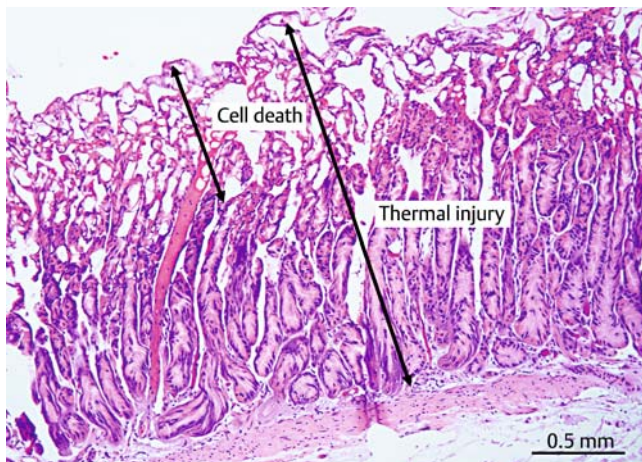
were cut from each lesion and formalin fixed, paraffin embedded, and H&E stained. The study was performed using a staged approach. Pathological results for every two consecutive patients were analyzed at the same time and the devitalization method was adjusted in the subsequent patients based on the histopathological analysis results obtained in the previous two patients.

Outcomes

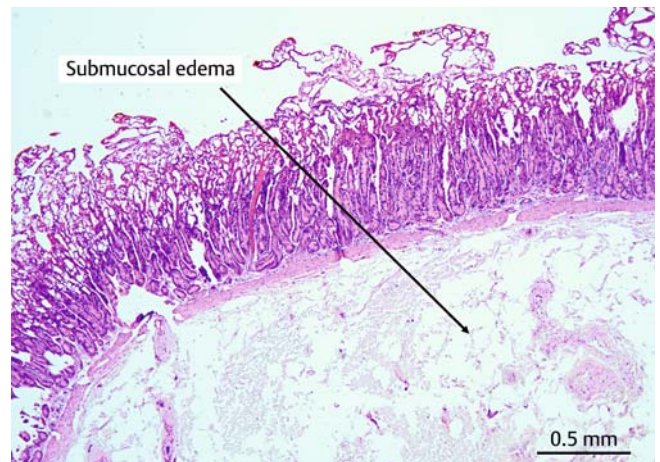Outcomes recorded in this study included percent cell death and percent depth of thermal injury as determined by the pathologists. Thermal injury was defined as abnormal and distorted cellular outlines and architecture that would not otherwise be seen in a normal biopsy. Cell death was defined as thermal injury that had resulted in apparent cellular death defined as loss and distortion of tissue structure resulting in a compressed appearance and absence of nuclei in cells. Percent thermal injury and percent cell death were defined as percent depth of thermal injury and cell death relative to the entire depth of the mucosa (► **Fig. 3**). Percent submucosal injury could not be accurately quantified due to submucosal edema. Thus, the submucosal injury was dichotomized into a binomial variable using a threshold of 10%, with less than 10% considered minimal injury. The threshold was chosen at 10% because clinically, the submucosa can serve as a buffer zone between the mucosa and muscularis propria where some injury is acceptable. Length of the excised stomach was also recorded.

Statistical analysis

Statistical analysis was conducted using STATA 15.0 (StataCorp LP, College Station, Texas, United States). Tests of hypothesis for categorical variables were performed using χ^2 test. Tests of hypotheses for continuous variables were performed using Student's t test for dependent and independent samples. Linear regression analysis was used to assess correlations between continuous variables. $P < 0.05$ was considered significant.



► **Fig. 3** Image of a pathology slide of gastric mucosa after GMD showing areas of “cell death” versus “thermal injury.” The cell death region is characterized by loss and distortion of tissue structure showing a “mushy” appearance and absence of nuclei in cells. The thermal injury region is characterized by altered cell architecture with fragmented and elongated nuclei (Scale: 0.5 mm).



► **Fig. 4** Image of a pathology slide of gastric mucosa after GMD showing the fluid cushion in the submucosa underneath resulting in submucosal edema. Edema is an effect expected from persistence of the fluid cushion after submucosal injection and the successive argon plasma coagulation (Scale: 0.5 mm).

Results

Six patients were enrolled in this study, resulting in 36 specimens (18 from the gastric body and 18 from the fundus). On average, length of the excised SG specimen was 19.3 cm (SD = 1.96). In the first two patients, devitalization was performed at 60 W. At 60 W, the muscularis propria was not damaged, so wattage was increased to 75 W for the remainder of the study aiming, for greater effectiveness. In addition, the fluid cushion was significantly reduced in the remainder of the study, from a mean of 11.1 mL in the first two patients to a mean of 3.9 mL in the last four patients. The correlation between the number of seconds of APC devitalization and the resultant tissue color was not statistically significant, but number of seconds was greater in brown tissue (13.9 seconds, 95% CI: 9.2, 18.5), than golden (10.9 seconds, 95% CI: 6.79, 15.04), than white (8 seconds, 95% CI: 5.04, 10.95), $P = 0.11$.

Slides from the random biopsies acting as control were all read by the pathologists as normal biopsies with 0% thermal injury. Analysis of the treatment slides revealed significant thermal injury of varying degrees in addition to submucosal edema, which represented persistence of the fluid cushion created by submucosal injection prior to devitalization (► **Fig. 4**). To determine whether fluid injection alone can cause mucosal injury, a one-time pathological analysis was performed on a SG specimen that was only injected but not ablated. The result was submucosal edema without any mucosal damage.

Mucosal thermal injury was found in all of the samples. Mean mucosal percent depth of thermal injury was $89.1 \pm 20.4\%$. Mucosal cell death was seen in most of the samples (97.2%). Mean percent mucosal cell death was $26.9 \pm 13.5\%$. Mucosal percent depth of thermal injury did not correlate with volume of injection (coef.: -0.45 , $P = 0.57$, 95% CI: $-2.1, 1.2$), number of seconds of devitalization (coef.: 0.04 , $P = 0.94$, 95% CI: $-0.97, 1.04$), or wattage applied (coef.: 0.47 , $P = 0.33$, 95% CI: $-0.5, 1.4$). However,

there was a significant correlation between tissue color and mucosal percent depth of thermal injury. The greatest mucosal percent depth of thermal injury was seen with brown (99.6%, 95% CI: 98.7, 100), followed by golden (92.5%, 95% CI: 85.5, 99.5), and then white (75.2%, 95% CI: 58.3, 92.1, $P < 0.01$).

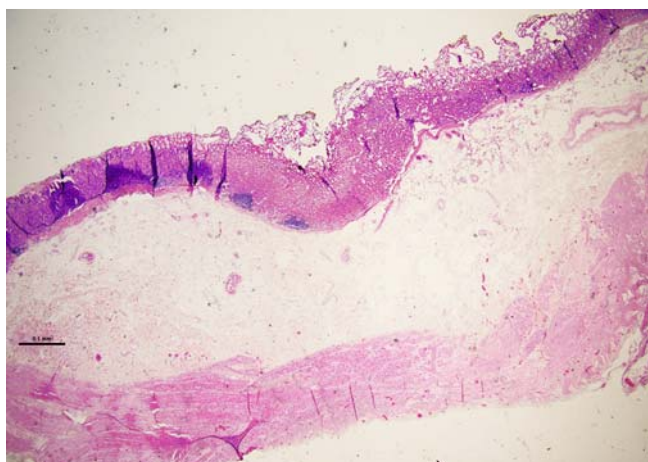
Submucosal thermal injury was seen in 88.9% of the samples. However, 33.3% of the samples had minimal ($\leq 10\%$) injury and 91.7% of the samples had $\leq 50\%$ injury. The greatest submucosal injury assessed in all samples was 55%. Greater than minimal submucosal injury ($> 10\%$) was found significantly more with brown tissue color (91.6%) than golden (75%) and white (33.3%, $P < 0.05$). Importantly, all sections revealed an intact muscularis propria with no evidence of thermal injury or cell death (► **Fig. 5**).

An incidental finding on pathological analysis was lifting of the mucosal cells off the basement membrane as can be seen in ► **Fig. 6**. Lifting may be an artifact; however, because 44.4% of samples exhibited this finding, it is worthy of note.

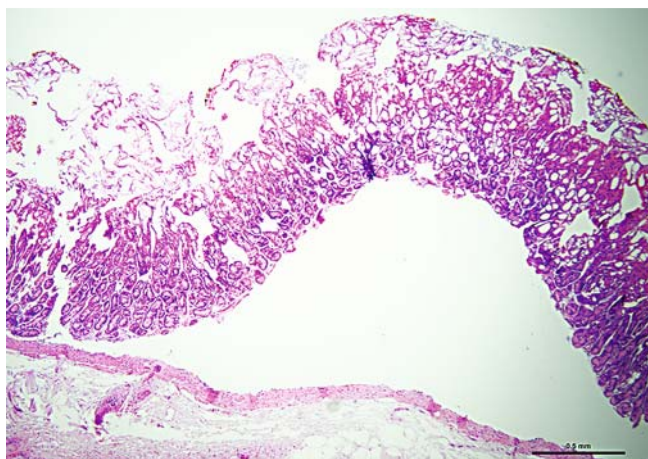
Discussion

The findings confirm that gastric mucosal devitalization using APC is achievable in the human stomach, using the superficial submucosa as a buffer zone, without damage to the muscularis propria. At 60 to 75 W, devitalization to white, golden, or brown colors resulted in sufficient depth of mucosal thermal injury and extent of cell death. The submucosa exhibited superficial thermal injury in addition to edema, an expected finding resulting from submucosal injection that was carried out prior to devitalization to protect the muscularis propria.

Importantly, this study found an association between tissue color and mucosal and submucosal thermal injury, with greater thermal injury found in darker tissue color. The association between tissue color and thermal injury suggests that color is an appropriate indicator for pathological effect, confirming com-



► **Fig. 5** Image of a pathology slide of gastric mucosa after GMD showing an intact muscularis propria (Scale: 0.1 mm).



► **Fig. 6** Image of a pathology slide demonstrating the "lifting" of the mucosa off the basement membrane (Scale: 0.5 mm).

mon clinical experience. Tissue color was found to be a reliable and feasible method of determining depth of devitalization, which would allow its use as a clinical indicator for endoscopic GMD by the endoscopist throughout the intervention.

It has been shown that the extent of gastric tissue damage from APC is associated with pulse duration and power settings [14, 18]. However, this study found the same effect at 60 and 75 W, and the authors would suggest to aim for a dose between 60 to 75 W *in vivo* for GMD to achieve a necessary depth of devitalization without compromising patient safety. Similarly, because all tissue colors correlated with mucosal thermal injury without muscularis propria injury, any tissue color is feasible and may be used *in vivo*. We found no evidence to show that the muscularis propria is injured with any color due to the protective effect of the submucosal cushion. However, we expect the effect of devitalization to continue to increase for 3 days post-devitalization, as apoptosis continues to occur in living tissue. Thus, we suggest using golden as the appropriate color indicator *in vivo*, because it achieves sufficient mucosal injury

and with an acceptable amount of submucosal injury. It also allows for a margin of error, as minor overtreatment towards brown or minor undertreatment towards white, will not compromise the procedures safety nor efficacy.

GMD performed in a rat model was able to achieve significant relative weight reduction as well as reduction in the lipid content of liver, subcutaneous, and visceral adipose tissue [17]. In a porcine model, GMD was also able to achieve relative weight loss and reduction in lipid content of heart and skeletal muscle. Notably, in that study, porcine mucosa regenerated after 8 weeks, but with a persistent reduction in serum ghrelin levels [16]. Ghrelin-producing cells of the gastric mucosa targeted by GMD may have taken longer to regenerate than other mucosal cells, contributing to continued metabolic effects and weight loss. Indeed, the endocrine effect caused by removal of the gastric mucosa is likely more complex and deserves further study to be fully understood.

Efficacy findings from the animal studies in addition to the safety findings from this *ex vivo* human study suggest that this procedure has the potential to be both safe and effective *in vivo* for treatment of obesity. When considering clinical adoptability, concern may arise regarding procedure time to achieve full devitalization. This is mitigated by two factors. First, studying the size of the excised stomach has allowed us to note that the surface area to ablate was less than originally thought. In the rat and porcine studies, 70% of the mucosa was targeted for devitalization. However, in humans, if devitalization is targeted only along the same distribution as the removed stomach during SG, it would take significantly less time. Second, the novel 3.6-mm APC catheter (as opposed to the 2.3-mm catheter) plays a role, as it has a ceramic tip for improved heat resistance and it also allows for a wider area of ablation to facilitate more efficient devitalization. The data presented may be translatable to other gastric mucosal diseases. For example, submucosal injection followed by ablation to a golden color can be recommended to treat mucosal pathology in the stomach such as gastric antral vascular ectasia (GAVE) and flat dysplasia not easily amenable to resection.

This study provides valuable information that supports performing the procedure *in vivo*; however, it has limitations. The main limitations relate to the study set-up. Conductance of the system may have been reduced *ex vivo*. Despite attempts to warm the SG specimen, the final temperature may have been lower than body temperature, which may have also affected conduction. In addition, because the stomach is a closed space and the procedure was performed in open air, the argon gas effect may have been diminished. *In vivo*, blood flow may provide a heat sink effect that may also affect the results. Another limitation is that the view with the endoscopic is different than with the naked eye and the color variation may be different *in vivo*, limiting interpretation. Finally, interpretation of color remains relatively subjective. Nevertheless, color seems to be the most reliable clinical indicator. Because the number of seconds of devitalization did not correlate with the final color or the pathological outcome, the number of seconds cannot be used as a reliable parameter representing "dose." Thus, despite

its apparent subjectivity, use of color as the dose measure is suggested.

The results of this study, in conjunction with the results from our pig and the rat obesity model showing reduction of body weight and visceral adiposity indicate that GMD is ready to be replicated in vivo in the human stomach [16, 17]. The 3.6-mm APC catheter is very promising as it allows a wider surface area of devitalization in a short time. In the future, selective mucosal devitalization may be achievable through other thermal methods (such as cryotherapy) or non-thermal methods (by potentially finding injectable substances into the mucosa/submucosa or a gel solution being sprayed onto the mucosa). At the moment, however, devitalization with APC preceded by submucosal injection of normal saline, which is known to be harmless to the gastric wall, seems to be the most optimal method.

Conclusion

This study demonstrates that APC after submucosal injection can achieve mucosal devitalization in a human stomach specimen at any indicator color safely with superficial submucosal injury and without injury to the muscularis propria. This corroborates the safety of the procedure and opens the door for GMD as a primary obesity therapy that targets the gastric mucosa. We suggest using golden as the appropriate color indicator in vivo because it achieves the greatest efficacy of mucosal injury with an acceptable amount of superficial submucosal injury. Future studies are underway aiming to confirm technical feasibility, tolerability, and safety of GMD in vivo (NCT03638843).

Acknowledgements

The authors thank Pathology Assistants Lynne Sakowski and Michele Conti for performing gross inspection and labeling of the specimens in addition to providing help and guidance for running experiments in the laboratory.

Competing interests

Dr. Khashab is a consultant for Boston Scientific and Olympus America. Dr. Kalloo is a founding member, equity holder and consultant for Apollo Endosurgery. Dr. Kumbhari is a consultant for Pentax Medical, Boston Scientific, Apollo Endosurgery, ReShape Life Sciences, and Medtronic. He receives research support from ERBE USA and Apollo Endosurgery. Dr. Votaggio has received salary support from C2 Therapeutics. This study was supported by Erbe Elektromedizin GmbH, Tübingen, Germany.

References

- [1] Finkelstein EA, Trogdon JG, Cohen JW et al. Annual medical spending attributable to obesity: payer- and service-specific estimates. *Health Aff (Millwood)* 2009; 28: w822–w831
- [2] Flegal KM, Carroll MD, Ogden CL et al. Prevalence and trends in obesity among US adults, 1999–2008. *JAMA* 2010; 303: 235–241
- [3] Ng M, Fleming T, Robinson M et al. Global, regional, and national prevalence of overweight and obesity in children and adults during 1980–2013: a systematic analysis for the Global Burden of Disease Study 2013. *Lancet* 2014; 384: 766–781
- [4] Nguyen NT, Magno CP, Lane KT et al. Association of hypertension, diabetes, dyslipidemia, and metabolic syndrome with obesity: findings from the National Health and Nutrition Examination Survey, 1999 to 2004. *J Am Coll Surg* 2008; 207: 928–934
- [5] English WJ, DeMaria EJ, Brethauer SA et al. American Society for Metabolic and Bariatric Surgery estimation of metabolic and bariatric procedures performed in the United States in 2016. *Surg Obes Relat Dis* 2018; 14: 259–263
- [6] Barola S, Chen YI, Ngamruengphong S et al. Technical aspects of endoscopic sleeve gastropasty. *Gastrointest Endosc* 2017; 85: 862
- [7] Lopez-Nava G, Galvao MP, Bautista-Castano I et al. Endoscopic sleeve gastropasty: How I do it? *Obes Surg* 2015; 25: 1534–1538
- [8] Fayad L, Adam A, Schweitzer M et al. Endoscopic sleeve gastropasty versus laparoscopic sleeve gastrectomy: a case-matched study. *Gastrointest Endosc* 2019; 89: 782–788
- [9] Novikov AA, Afaneh C, Saumoy M et al. Endoscopic sleeve gastropasty, laparoscopic sleeve gastrectomy, and laparoscopic band for weight loss: How do they compare? *J Gastrointest Surg* 2018; 22: 267–273
- [10] Johans W, Luis W, Janssen J et al. Argon plasma coagulation (APC) in gastroenterology: experimental and clinical experiences. *Eur J Gastroenterol Hepatol* 1997; 9: 581–587
- [11] Sagawa T, Takayama T, Oku T et al. Argon plasma coagulation for successful treatment of early gastric cancer with intramucosal invasion. *Gut* 2003; 52: 334–339
- [12] Fujishiro M, Kodashima S, Ono S et al. Submucosal injection of normal saline can prevent unexpected deep thermal injury of Argon plasma coagulation in the in vivo porcine stomach. *Gut Liver* 2008; 2: 95–98
- [13] Fujishiro M, Yahagi N, Nakamura M et al. Submucosal injection of normal saline may prevent tissue damage from argon plasma coagulation: an experimental study using resected porcine esophagus, stomach, and colon. *Surg Laparosc Endosc Percutan Tech* 2006; 16: 307–311
- [14] Gong EJ, Ahn JY, Jung HY et al. Effects of argon plasma coagulation on human stomach tissue: An ex vivo study. *J Gastroenterol Hepatol* 2017; 32: 1040–1045
- [15] Manner H, Neugebauer A, Scharpf M et al. The tissue effect of argon plasma coagulation with prior submucosal injection (Hybrid-APC) versus standard APC: A randomized ex-vivo study. *United European Gastroenterol J* 2014; 2: 383–390
- [16] Kumbhari V, Lehmann S, Schlichting N et al. Gastric mucosal devitalization is safe and effective in reducing body weight and visceral adiposity in a porcine model. *Gastrointest Endosc* 2018; 88: 175–184
- [17] Oberbach A, Schlichting N, Heinrich M et al. Gastric mucosal devitalization reduces adiposity and improves lipid and glucose metabolism in obese rats. *Gastrointest Endosc* 2018; 87: 288–299 e286
- [18] Watson JP, Bennett MK, Griffin SM et al. The tissue effect of argon plasma coagulation on esophageal and gastric mucosa. *Gastrointest Endosc* 2000; 52: 342–345