Mini-invasive treatment of sump syndrome: OverStitch choledochoduodenostomy revision

A 72-year-old woman, who was unfit for surgery, was admitted with recurrent cholangitis. She had a history of cholecystectomy and side-to-side choledochoduodenostomy (CDD) for huge impacted stones. In the previous year, she had undergone multiple endoscopic retrograde cholangiopancreatographies (ERCPs) with endoscopic sphincterotomy, incomplete stone extractions, and plastic stent placement in a local hospital. Magnetic resonance cholangiography showed multiple stones throughout the biliary tree, which was dilated up to 4 cm, along with an incarcerated plastic stent.

Endoscopy with a frontal-view scope (GIF-1TH190; Olympus Europe) confirmed a 25-mm CDD in the duodenal bulb (▶ **Fig. 1**). Management of the huge impacted stones by conventional techniques was not feasible; therefore, a 1.9-Fr bipolar electrohydraulic lithotripsy probe (Autolith; Northgate Technologies Inc.) was passed through the working channel of the endoscope to break the stones under direct cholangioscopy guidance (▶ **Fig. 2**). The scope channel allowed the removal of all fragments. Final fluoroscopy revealed a large diameter, atonic, empty biliary tree with delayed biliary outflow. A plastic stent was then inserted from the common bile duct to the duodenum, through the papilla, to promote drainage (▶ **Fig. 3**).

The patient returned 1 month later because of cholangitis. Endoscopy revealed a large amount of food debris in the biliary reservoir; a diagnosis of sump syndrome was made. Complete extraction of the food matter was performed. In order to prevent the recurrence of duodenocholedochal reflux, we decided to perform a stoma revision using the OverStitch device (Apollo Endosurgery; Austin, Texas, USA) to reduce the size of the CDD, leaving enough room for biliary outflow (▶ **Video 1**). There were no post-procedural complications. The patient has remained asymptomatic during 1 year of follow-up (▶ **Fig. 4**).

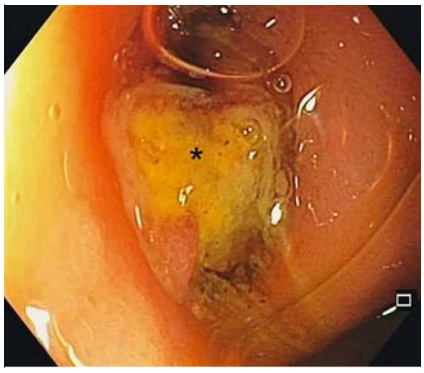

▶ **Fig. 1** Endoscopic view showing a side-to-side choledochoduodenostomy with impacted stones (asterisk) that were causing biliary obstruction and acute cholangitis.

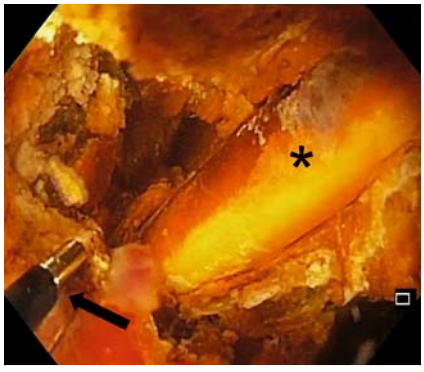

▶ **Fig. 2** Cholangioscopic view showing the electrohydraulic lithotripsy probe (arrow) located 1 – 2 mm from the surface of the gallstones, and ready to generate optimal fragmentation pressure under direct endoscopic control. In the common bile duct an incarcerated plastic stent is easily recognizable (asterisk).

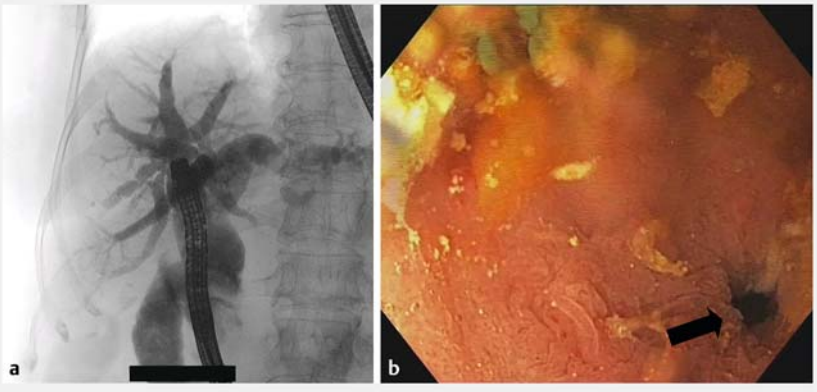

▶ **Fig. 3** Images following the removal of stone fragments showing: **a** atony and marked dilation of the biliary tree (the endoscope is easily recognizable inside the intrabiliary ducts with direct access through the choledochoduodenostomy); **b** antegrade endoscopic placement of a biliary plastic stent from the common bile duct to the second part of the duodenum (major papilla area; asterisk).

Sump syndrome is a rare long-term complication of CDD, with a reported prevalence of 2.5 % [1]. Endoscopic sphincterotomy is the treatment of choice but, if endoscopic treatment fails, surgery is advisable [2]. Evidence concerning endoscopic closure of a CDD is lacking [3 – 5]. This is the first report detailing an endoscopic revision of a CDD using endoscopic suturing.

Endoscopy_UCTN_Code_TTT_1AR_2AG

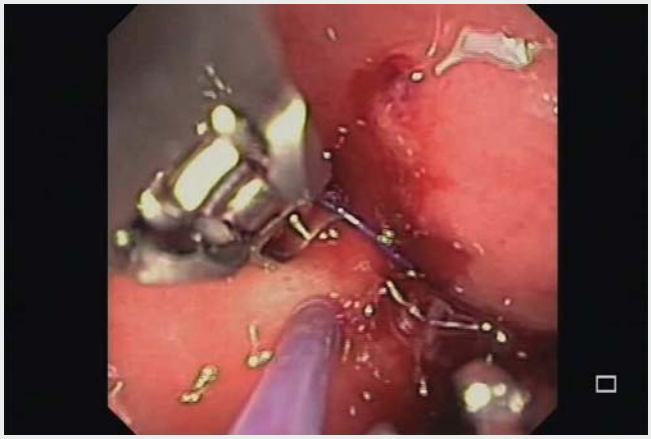

Video 1 Management of sump syndrome by electrohydraulic lithotripsy under direct cholangioscopy view and by choledochoduodenostomy revision using an endosuturing system

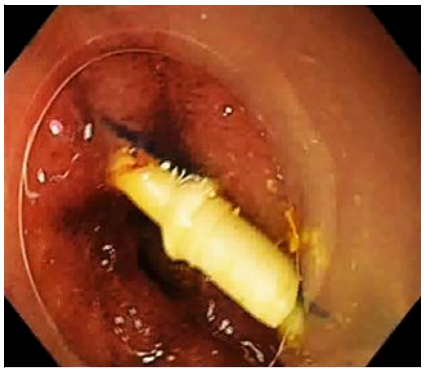

▶ **Fig. 4** Follow-up endoscopic evaluation at 2 months showing a reduced caliber of the choledochoduodenostomy, with no evidence of lithiasis or food/debris inside.

Competing interests

None

The authors

Antonino Granata[1], Michele Amata[1], Alberto Martino[1], Dario Ligresti[1], Sergio Li Petri[2], Calogero Ricotta[2], Mario Traina[1]

1 Digestive Endoscopy Service, Department of Diagnostic and Therapeutic Services, IRCCS-ISMETT, Palermo, Italy
2 Abdominal Surgery and Organ Transplantation Unit, Department for the Treatment and Study of Abdominal Diseases and Abdominal Transplantation, IRCCS-ISMETT, Palermo, Italy

Corresponding author

Antonino Granata, MD
Endoscopy Service, IRCCS-ISMETT, Via Tricomi 5, 90127 Palermo, Italy
Fax: +39-091-2192400 (specify Endoscopy Service)
agranata@ismett.edu

References

[1] Leppard WM, Shary TM, Adams DB et al. Choledochoduodenostomy: is it really so bad? J Gastrointest Surg 2011; 15: 754–757
[2] Caroli-Bosc FX, Demarquay JF, Peten EP et al. Endoscopic management of sump syndrome after choledochoduodenostomy: retrospective analysis of 30 cases. Gastrointest Endosc 2000; 51: 180–183
[3] Ell C, Boosfeld C, Henrich R et al. Endoscopic treatment of the "sump syndrome" after choledochoduodenostomy: a new technique using an amplatzer septal occluder. Z Gastroenterol 2006; 44: 1231–1235
[4] Ellison JC, Tarnasky PR. Endoscopic management of sump syndrome: closure of choledochoduodenostomy. Gastrointest Endosc 2014; 80: 725–726
[5] Ersoz G, Tekin F, Turan I et al. A novel method for closure of a choledochoduodenostomy in sump syndrome. Endoscopy 2015; 47 (Suppl. 01): E365–E366

Bibliography
DOI https://doi.org/10.1055/a-0919-4318
Published online: 4.6.2019
Endoscopy 2019; 51: E337–E338

Stuttgart · New York
ISSN 0013-726X