

Practical applications and learning curve for EUS-guided hepaticoenterostomy: results of a large single-center US retrospective analysis



Authors

Theodore W. James, Todd H. Baron

Institution

Division of Gastroenterology and Hepatology, Department of Medicine, University of North Carolina School of Medicine, Chapel Hill, North Carolina, United States

submitted 12.9.2018

accepted after revision 11.2.2019

Bibliography

DOI <https://doi.org/10.1055/a-0867-9599> |

Endoscopy International Open 2019; 07: E600–E607

© Georg Thieme Verlag KG Stuttgart · New York

ISSN 2364-3722

Corresponding author

Todd Huntley Baron, MD, 130 Mason Farm Road, CB 7080, Chapel Hill, NC 27599

Fax: +1-984-974-0744

todd_baron@med.unc.edu

ABSTRACT

Background and study aims Endoscopic ultrasound-guided hepaticoenterostomy (EUS-HE) is an effective method of endoscopic biliary drainage in cases where endoscopic retrograde cholangiopancreatography has failed or is deemed impossible. Indications for EUS-HE have expanded, resulting in increased interest by endoscopists to learn the procedure; however, few data exist on breadth of appli-

cation or experience needed to develop proficiency. We describe utilization of EUS-HE for biliary decompression at a large tertiary referral center along with procedural learning curve.

Patients and methods Retrospective evaluation of 60 consecutive patients who underwent attempted EUS-HE by one endoscopist from February 2016 through June 2018. Procedures were divided into chronological and summative experience quartiles. We compared procedural success rate, procedural utilization, and procedure duration over time.

Results Sixty patients underwent attempted EUS-HE during the study period: 35 with surgically altered anatomy, 23 with malignant biliary obstruction, 35 outpatients, 35 females; median age, 66 years. The procedure was technically successful in 53 patients. Success rates by summative experience quartile were 80%, 80%, 93.3% and 100% respectively. Beginning at patient number 40, the remaining cases had a success rate of 100%. Utilization increased from eight cases in the first chronological quartile to 28 in the fourth. There was no significant reduction in procedure duration over time.

Conclusion For an experienced endoscopist, EUS-HE could be performed effectively and safely after the experience of 40 cases. Limitations of this study include a single endoscopist and heterogeneous patient population with variable anatomy that may affect procedural success. Future studies should include data from multiple centers and endoscopists.

Introduction

Endoscopic retrograde cholangiopancreatography (ERCP) remains the preferred method of biliary drainage due to high technical success rate and acceptable adverse event rate [1]. Historically, when ERCP fails or is deemed impossible, percutaneous transhepatic biliary drainage (PTBD) is attempted. While often technically successful, PTBD has several notable disadvantages including risk of bleeding, bile leakage, pain at the insertion site and cosmetic dissatisfaction [2, 3]. As a result, PTBD is associated with a decrease in patient quality of life and pa-

tients overwhelmingly prefer internal biliary drainage when possible [4, 5].

Endoscopic ultrasound-guided hepaticoenterostomy (EUS-HE) is an effective method of endoscopic biliary drainage. The procedure is performed by EUS-guided puncture of a branch of the left intrahepatic duct followed by placement of endoprosthesis transmurally from the gastrointestinal lumen into the intrahepatic biliary tree. Previously described approaches have included transgastric, transduodenal, transjejunal, and transesophageal [6–9]. EUS-HE was initially utilized for palliation of malignant biliary obstruction, however, indications for

the procedure have expanded over time [10,11]. We recently published data on utilization of EUS-HE for benign disease in surgically altered anatomy [12].

Full understanding of the breadth of application is lacking, as are robust data on the experience needed to develop procedural proficiency. The current study aimed to describe utilization of EUS-HE at a large tertiary referral center along with procedural learning curve for biliary decompression using a non-foreshortening, self-expandable metal biliary stent.

Patients and methods

All adult patients (age ≥ 18 yr) evaluated for EUS-HE by a single endoscopist at a large tertiary referral center between February 2016 and June 2018 were identified. Endoscopy reports, medical charts, and relevant laboratory data were reviewed and recorded in accordance with Institutional Review Board protocol. The performing endoscopist had more than 20 years of therapeutic endoscopic experience in complex procedures and ERCP, but less than 2 years of EUS experience at the time of first EUS-HE.

Clinical and procedural data were collected, including etiology of biliary disease, indication for EUS-HE, endoscopic data (length and diameter of stent, anastomotic location, procedural findings), procedure-related adverse events (AEs), post-procedural symptoms, and clinical success, when available. Clinical success was defined as complete resolution of clinical symptoms with normalization of laboratory tests; this was monitored pragmatically without formal follow up protocol, given the retrospective nature of the study. Previously published data on a subset of patients with benign biliary disease and surgically altered anatomy are included in this analysis [12].

Prior to undergoing the procedure, all patients were informed of the risks, benefits of EUS-guided transmural biliary drainage, and alternatives; each patient provided written informed consent. General anesthesia and fluoroscopy were used in all cases. Pre-procedural antibiotics were not routinely administered. The technique of EUS-HE was performed as previously described [12]. Briefly, a standard therapeutic channel oblique linear echoendoscope (GF-UCT180, Olympus America, Center Valley, Pennsylvania, United States) was passed into the stomach, esophagus or jejunum to visualize the left lobe of the liver. Intrahepatic ducts of adequate caliber in hepatic segments II or III were identified with avoidance of intervening vessels as identified by Doppler. A 19G needle (Expect, Boston Scientific, Marlborough, Massachusetts, United States) preloaded with water soluble contrast was used to puncture through the liver into the selected duct and entry was confirmed by contrast injection. The needle was flushed with saline and a 0.025-inch, 450-cm-long hydrophilic-tipped guidewire (VisiGlide, Olympus) was passed antegrade into the biliary tree. The needle was withdrawn and the tract dilated prior to deploying a fully covered, non-foreshortening, self-expandable metal biliary stent (FCSEMS) (VIABIL Biliary Endoprosthesis, W.L. Gore & Associates, Flagstaff, Arizona, United States) under fluoroscopic and endoscopic visualization. A plastic biliary stent was routinely passed through the FCSEMS.

Technical success was defined as completion of EUS-guided biliary stent placement from hepatic duct into gastrointestinal tract. AEs were graded according to the American Society for Gastrointestinal Endoscopy lexicon [13]. Learning curve was evaluated by dividing procedures into quartiles based upon both chronological timeline and summative experience (first set of 15 procedures performed, second set of 15 procedures performed, etc.). Procedural success rate, procedural utilization, and procedural duration over time were compared.

Statistical analyses were performed using Stata version 15.1 (StataCorp, Texas, United States). All continuous variables are expressed as mean \pm standard deviation, and skewed variables are expressed as median and interquartile range. Categorical variables are expressed as proportions (%). Student's *t*-test was used to compare continuous measures, and two-tailed Fisher exact test was used to compare differences in proportions between groups. Because of the small number of events, we did not perform a logistic regression analysis. $P < .05$ was considered statistically significant. This was not a comparator study and thus neither sample size calculation nor power analysis was performed.

Results

During the study period, EUS-HE was attempted in 60 patients and the procedure was technically successful in 53 patients (88.3%). There were 35 females (median age, 66 years) and 35 patients had surgically altered anatomy; 23 Roux-en-Y (16 gastric bypass, 7 hepaticojejunostomy), three Billroth II gastrectomy, six Whipple, one right lobe hepatectomy, one gastrojejunostomy, and one other. Thirty-five patients were outpatients at the time of the procedure and 22 had previously failed traditional or device-assisted ERCP.

Indications for the procedure were malignant biliary obstruction (23), common bile duct stone (11), benign post-surgical stricture (12), benign stricture secondary to chronic pancreatitis (5), inflammatory stricture (2), primary sclerosis cholangitis (1), occluded biliary stent (1) and bile leak (4). In the 23 patients with malignant biliary obstruction, the primary tumor was pancreatic (11), cholangiocarcinoma (3), gastric cancer (1), metastatic colon cancer (2), metastatic lung cancer (1), metastatic breast cancer (2), ampullary carcinoma (1), hepatocellular carcinoma (1) and malignant stricture of undetermined primary (1). Patient demographic data are shown in ► **Table 1**.

Procedure technical success

Technical success was achieved in 53 patients; mean procedure time was 117.1 minutes (SD \pm 56.3). The approach was transgastric in 46 patients, transesophageal in three and transjejunal in four. In 51 cases the stent was deployed into a branch of left hepatic duct; the mean ductal diameter was 7.26 mm (SD \pm 3.63). In the remaining cases the stent was deployed into a biloma communicating with left hepatic duct (1) or an abscess communicating with left hepatic duct (1). The tract was dilated prior to stent deployment via tapered catheters and standard biliary balloon dilators (mean dilation diameter 4.5 mm) followed by stent placement. Stent diameters were 8 mm (41 pa-

► **Table 1** Patient demographic data.

	Successful EUS-HE (n = 53)	Unsuccessful EUS-HE (n = 7)	All Procedures (n = 60)
Median age (SD)	66 (± 16)	53.7 (± 18.7)	68 (± 15.2)
Number of females (%)	30 (55.6%)	5 (71.4%)	35 (81.4%)
Surgically altered anatomy (%)	30 (55.6%)	5 (71.4%)	35 (81.4%)
▪ Roux-en-Y Gastric Bypass	13	3	16
▪ Roux-en-Y Hepaticogastrostomy	7	0	7
▪ Billroth II	2	1	3
▪ Whipple	6	0	6
▪ Gastrojejunostomy	1	0	1
▪ Right Lobe Hepatectomy	1	0	1
▪ Unspecified	0	1	1
Outpatient cases (%)	29 (54.7%)	6 (85.7%)	35 (81.4%)
Prior unsuccessful ERCP (%)	21 (39.6%)	1 (14.3%)	22 (51.2%)
Reason for prior unsuccessful ERCP			
▪ Unable to reach papilla	5	0	5
▪ Unable to recognize papilla	1	0	1
▪ Unable to cannulate	5	0	5
▪ Unable to advance wire beyond stricture	8	1	9
▪ Embedded bile duct stent	1	0	1
▪ Unsuccessful drainage of liver abscess	1	0	1
Indication for EUS-HG			
▪ Biliary obstruction	50	6	56
▪ Treatment of bile leak	3	1	4
Etiology of bile duct obstruction			
Malignant obstruction	22 (41.5%)	1 (14.3%)	23 (53.5%)
▪ Pancreatic cancer	11	0	11
▪ Cholangiocarcinoma	2	1	3
▪ Gastric cancer	1	0	1
▪ Metastatic colon cancer	2	0	2
▪ Metastatic lung cancer	1	0	1
▪ Metastatic breast cancer	2	0	2
▪ Ampullary carcinoma	1	0	1
▪ Hepatocellular carcinoma (fibrolamellar subtype)	1	0	1
▪ Malignant stricture, unidentified primary	1	0	1
Benign obstruction	28 (52.8%)	5 (71.4%)	33 (76.7%)
▪ Common bile duct stone	9	2	11
▪ Chronic pancreatitis	4	1	5
▪ Occluded biliary stent	1	0	1
▪ Primary Sclerosis Cholangitis	1	0	1
▪ Inflammatory stricture	2	0	2

► **Table 1** (Continuation)

	Successful EUS-HE (n = 53)	Unsuccessful EUS-HE (n = 7)	All Procedures (n = 60)
▪ Benign post-surgical stricture	10	2	12
▪ Indeterminant stricture	1	0	1

EUS-HE, endoscopic ultrasound-guided hepaticoenterostomy; ERCP, endoscopic retrograde cholangiopancreatography

tients) or 10 mm (12 patients) with lengths of 40 mm (2 patients), 60 mm (9 patients), 80 mm (31 patients), and 100 mm (11 patients). Two patients required overlapping stents (40 mm and 100 mm in one and 60 mm and 60 mm in the other) as there was concern the initial stent was of insufficient length within the stomach to prevent migration into the peritoneum.

Fifteen procedures were performed outpatient. Inpatients were hospitalized for a mean of 2.28 days following the procedure (SD ± 4.1). Four patients experienced mild AEs (one with

post-procedural minor bleeding, two with post-procedural abdominal pain, and one with post-procedural cholangitis) requiring hospitalization for less than 3 nights. Four patients experienced moderate AEs (one with hematemesis secondary to a Mallory-Weis tear requiring repeat endoscopy, and three in whom sepsis develop after the procedure requiring IV antibiotics). There were four deaths during the follow-up period from underlying malignancy. Procedural and outcomes data are shown in ► **Table 2**.

► **Table 2** Procedural and outcomes data.

Stent Placement			
	Successful EUS-HE (n = 53)	Unsuccessful EUS-HE (n = 7)	All procedures (n = 60)
Mean procedure time, minutes (SD)	117.11 (± 56.31)	134 (± 102.2)	117.11 (± 56.04)
Mean number of EUS-guided needle puncture attempts (SD)	1.04 (± 0.19)	1.43 (± 0.79)	1.04 (± 0.19)
Proximal stent site			
▪ Stomach	46	7	53
▪ Jejunum	4	0	4
▪ Esophagus	3	0	3
Distal stent site			
▪ Left intrahepatic duct	51		
▪ Biloma communicating with left intrahepatic duct	1		
▪ Abscess communicating with left intrahepatic duct	1		
Mean size of left hepatic duct, mm (SD)	7.26 (± 3.63)	1.75 (± 2.58)	7.26 (± 3.61)
Mean dilation diameter prior to stent deployment (SD)	4.54 (± 1.03)	5 (± 1.41)	4.54 (± 1.03)
Cases requiring electrocautery	3	1	4
Stent diameters			
▪ 8 mm	41		
▪ 10 mm	12		
Stent lengths			
▪ 40 mm	2		
▪ 60 mm	9		
▪ 80 mm	31		
▪ 100 mm	11		
Median stent length, mm	80		
Median stent diameter, mm	8		
Cases requiring two overlapping stents	2		

► **Table 2** (Continuation)

ERCP and Antegrade Therapy			
	Successful EUS-HG (n = 53)	Unsuccessful EUS-HG (n = 7)	All Procedures (n = 60)
Cases with ERC performed through EUS-HG (%)	43 (81.1%)		
Stricture present on ERCP	29		
Type of stricture			
▪ Benign	15		
▪ Malignant	13		
▪ Indeterminant	1		
Mean number of procedures to resolution of condition (SD)	2.43 (± 1.01)		
Clinical Outcome			
	Successful EUS-HE (n = 53)	Unsuccessful EUS-HE (n = 7)	All Procedures (n = 60)
Inpatient cases (%)	24 (45.3%)	1 (14.3%)	25 (41.7%)
Outpatients admitted following procedure (%)	14 (26.4%)	5 (71.4%)	19 (31.7%)
Outpatients discharged to home (%)	15 (28.3%)	0 (0%)	15 (25%)
Mean reduction in bilirubin after procedure (SD)	2.35 (± 2.67)	-1.38 (± 3.69)	1.93 (± 2.58)
Patients with eventual stent removal (%)	27 (50.9%)		
Mean length of time stent left in place (SD)	97.67 (± 85.72)		
Patients with clinical success (%)	53 (100%)	4 (57.1%)	57 (95%)
Mean length of hospital stay after procedure (SD)	2.28 (± 4.12)	1.67 (± 2.42)	2.28 (± 4.12)
Patients with adverse events (%)	7 (13%)	2 (28.6%)	9 (15%)
Severity of adverse events			
▪ Mild	4	0	4
▪ Moderate	4	0	4
▪ Severe	0	3	3
Patients with unplanned surgical intervention (%)	3 (5.66%)	3 (42.9%)	6 (10%)
Deaths during follow up from underlying malignancy (%)	4 (7.55%)	1 (14.3%)	5 (8.3%)
EUS-HE, endoscopic ultrasound-guided hepaticoenterostomy			

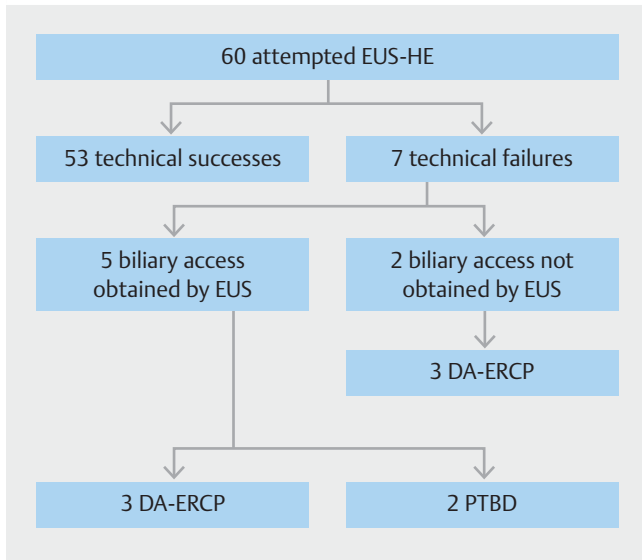
Procedure technical failure

The approach was transgastric in all seven patients and EUS-guided biliary target was a branch of the left hepatic duct in all cases; mean ductal diameter was 1.75 mm (SD ± 2.58). Mean procedure time was 110.9 minutes (SD ± 71.6). All patients underwent EUS-guided puncture of the gastric wall in an attempt to access the biliary tree; access was obtained in five patients. In the two patients without successful EUS-guided biliary access, this was due to decompressed ducts and the procedure was aborted in favor of ERCP. Four of the seven technical failures ultimately went on to clinical success (57.1%) as a result of cross-over to another mode of biliary decompression.

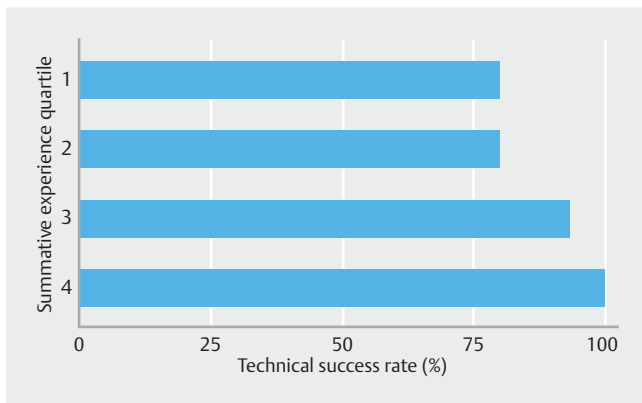
In one of the five patients with successful EUS-guided biliary access, once cholangiogram was obtained it was felt that the intrahepatic ducts were insufficiently dilated to allow success-

ful stent deployment and the patient underwent balloon enteroscopy-assisted ERCP. In a second patient with successful EUS-guided biliary access, a guidewire was passed successfully into the left hepatic duct, however, a dilator could not be advanced into the tract due to obstruction; this patient also subsequently underwent ERCP.

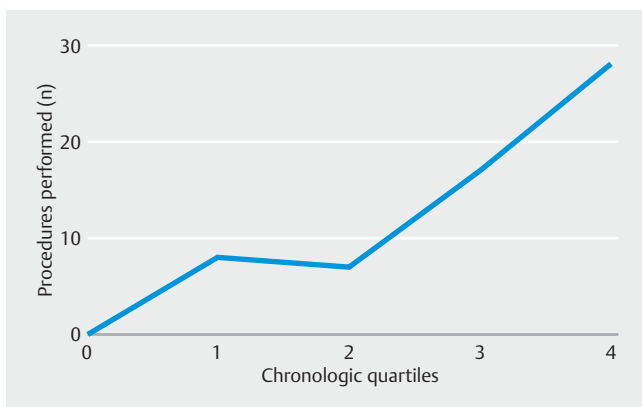
In one patient with metastatic cholangiocarcinoma, the distal end of the stent was successfully placed into the left hepatic duct, however, the proximal end was deployed into the peritoneum. A second stent was placed coaxially through the first stent to bridge the distance. During this process, however, the distal end of the first stent regressed into the lesser sac and could not be rescued; this was considered a severe AE. The procedure was aborted and ERC was performed for transpapillary drainage of the left intrahepatic system to prevent drainage



► **Fig. 1** Ultimate biliary drainage modality. EUS-HE, endoscopic ultrasound-directed hepaticocenterostomy; DA-ERCP, device-assisted endoscopic retrograde cholangiopancreatography; PTBD, percutaneous transhepatic biliary drainage.



► **Fig. 2** Percent technical success by summative experience quartile.



► **Fig. 3** Procedure utilization over time by chronologic quartile.

into the lesser sac. ERC was successful and following the procedure, the patient chose to be discharged to home hospice. This patient had surgically altered anatomy, necessitating ERC via single-balloon enteroscope; for this reason, EUS-HG was the first-choice therapy.

Two additional patients experienced severe AEs resulting in the procedure being technically unsuccessful. One patient developed hypotension during the procedure due to a non-ST segment elevation myocardial infarction, required a coronary stent, and subsequently underwent PTBD. Another patient with a RYGB had disruption of the jejunal limb during EUS, requiring emergent laparotomy followed by PTBD. The ultimate biliary decompression methods are shown in ► **Fig. 1**.

Learning curve

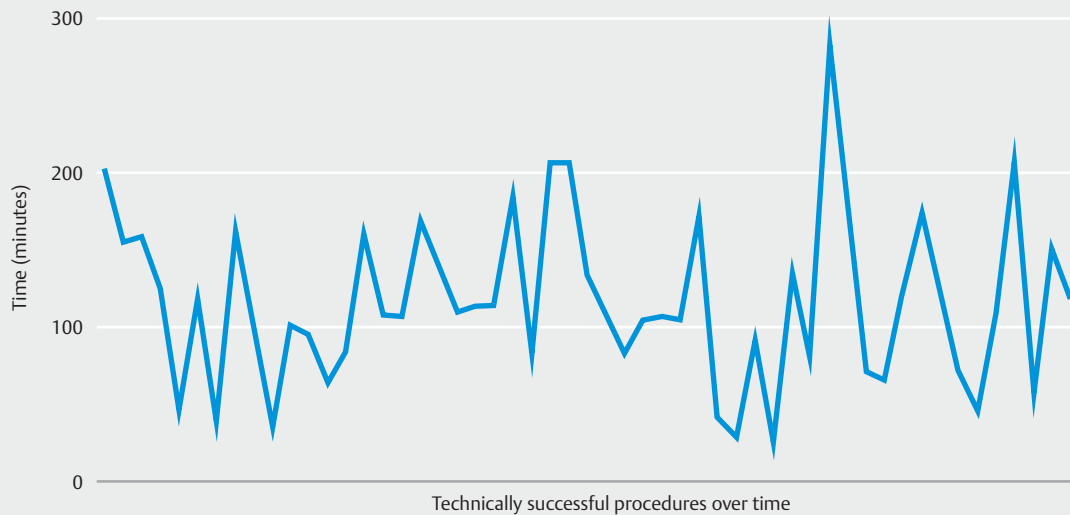
Success rates by summative experience quartile were 80%, 80%, 93.3% and 100% respectively (► **Fig. 2**). The last technical failure in the series occurred in the 39th patient, with a success rate up to that point of 84.2%. Beginning at patient number 40, the remaining cases had a success rate of 100%. Utilization of the procedure increased from eight cases in the first chronological quartile to 28 in the fourth (► **Fig. 3**). There was no significant reduction in procedure duration over time (► **Fig. 4**).

Discussion

EUS-guided hepaticogastrostomy was first described by Burmester et al. in 2003 as a series of four patients with malignant biliary obstruction after failing ERCP. This approach represented the first EUS-guided hepaticocentric anastomosis, however, other access points have been described. Along with EUS-guided choledochoduodenostomy and biliary rendezvous, EUS-HE is an important method for obtaining endoscopic biliary drainage in cases where ERCP has either failed or been deemed impossible.

The current study is the largest retrospective case series of EUS-HE and includes patients with gastric, jejunal and esophageal EUS-guided hepatic anastomosis using a commercially available FCSEMS with FDA approval for palliation of malignant biliary strictures. This stent has several notable characteristics that make EUS-HE possible: non-foreshortening design, presence of anti-migration fins and, as a result, lack of movement during deployment. Outside of the United States, specially designed stents for the purpose of EUS-HE are commercially available, such as Giobor stent (Taewoong Medical, Gyeonggi-do, South Korea) and Zeo Stent (ZEON Medical, Tokyo, Japan). Our study found a technical success rate for EUS-HE of 88.3%, which is comparable to prior studies using these dedicated stents [14, 15].

At our center, we noted a 100% technical success rate beginning after the first 40 patients. This is no doubt a product of accrued experience with the technique but is also secondary to improvements in patient selection. Two anatomical criteria should be closely evaluated to ensure technical success: left hepatic ductal diameter and distance from the gastrointestinal lumen to the duct. Technical success rates will be higher if the intrahepatic ducts are adequately dilated to sufficiently pro-



► **Fig. 4** Technically successful procedure duration over time (minutes). Earliest procedures on left, most recent procedures on right.

vide a target for initial needle puncture as well as allow stent placement. In our study, mean left hepatic duct diameter was 7.26 mm (SD \pm 3.63) in the cases with technical success and 1.75 mm (SD \pm 2.58) in technical failure. As FCSEMS are not available in the United States with lengths beyond 10 cm, the distance from the lumen to the targeted portion of the biliary tree should be no greater than this distance. In instances of insufficient stent length, a second stent can be placed coaxially within the first stent, however, with adequate planning, this can often be avoided. In the current study, three patients required a second stent to be placed and in one, the first stent became dislodged in the process. Over time, we began focusing EUS-HE on patients with sufficiently dilated ducts, within proximity to our initial puncture site and with a stable scope position; these changes in patient selection likely led to our increase in technical success.

Conclusion

In summary, for an experienced endoscopist, it appears that EUS-hepaticoenterostomy can be performed effectively and safely after experience with 40 cases. Several notable limitations of this study include experience of only one endoscopist and a heterogeneous patient population. The variable anatomy and etiology of biliary obstruction may affect procedural success. EUS-hepaticoenterostomy is a demanding intervention and, in less experienced hands, will likely have a longer learning curve. Future studies should include data from multiple centers and endoscopists and would ideally be performed in a randomized controlled fashion against other biliary drainage modalities, such as ERCP and percutaneous therapy.

Acknowledgement

Dr. James receives research and training support in part through a grant from the National Institutes of Health (T32DK007634).

Competing interests

Dr. Baron is a consultant and speaker for Boston Scientific, W.L. Gore, Cook Endoscopy, and Olympus America

References

- [1] Baron TH, Grimm IS, Swanstrom LL. Interventional approaches to gallbladder disease. *N Engl J Med* 2015; 373: 357–365
- [2] Carrasco CH, Zornoza J, Bechtel WJ. Malignant biliary obstruction: complications of percutaneous biliary drainage. *Radiology* 1984; 343–346
- [3] Winick AB, Waybill PN, Venbrux AC. Complications of percutaneous transhepatic biliary interventions. *Tech Vasc Interv Radiol* 2001; 4: 200–206
- [4] Sharaiha RZ, Kumta NA, Desai AP et al. Endoscopic ultrasound-guided biliary drainage versus percutaneous transhepatic biliary drainage: predictors of successful outcome in patients who fail endoscopic retrograde cholangiopancreatography. *Surg Endosc* 2016; 30: 5500–5505
- [5] Nam K, Kim DU, Lee TH et al. Patient perception and preference of EUS-guided drainage over percutaneous drainage when endoscopic transpapillary biliary drainage fails: An international multicenter survey. *Endosc Ultrasound* 2018; 7: 48–55
- [6] Burmester E, Niehaus J, Leineweber T et al. EUS-cholangio-drainage of the bile duct: report of 4 cases. *Gastrointest Endosc* 2003; 57: 246–251
- [7] Park SJ, Choi J-H, Park DH et al. Expanding indication: EUS-guided hepaticoduodenostomy for isolated right intrahepatic duct obstruction (with video). *Gastrointest Endosc* 2013; 78: 374–380

- [8] Park DH, Song T-J, Eum J et al. EUS-guided hepaticogastrostomy with a fully covered metal stent as the biliary diversion technique for an occluded biliary metal stent after a failed ERCP (with videos). *Gastrointest Endosc* 2010; 71: 413–419
- [9] Sharaiha RZ, Kalloo AN, Khashab MA. EUS-guided hepatoesophagostomy for transesophageal biliary drainage (with video). *Gastrointest Endosc* 2012; 76: 227–228
- [10] Iwashita T, Nakai Y, Hara K et al. Endoscopic ultrasound-guided antegrade treatment of bile duct stone in patients with surgically altered anatomy: A multicenter retrospective cohort study. *J Hepatobiliary Pancreat Sci* 2016; 23: 227–233
- [11] Ogura T, Kitano M, Takenaka M et al. Multicenter prospective evaluation study of endoscopic ultrasound-guided hepaticogastrostomy combined with antegrade stenting (with video). *Dig Endosc* 2018; 30: 252–259
- [12] James TW, Fan YC, Baron TH. EUS-guided hepaticoenterostomy as a portal to allow definitive antegrade treatment of benign biliary diseases in patients with surgically altered anatomy. *Gastrointest Endosc* 2018; 88: 547–554
- [13] Cotton PB, Eisen GM, Aabakken L et al. A lexicon for endoscopic adverse events: report of an ASGE workshop. *Gastrointest Endosc* 2010; 71: 446–454
- [14] Imai H, Takenaka M, Omoto S et al. Utility of endoscopic ultrasound-guided hepaticogastrostomy with antegrade stenting for malignant biliary obstruction after failed endoscopic retrograde cholangiopancreatography. *Oncol* 2017; 93: 69–75
- [15] De Cassan C, Bories E, Pesenti C et al. Use of partially covered and uncovered metallic prosthesis for endoscopic ultrasound-guided hepaticogastrostomy: Results of a retrospective monocentric study. *Endosc Ultrasound* 2017; 6: 329–335