Published online: 2019-04-02

Endoscopic ultrasound-guided biliary drainage in a novel radiofrequency ablation-based swine biliary dilatation model

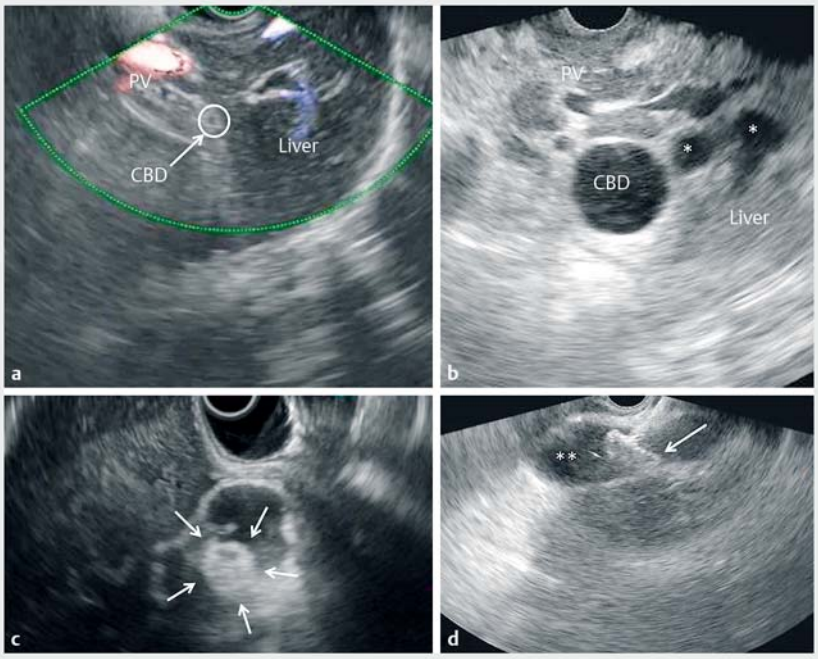

▶ **Fig. 1** Endoscopic ultrasound images in a minipig model showing: **a** the normal common bile duct (CBD) and portal vein (PV) at the hepatic hilum viewed from the stomach before radiofrequency ablation (RFA) of the distal CBD; **b** the distal CBD viewed from the stomach following RFA with evidence of dilatation of the CBD and intrahepatic biliary ducts (*); **c** the RFA-induced hyperechoic lesion (arrows) in the distal CBD seen from the bulb; **d** the distal flange of the lumen-apposing metal stent, seen from the gastric antrum and correctly deployed in the distended gallbladder (**).

▶ **Fig. 2** Endoscopic view showing the proximal flange of the lumen-apposing metal stent correctly deployed in the gastric antrum.

Endoscopic ultrasound (EUS)-guided drainage procedures are becoming increasingly widespread in clinical practice, even though they are technically challenging and require a substantial learning curve. In vivo swine biliary dilatation models for training have been described; however, they provide erratic biliary dilatation and can also be technically cumbersome [1–5]. We describe EUS-guided gallbladder drainage with a lumen-apposing metal stent (LAMS) in a novel swine biliary dilatation model.

A 30-kg minipig underwent endoscopic retrograde cholangiography and temperature-controlled endobiliary radiofrequency ablation (EB-RFA) of the distal common bile duct (CBD) with a dedicated RFA system (ELRA, STARmed) (▶ **Video 1**). The ablation consisted of 10 W of power delivered via an endobiliary catheter-electrode, with a temperature sensor at a target temperature of 80 °C, for two rounds of 90 seconds. After 11 days, the pig was re-examined with a linear EUS scope, which revealed dilatation of both the intrahepatic and extrahepatic biliary ducts, including the gallbladder. At the distal third of the CBD, an RFA-induced hyperechoic lesion was detected (▶ **Fig. 1**).

The distended gallbladder was accessed from the gastric antrum with a 19G needle (Expect, Boston Scientific). A 0.025-inch guidewire (VisiGlide 2, Olympus) was then inserted through the needle and coiled into the gallbladder. After a cholecystogastric fistula had been created using a wire-guided needle knife (MicroKnife, Boston Scientific), the tract was dilated with a 6-mm balloon (Hurricane, Boston Scientific). Finally, a 10 × 20-mm LAMS (Spaxus, Taewoong) was placed under combined EUS, fluoroscopic, and endoscopic guidance (▶ **Fig. 2**).

Temperature-controlled EB-RFA of the distal CBD proved to be a straightforward, effective, and novel technique to create a biliary stricture with subsequent massive upstream biliary dilatation. EUS-guided gallbladder drainage with a LAMS was feasible in this model, which is theoretically suitable also for other EUS-guided biliary interventions. Furthermore, the swine model provides excellent haptic feedback and suitable levels of realism in comparison to procedures undertaken in humans.

Endoscopy_UCTN_Code_TTT_1AU_2AB

Competing interests

None

This document was downloaded for personal use only. Unauthorized distribution is strictly prohibited.

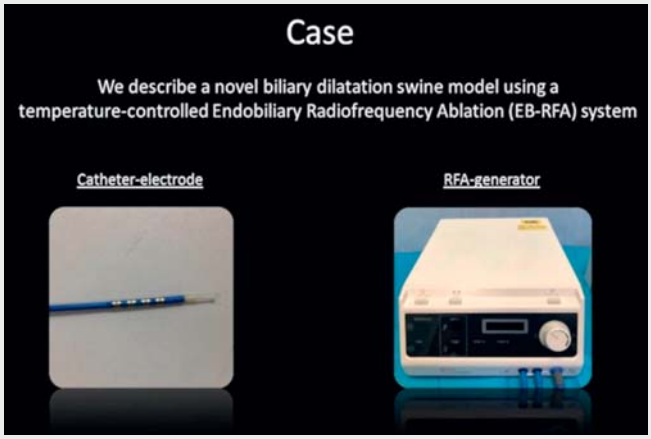

Video 1 Video showing endoscopic ultrasound-guided biliary drainage with a lumen-apposing metal stent in a novel swine biliary dilatation model obtained with a temperature-controlled endobiliary radiofrequency ablation system.

The authors

Dario Ligresti[1], Stefano Baraldo[2], Radhika Chavan[3], Margaret Geri Keane[4], Yu-Ting Kuo[5], Shaimaa Saleem[6], Dong-Wan Seo[7]

1 Endoscopy Service, Department of Diagnostic and Therapeutic Services, IRCCS-ISMETT, Palermo, Italy.
2 Department of Endoscopy, Barretos Cancer Hospital, Barretos, Brazil
3 Department of Medical Gastroenterology, Asian Institute of Gastroenterology, Hyderabad, India
4 Institute of Hepatology, Kings College Hospital, London, UK
5 Division of Endoscopy, Department of Integrated Diagnostics and Therapeutics, National Taiwan University Hospital, Taipei, Taiwan
6 Gastroenterology and Endoscopy Department, Ahmed Maher Teaching Hospital, Cairo, Egypt
7 Department of Gastroenterology, Asan Medical Center, University of Ulsan College of Medicine, Seoul, South Korea

Corresponding author

Dong-Wan Seo, MD, PhD
Department of Gastroenterology, Asan Medical Center, University of Ulsan College of Medicine, 88 Olympic-ro 43-gil, Songpa-gu, Seoul 05505, South Korea
Fax: +82-2-4760824
dwseoamc@amc.seoul.kr

References

[1] Lee TH, Choi JH, Lee SS et al. A pilot proof-of-concept study of a modified device for one-step endoscopic ultrasound-guided biliary drainage in a new experimental biliary dilatation animal model. World J Gastroenterol 2014; 20: 5859 – 5866
[2] Alcaide N, Lorenzo-Pelayo N, Ruiz-Zorrilla R et al. Endoscopic porcine model of biliary obstruction using over-the-scope clips: feasibility and applicability to training in EUS-guided drainage procedures. Gastrointest Endosc 2013; 77: AB294 – AB295
[3] Minaga K, Kitano M, Itonaga M et al. Endoscopic ultrasound-guided biliary drainage using a newly designed metal stent with a thin delivery system: a preclinical study in phantom and porcine models. J Med Ultrason 2018; 45: 391 – 397
[4] Park JS, Jeong S, Kim JM et al. Development of a swine benign biliary stricture model using endoscopic biliary radiofrequency ablation. J Korean Med Sci 2016; 31: 1438 – 1444
[5] Rumalla A, Petersen BT, Baron TH et al. Development of a swine model for benign stenosis of the bile duct by endoscopic application of intraluminal thermal injury. Gastrointest Endosc 2003; 57: 73 – 77

Bibliography
DOI https://doi.org/10.1055/a-0867-9348
Published online: 1.4.2019
Endoscopy 2019; 51: E162–E163
© Georg Thieme Verlag KG
Stuttgart · New York
ISSN 0013-726X

ENDOSCOPY E-VIDEOS
https://eref.thieme.de/e-videos

Endoscopy E-Videos is a free access online section, reporting on interesting cases and new techniques in gastroenterological endoscopy. All papers include a high quality video and all contributions are freely accessible online.

This section has its own submission website at https://mc.manuscriptcentral.com/e-videos

This document was downloaded for personal use only. Unauthorized distribution is strictly prohibited.