

# Endoscope-assisted deliverance of a snare into the deep colon for endoscopic submucosal dissection ▶

OPEN  
ACCESS



## Author

Qiang Zhang

## Institution

Guangdong Provincial Key Laboratory of Gastroenterology, Department of Gastroenterology, Nanfang Hospital, Southern Medical University, Guangzhou, China

submitted 14.6.2018

accepted after revision 17.10.2018

## Bibliography

DOI <https://doi.org/10.1055/a-0859-7204> |

Endoscopy International Open 2019; 07: E459–E461

© Georg Thieme Verlag KG Stuttgart · New York  
ISSN 2364-3722

## Corresponding author

Qiang Zhang, Guangdong Provincial Key Laboratory of Gastroenterology, Department of Gastroenterology, Nanfang Hospital, Southern Medical University, Tonghe Road 1838, Guangzhou, China 510515

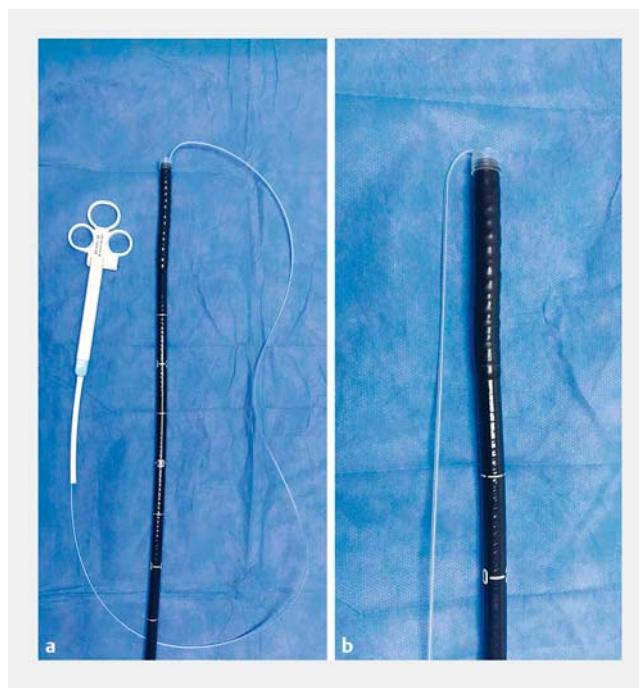Fax: +86-20-87280770

4024313@qq.com

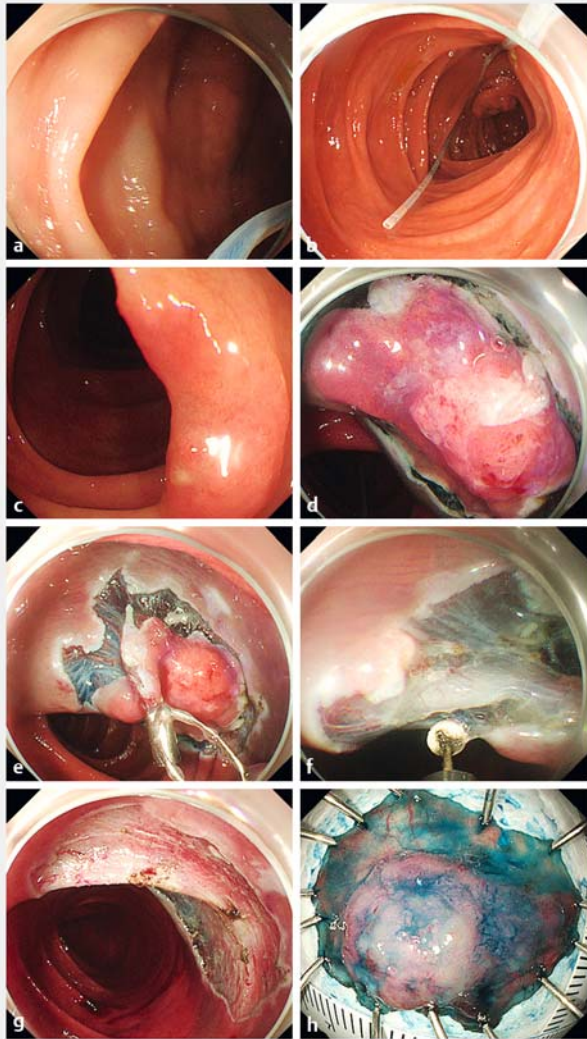
The endoscopic snare and endoclips are available at endoscopy centers, and the snare combined with endoclips reportedly can be used for endoscopic submucosal dissection (ESD) of colorectal lesions [1, 2]. Use of the snared combined with endoclips is not dependent upon lesion position, the mucosal flap can be pushed or pulled to expose the submucosa, and traction strength can be adjusted in real time. However, this method can be used in the deep colon only with the aid of a special balloon catheter with an external diameter of 16.2 mm [2].

We explored use of a snare combined with endoclips for assisting in ESD (SC-ESD) [3, 4]. SC-ESD has been successfully applied in resection of upper gastrointestinal mucosal lesions. Mucosal external traction and internal traction are keys to the technique. For colorectal ESD, especially deep colonic ESD, the mechanism behind delivering the snare into the colon together with the endoscope should be addressed. Here, we describe two cases – laterally spreading tumors (LST) in the transverse and ascending colon, respectively – that illustrate use of the technique (▶ **Fig. 1**, ▶ **Fig. 2**, and ▶ **Fig. 3** and ▶ **Video 1**).

We used a snare with an outer diameter of 1.8 mm (SD-221L-25, OLYMPUS, Japan) that was both soft and thin, which made it possible to inversely insert it into the endoscopic working channel (▶ **Fig. 1**) and then deliver it to the colon together with the endoscope (▶ **Fig. 2a**, ▶ **Fig. 3a**). After the snare entered the colon and crossed the lesion, an endoclip was used to push the snare out of the endoscopic working channel to form a U-shaped loop in the front part of the snare (▶ **Fig. 2b**, ▶ **Fig. 3b**), which was placed at the distal end of the lesion. The U-shaped loop prevented the snare from slipping out of the colon.



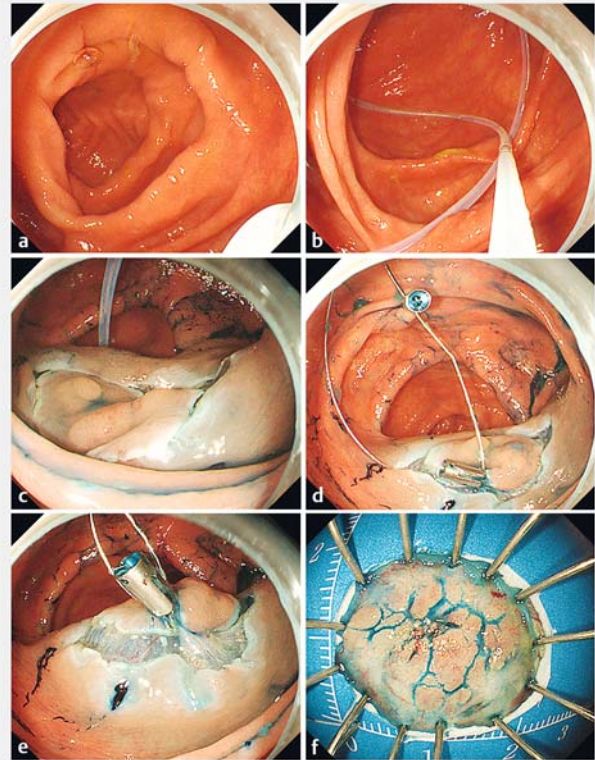
▶ **Fig. 1** An inversely inserted snare in the endoscopic working channel. **a** A snare was inserted from the head end of the endoscope into the working channel. The length of insertion was approximately 30 mm. **b** The snare was soft and thin and could be efficiently attached to the endoscope.



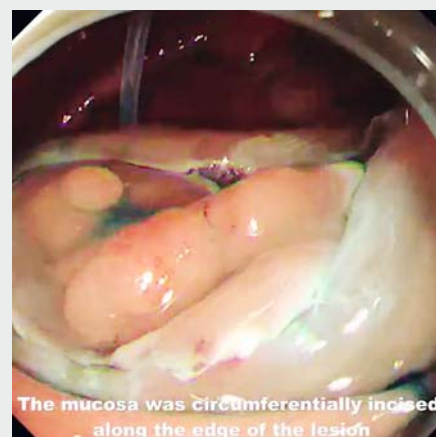► **Fig. 2** A laterally spreading tumor at the transverse colon was resected with SC-ESD. Mucosal external traction was used in SC-ESD. **a** A snare was delivered into the deep colon together with the endoscope. **b** The snare was pushed out of the endoscopic working channel to form a U-shaped loop. **c, d** The mucosa was circumferentially incised along the edge of the lesion. **e, f** The snare was fixed with the endoclips to the incised mucosal flap at the anal side, and the flap was then dissected. **g** Wound. **h** Specimen.

Next, the mucosa was circumferentially incised along the edge of the lesion (► **Fig. 2d**, ► **Fig. 3c**). After the snare was pulled back near the mucosal flap, it was fixed with endoclips (HXROCC-D-26-195-C, MICRO-TECH, China) to the flap at the anal side. The submucosa thus was exposed by pulling the snare and then dissected (► **Fig. 2e**, ► **Fig. 2f**), which produced external traction.

For the LST in the ascending colon, the snare was fixed with endoclips to the mucosal flap at the anal side (one fixed site) and then fixed to the normal colonic mucosa opposite the mucosal flap (another fixed site) (► **Fig. 3d**). Next, the snare was moderately tightened to achieve mutual pulling of the two fixed sites, exposing the submucosa (► **Fig. 3e**), which resulted



► **Fig. 3** A laterally spreading tumor at the ascending colon was resected with SC-ESD. Mucosal internal traction was used in SC-ESD. **a** A snare was delivered into the deep colon together with the endoscope. **b** The snare was pushed out of the endoscopic working channel to form a U-shaped loop. **c** The mucosa was circumferentially incised along the edge of the lesion. **d** The snare was fixed to the incised mucosal flap at the anal side (one fixed site) and was fixed to the normal colonic mucosa opposite the flap (another fixed site). **e** The snare was moderately tightened to achieve mutual pulling of the two fixed sites and fully expose the submucosa. **f** Specimen.



► **Video 1** A laterally spreading tumor at the ascending colon resected with the aid of mucosal internal traction.

in internal traction. In practice, the snare could be restored to its original straight shape even if it was bent during delivery, and mucosal external and internal traction both could be achieved effectively. The two LSTs in the deep colon were completely resected using SC-ESD (► **Fig. 2g**, ► **Fig. 2h** and ► **Fig. 3f**).

### Competing interests

---

None

### References

---

- [1] Yoshida N, Doyama H, Ota R et al. The clip-and-snare method with a pre-looping technique during gastric endoscopic submucosal dissection. *Endoscopy* 2014; 46: E611–E612
- [2] Yamada S, Doyama H, Ota R et al. Impact of the clip and snare method using the prelooping technique for colorectal endoscopic submucosal dissection. *Endoscopy* 2016; 48: 281–285
- [3] Zhang Q, Wang Z. Snare with endoclips to assist in endoscopic submucosal dissection with mucosal internal traction for a gastric neoplasia involving pyloric ring. *Dig Endosc* 2018; 30: 539–540
- [4] Zhang Q, Yao X, Wang Z. A modified method of endoclip-and-snare to assist in endoscopic submucosal dissection with mucosal traction in the upper GI tract. *VideoGIE* 2018; 3: 137–141