

# Endovascular Treatment of Intracranial Atherosclerotic Stenosis

## Endovaskuläre Behandlung intrakranieller arteriosklerotischer Stenosen

### Authors

Hannes Nordmeyer<sup>1,2</sup>, René Chapot<sup>3</sup>, Patrick Haage<sup>4</sup>

### Affiliations

- 1 Department of Interventional Radiology and Neuroradiology, Neurocenter Solingen, radprax St. Lukas Hospital, Solingen, Germany
- 2 School of Medicine, Department of Health, Witten/Herdecke University, Witten, Germany
- 3 Diagnostic and Interventional Radiology and Neuroradiology, Alfried-Krupp-Hospital, Essen, Germany
- 4 Department of diagnostic and interventional Radiology, Helios University Hospital, Wuppertal, Germany

### Key words

intracranial stenosis, atherosclerosis, cerebral ischemia, endovascular treatment, stent, angioplasty

received 11.09.2018

accepted 25.01.2019

### Bibliography

DOI <https://doi.org/10.1055/a-0855-4298>

Published online: 4.4.2019

Fortschr Röntgenstr 2019; 191: 643–652

© Georg Thieme Verlag KG, Stuttgart · New York

ISSN 1438-9029

### Correspondence

Dr. Hannes Nordmeyer

Interventional Radiology and Neuroradiology,  
radprax St. Lukas Klinik, Schwanenstraße 136,  
42697 Solingen, Germany

Tel.: ++49/212/70 51 86 51

nordmeyer@gmx.com

### ABSTRACT

**Background** Intracranial atherosclerotic stenosis (ICAS) causes 5 – 10% of all ischemic strokes in the European population. Indication for endovascular treatment is a special challenge and the selection of material as well as interventional techniques essentially differs from the treatment of extracranial stenoses. According to recent studies patient selection became evidence based; however the method should not be abandoned. New technical approaches can contribute to avoid complications.

**Method** We performed a review of the literature with regard to conservative as well as endovascular treatment of ICAS. Different technical approaches are discussed and strategies

to avoid complications are stressed. Based on the treatment indication, the positions of the authorities and the professional societies are taken into account.

**Results and Conclusion** A single self-expanding stent is approved for the treatment of ICAS. Balloon mounted and other self-expanding Stents are available for off-label use. Anatomical conditions and features of the stenosis determine the choice of material. Distal wire perforations causing intracranial bleedings may occur during exchange manoeuvres and constitute one of the technical complications in the treatment of ICAS. In contrast, there is hardly any efficient way to eliminate the risk of ischemia in the territory of perforating arteries arising from the intracranial posterior circulation and the middle cerebral artery. The results of the randomized prospective trials strengthen the conservative treatment of ICAS. Endovascular treatment should not be withheld from patients with either hemodynamic stenosis, recurrent ischemic events under best medical treatment in the territory of the stenosed vessel or acute occlusions of a stenosis.

### Key Points:

- Medical therapy and risk reduction constitute the primary treatment of intracranial stenosis.
- Recurrence under best medical treatment and acute occlusions of intracranial stenosis are indications for endovascular treatment.
- Acute occlusions due to intracranial stenosis often are treated by stenting and angioplasty after mechanical thrombectomy.
- Exchange manoeuvres with distal wire perforation can cause intracranial hemorrhage.
- Basal ganglia and brain stem ischemia constitute a specific risk in treatment of vessel segments bearing perforators.

### Citation Format

- Nordmeyer H, Chapot R, Haage P. Endovascular Treatment of Intracranial Atherosclerotic Stenosis. Fortschr Röntgenstr 2019; 191: 643–652

### ZUSAMMENFASSUNG

**Hintergrund** Intrakranielle arteriosklerotische Stenosen (ICAS) sind in der europäischen Bevölkerung ursächlich für 5 – 10% der zerebralen Ischämien. Die Indikationsstellung zur endovaskulären Therapie stellt eine besondere Herausforderung dar und die Wahl des Materials sowie die Interventionen

technik unterscheiden sich wesentlich von der Behandlung extrakranieller Stenosen. Die Behandlungsindikation ist durch die aktuelle Studienlage evidenzbasiert geworden, sollte jedoch nicht zu einer Abkehr von der Methode führen. Neue technische Konzepte können zur Vermeidung technischer Komplikationen beitragen.

**Methode** Die Arbeit widmet sich unter Würdigung der aktuellen Literatur der konservativen und interventionellen Therapie intrakranieller Stenosen. Die technischen Ansätze der endovaskulären Behandlung werden detailliert beschrieben und es werden insbesondere Strategien zur Vermeidung typischer Komplikationen herausgearbeitet. Anhand der Indikationsstellung werden die Standpunkte der öffentlichen Instanzen und der Fachgesellschaften erörtert.

**Ergebnisse und Schlussfolgerung** Für die endovaskuläre Behandlung steht als einzig zugelassenes Produkt ein selbstexpandierender Stent zur Verfügung. Off-Label kommen Ballon-

expandierbare und verschiedene selbstexpandierende Stents zur Verfügung, deren Wahl von den anatomischen Gegebenheiten und den Charakteristika der Stenose abhängt. Blutungen durch distale Drahtperforationen sind technische Komplikationen, die vor allem bei der Durchführung von Wechselmanövern auftreten. Komplikationen wie Perforator-Infarkte sind demgegenüber kaum vermeidbar und stehen vor allem bei Stenosen der hinteren Zirkulation sowie des M1-Segments der A. cerebri im Zusammenhang mit der Erkrankung. Das Morbiditäts- und Mortalitätsrisiko ist in der hinteren Zirkulation höher. Die Ergebnisse der großen randomisierten prospektiven Studien haben die Rolle der konservativen Therapie intrakranieller Stenosen gestärkt. Patienten mit hämodynamisch wirksamen, unter Blutdruckschwankungen symptomatischen Stenosen oder rezidivierenden Ischämien unter optimierter medikamentöser Therapie und solchen mit akuten Verschlüssen sollte die Stent-PTA aber nicht vorenthalten werden.

## Introduction

Stroke is one of the most common causes of disability and need for long-term care and is the second most common cause of death worldwide [1]. Intracranial atherosclerotic stenosis (ICAS) causes 5–10% of all ischemic strokes and transient ischemic attacks (TIA) in the European population. At up to 40–50%, the rate of symptomatic ICAS is significantly higher in the Asian population and is probably the most common cause of stroke worldwide [2, 3].

The infarct pattern of symptomatic intracranial stenoses is characterized by a particular heterogeneity, since they can lead to both arterio-arterial embolic and hemodynamic as well as perforator ischemia [4, 5]. The latter occur most frequently in stenoses of the M1 segment, the basilar artery and the V4 segment, with ICAS of the anterior vs. posterior circulation leading more frequently to arterio-arterial embolisms (51.8% vs. 34.0%) and less frequently to local branch occlusions (12.3% vs. 40.4%) [6].

The 2-year recurrence risk of an ischemic infarction is 14–19% for ICAS, with most events occurring within the first year [7–9]. In contrast, asymptomatic ICAS with drug therapy is reported to have a significantly lower annual stroke risk of <2% [7].

Conservative (medicinal and lifestyle change) and endovascular therapy procedures as well as endovascular therapeutic approaches [percutaneous balloon angioplasty (PTA) or stent-assisted angioplasty (PTAS)] are available for the treatment of ICAS. In the randomized COSS study in arteriosclerotically-induced intracranial stenoses with hemodynamic relevance, the creation of extra-intracranial bypasses, as successfully established in MoyaMoya disease and in certain disease stages even without alternatives, showed no advantage over drug-conservative treatment in the randomized COSS study [10].

The prospective, non-randomized SSYLVA study [11] investigated the use of a balloon-mounted stent (NEUROLINK® Guidant Corporation, Santa Clara, CA) in patients with intracranial stenoses of the anterior, intracranial and extracranial stenoses of the posterior circulation. The risk of stroke after stent PTA was 13.9%

in the first year (6.6% in the first 30 days and 7.3% after 30 days in the first year). Initial approval studies for PTAS procedures with the self-expanding Wingspan stent (StrykerNeurovascular, Fremont, CA, USA) [12] as well as additional studies [13–15] have shown promising results which could not be confirmed in the controversial multicenter and randomized SAMMPRIS study [16], which was discontinued prematurely because the primary endpoint, stroke after 30 days, was 14.7% in the intervention arm and significantly higher than 5.8% in the conservative arm. Likewise, the multicenter VISSIT study [17], in which the Pharos Vitesse stent (Codman & Shurtleff, Raynham, Massachusetts, USA) had been used, was prematurely terminated due to a significantly higher event rate in the interventional therapy arm (36.2% vs. 15.1% in the conservative arm). The WEAVE study presented at the 2018 International Stroke Conference demonstrated positive results [18]. Prospective, non-randomized patients were included for on-label treatment using the Wingspan stent system; these patients suffered two strokes or more in the region of the stenosed vessel at least seven days previously. The events “stroke or death” occurred in only 2.4% within the first 72 hours, well below the 4% complication rate set by the FDA. The authors attribute these results, which for the first time were positive in favor of endovascular treatment, to the strict inclusion criteria and the greater experience of the participating centers compared to other studies; criticisms include the lack of data regarding long-term follow-up, thus these study results have not yet led to a change in the indication for utilization.

## Treatment Options

### Conservative therapy

Lifestyle changes (weight loss, exercise and smoking cessation) and drug therapy are used for secondary prophylactic conservative treatment of ICAS.

For a long time oral coagulants were an important pillar of therapy of ICAS [19], but in 2005 their significance decreased as a result of the large randomized WASID study [20]. Patients in the high-dose acetylsalicylic acid (ASA) group had significantly less severe intracranial hemorrhage and mortality than the Warfarin group, while no significant difference was seen in the combined primary endpoint (ischemic stroke, any intracranial hemorrhage, and vascular death).

Aspirin (acetylsalicylic acid – ASA) continues to be the most prevalent substance in stroke therapy. However, annual ischemic events of 4 – 19% are reported with ICAS aspirin monotherapy [7, 16, 21]. Doubling inhibition of thrombocyte function is therefore particularly important in the early phase. As a result of the CARESS study of symptomatic carotid stenoses [22] as well as large cardiological studies [23, 24], the randomized Chinese CHANCE study [25] of more than 5000 stroke patients (with mixed etiology) demonstrated that the primary endpoint (any stroke within 90 days) in the group of double thrombocyte inhibition occurred significantly less frequently at the same rate of severe bleeding using the combined therapy of ASA/clopidogrel compared to the ASA monotherapy group. Likewise in the SAMMPRIS study, doubled platelet inhibition with ASA and clopidogrel was used in the conservative arm in the early phase (90 days) and contributed to a lower stroke recurrence rate of 12.2% (compared to 18% in WASID). In SAMMPRIS, much stricter risk factor management with lifestyle modification and cholesterol lowering was also applied with high-dose statins.

ASA or clopidogrel resistance is important in the choice of anti-platelet agents, even though there is no reliable evidence. In the CHANCE study, a higher prevalence of clopidogrel resistance was found in the Asian population and in one subgroup analysis this was highly relevant [25]. Clopidogrel is an inactive pro drug that is converted into its active metabolite via CYP2C19. In CHANCE 59% of 2933 patients were carriers of a loss-of-function allele and in the 90-day follow-up no additional benefit of doubled thrombocyte function inhibitor was observed in these patients. In the group of non-carriers of this allele, a significant reduction of new infarcts to 6.7% under doubled thrombocyte function inhibitor was observed (compared to 12.4% under ASA alone).

In the event of clopidogrel resistance, ticagrelor can be used as an alternate preparation since it also acts on the ADP receptor P2Y<sub>12</sub>, but does not have to be metabolized and therefore does not carry the risk of a non-response [26]. Data from the SOCRATES study did not show the superiority of ticagrelor over aspirin (ischemic stroke using ticagrelor 5.8% vs. 6.7% with aspirin) [27]. However, in the subgroup of patients with atherosclerotic, unspecified ipsilateral stenosis, ticagrelor significantly reduced the risk of recurrence, myocardial infarction and death (6.7% for ticagrelor vs. 9.6% for aspirin) [28]. The significance for ICAS remains unclear, but the results underline the importance of the stroke mechanism for the choice of secondary prophylaxis. The shorter duration of effectiveness is problematic as well as the requirement of twice daily intake with the risk of a gap should a dose be already forgotten.

Prasugrel may also be used in combination with aspirin if there is clopidogrel resistance; this has been tested in clinical practice in some centers prior to planned endovascular surgery. However,

the risk-benefit balance of working with a heterogeneous patient population does not suggest the primary use of the aspirin/prasugrel combination in neurointerventions, so it should also be considered a reserve drug due to the potentially higher bleeding rate [29].

Cilostazole, an anti-inflammatory, anti-atheromatic and vasodilatory phosphodiesterase-3 inhibitor, is currently only used for ICAS in Asia. The substance was tested on Korean patients in the TOSS I and II trials and showed a lower rate of stenosis progression and a higher rate of stenosis regression [30, 31].

Also, the effects of intensified drug therapy (LDL target  $\leq 70$  mg/dl, HbA1c target  $\leq 6.5\%$ , systolic blood pressure target  $\leq 140$  mmHg) on ICAS used in SAMMPRIS but not in WASID have also been reported in a smaller study of 50 patients by Leung et al. [32]. In 49% of patients, intracranial stenosis was slightly decreased with this therapy, 43% remained stable and only 8% were progressive.

In summary, conservative treatment of ICAS consists in the adjustment of risk factors through lifestyle-modifying measures as well as in plaque-stabilizing therapy with statins and the reduction of arterio-arterial embolic ischemia by administration of anti-platelet agents, thus double anti-aggregation should be sought in the early phase of the stroke.

## Endovascular Treatment

Cerebrovascular anatomy presents a particular challenge due to the highly angulated sections of the vessels, especially in elderly patients with increased elongations and wall calcifications. The formation of extracranial elongations of the carotids and the vertebral arteries varies greatly between individuals; the siphon section of the internal carotid artery and the atlas loop of the vertebral artery make considerable demands on the material even in younger patients. The use of rigid balloons and balloon-mounted stents from cardiology is therefore subject to some limitations in neurovascular procedures. In addition, the lamina muscularis of the cerebral arteries is thinner than that of the coronary arteries. Consequently these vessels are not only more difficult to reach, but are also more vulnerable. Finally, it is important to take into account the perforator arteries emanating from certain sections of the intracranial arteries and whose iatrogenic occlusion by PTA or PTAS represents a specific risk in stenosis treatment.

The selection of PTA balloons and stents is influenced by anatomical criteria of both the access route and the target vessel. General recommendations cannot be made here because, for example, case series of non-randomized studies show no correlation between complication rates and stent type [33]. However, it is generally less risky to use a balloon-mounted stent in the horizontal and straight petrous segment than in the strongly angulated siphon section of the internal carotid artery.

Access is usually transfemoral, in rare cases of occlusion of the iliac arteries or abdominal aorta a transbrachial approach can be used. The procedure for using balloon-mounted and self-expanding stents is fundamentally different.

## Balloon and Stent Angioplasty Technique

Single PTA of intracranial stenoses offers the advantage of a defensive, potentially incremental approach and allows imaging control through all modalities, as no artifacts from stent material appear in CT angiography (CTA) or MR angiography (MRA). In addition, using a single balloon usually avoids an exchange maneuver. Smaller case series [34] and personal experience show that primary stent implantation can be avoided, at least in some patients with non-calcified stenoses.

### Balloon-mounted and self-expanding stents

Selection of the balloon and stent depends on the length and degree of the stenosis. A balloon-mounted stent can be adapted very accurately to the length of the stenosed vascular section, while with self-expanding stents it should be noted that the radial force at the stent ends is less than in the center of some models, so that an overlap of the section to be treated may be necessary. At the same time, the stent should be as short as possible in order to cover as few branches as possible in the healthy vascular section. Predilation of the stenosis should be performed with an undersized balloon to avoid vascular injuries such as dissections and ruptures. The aim here is not the restoration of the original lumen, but the restoration of sufficient blood flow.

### Balloon-mounted stents

When using balloon-mounted stents (► Fig. 3), a micro-wire is first passed through the intracranial stenosis. Difficult anatomical conditions may require probing using a micro-catheter, which is then removed using a guide wire. The micro-wire should be placed distal to the stenosis so that the stiffer proximal section provides sufficient support to advance the rigid balloon-mounted stent. If the soft tip of the wire is left only directly distal to the stenosis out of caution, e. g. for anatomical reasons, a backward movement of the wire tip usually occurs at the latest at the siphon passage of the stent, the position distal to the stenosis is lost and new probing is necessary.

Once the balloon-mounted stent has been correctly placed over the stenosis, it is preferably expanded to the desired diameter using a manometer. When the balloon is retracted, the tip of the wire will usually make a sudden distal movement, as the extension of the system in the proximal curves will advance the wire. In order to avoid distal perforation, the pressure on the wire must first be relieved so that the balloon can then be removed without jerky wire movements while maintaining a traction/thrust equilibrium.

### Self-expanding stents

In contrast, the implantation of self-expanding stents (► Fig. 1) requires at least two work steps, since PTA of the stenosis must be performed first. The procedure with a suitable PTA balloon is similar to that described above for the implantation of balloon-mounted stents. After the PTA, a micro-catheter must be inserted for stent delivery. This can be done parallel to the existing wire, which advantageously marks the structures to be probed and secures access to the vessel distal to the stenosis. Usually,

however, a guide wire is used primarily for the PTA, through which the micro-catheter can subsequently be exchanged. In addition to the initial probing of the stenosis and the PTA, this maneuver represents a significant intervention risk, since replacement of the PTA balloon and catheter can again lead to movements of the wire tip and thus to distal perforations. Once the micro-catheter has been placed, the stent is released into the stenosis.

In addition to bleeding complications caused by wire perforations, the risks of endovascular treatment include vascular dissections and ruptures, immediate recurrent stenosis (“recoil”), in-stent thrombosis as well as perforator and embolic ischemia [35].

## Balloon-mounted vs. Self-expanding Stents

The off-label use of balloon-mounted coronary stents is quite common. Sales of Pharos Vitesse (Codman & Shurtleff, Raynham, Massachusetts, USA) and Channel (Balt, Montmorency, France) balloon-mounted stents approved for neurovascular use were discontinued in Europe in 2013 after approval expired, while the self-expanding Wingspan stent remains available.

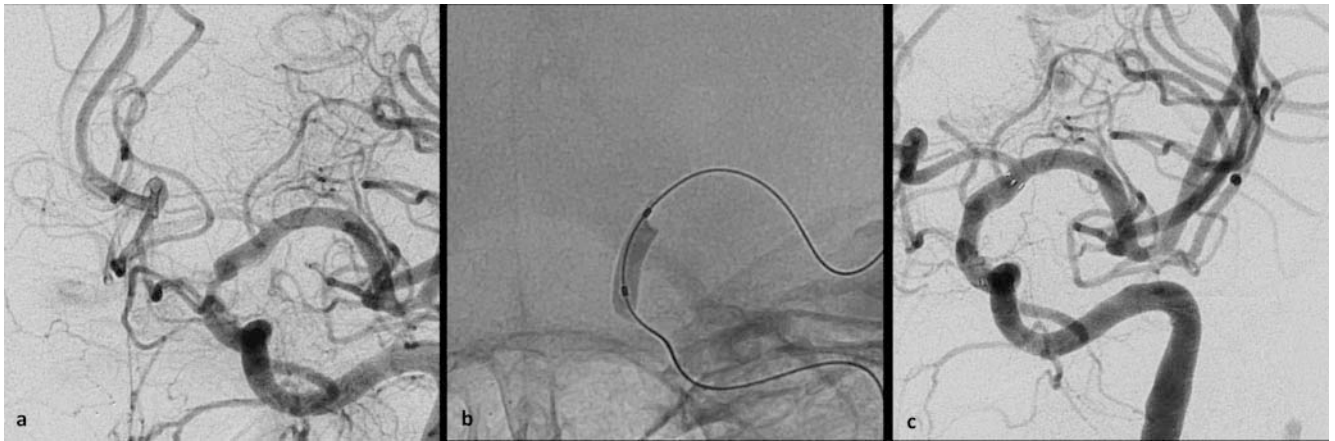
The use of self-expanding stents is preferred by some interventionalists due to the anatomical conditions in the M1 segment of the middle cerebral artery, while balloon-mounted stents are more common in the posterior circulation in the V4 segment of the vertebral artery and the basilar artery [36] as well as in the intracranial section of the carotid artery [37]. High recurrent stenosis rates of 24–28% speak against the use of self-expanding Enterprise and Wingspan stents [38, 39]. With comparable stent geometry, results with the Neuroform and Atlas stent (Stryker Neurovascular, Fremont, CA, USA) are likely to be more favorable. Due to the high costs associated with poor revenue, studies are just as unlikely as studies of drug-coated devices.

The SAMMPRIS and other studies found a higher rate of symptomatic strokes in the posterior circulation, especially in the basilar artery area [40–43] which could not be traced to the type of stents employed. Rather, a possible explanation for the higher stroke rate is postulated to be the closure of perforators by the atheromatous plaque dislocated and pressed in before the perforator exit during balloon dilatation (so-called “snow plow effect”), which could explain the higher rate of periprocedural ischemic strokes.

## Drug-coated Balloons and Stents

Neither drug-coated balloons nor stents have been studied in randomized trials in patients with ICAS. Paclitaxel and sirolimus-coated stents were developed for coronary stenosis and showed improved revascularization rates and less in-stent thrombosis compared to uncoated stents [44, 45]. Both substances have an anti-proliferative mechanism of action that reduces the migration and proliferation of endothelial muscle cells and thus neointimal hyperplasia [46].

Case series demonstrated the technical feasibility and good results regarding angiographic recurrence rates also with respect



► **Fig. 1** Symptomatic high-grade supraclinoid stenosis of the left internal carotid artery. Upper row: lateral projection, lower row: oblique projection (LAO). The stenosis affects the para-ophthalmic segment **a** and is dilated with a 3 mm balloon **b**. A self-expanding stent (3.5/15 mm) is implanted from slightly infra-ophthalmic to below the carotid T **c**. The ophthalmic artery, the posterior ramus, and the anterior choroid artery are covered by the stent without compromising flow.

to ICAS [47, 48]. In a retrospective comparison, the paclitaxel-coated Elutax DEB (drug-eluting balloon) (Aachen Resonance, Aachen, Germany) even showed a clear superiority over the Wingspan stent with respect to clinical recurrence and angiographic restenosis rate [49]. In a retrospective comparison of two drug-eluting stents (DES), 100 successful procedures showed a low restenosis rate of 3.6% exclusively after treatment with zotarolimus-coated Resolute Integrity™ (Medtronic Inc., Santa Rosa, CA, USA), and in no single case after treatment using paclitaxel-coated Taxus Element™ (Boston Scientific Corporation, Natick, MA, USA). The periprocedural complication rate was 9.9% and 3.0% for permanent disability [50]. Neither drug-coated balloons nor stents have been investigated in randomized trials in patients with ICAS.

## Premedication and Aftercare

All patients undergoing elective procedures should be premedicated with doubled thrombocyte factor with ASA and clopidogrel or another ADP receptor antagonist (see above). To rule out clopidogrel resistance, many clinics use thrombocyte function testing prior to stent implantation.

Immediately post-procedure, observation is required in the stroke unit or ICU with arterial pressure measurement and close monitoring of blood pressure to prevent hyperperfusion bleeding.

Following stent implantation, doubled thrombocyte function inhibitor is usually continued for three months, followed by lifelong platelet inhibition monotherapy with ASA.

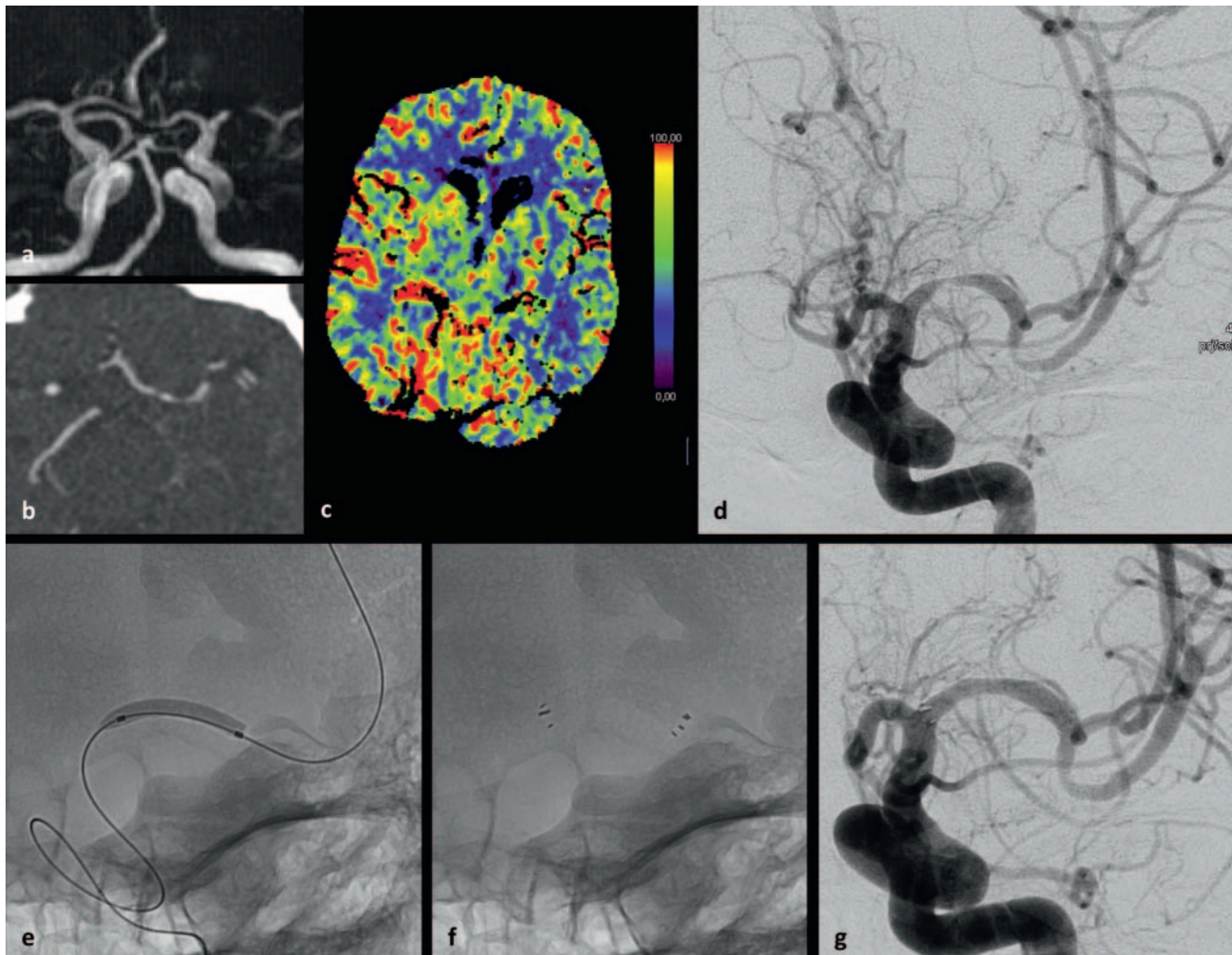
After a single PTA, doubled thrombocyte function inhibitor should be performed for at least one month, since even without stent implantation increased thrombogenicity of the endothelium injured by the angioplasty can initially be assumed. A useful follow-up examination might include, for example, sectional image diagnostic and/or transcranial doppler/duplex sonographic control after three to six months. In this case, the pre-interventional

imaging method should be used, as only in this way can a meaningful comparison be made with the initial findings.

Catheter angiographic control should be performed at least once after stent PTA, as most stents cause artifacts in both the CTA and the MRA. Due to significantly their reduced artifacts, Acclino and Credo stents (Acandis, Pforzheim, Germany) can be sufficiently assessed using CT angiography. In the case of asymptomatic recurrent stenoses, MR or CT perfusion helps to assess possible hemodynamic relevance for further planning of therapy and control intervals.

## Future Developments

One approach to avoiding perforator infarcts is to under-dimension the PTA balloon with the idea of mitigating the risk of the snow-plow effect; there are no other concepts, thus only identification of high-risk patients can avoid serious complications. Other typical complications, such as peri-interventional bleeding through wire perforations, can be reduced by more experienced interventionalists and technical innovations to avoid double-lumen balloon system switching maneuvers. The authors of the WEAVE register study explain their significantly lower complication rate with the Wingspan system compared to SAMMPRIS by, among other things, the experience of the interventionalists involved, which was the criterion for selecting the participating centers. The NeuroSpeed® double lumen PTA balloon (Acandis, Pforzheim, Germany) offers a technical approach to avoid distal perforations caused by uncontrolled micro-wire movements during changing maneuvers [51]. After the PTA, this enables stent delivery through the lumen originally used for the micro-wire. In this way, the stent can be released during withdrawal from the balloon catheter without further wire manipulation. The version of the NeuroSpeed balloon catheter initially used in the ASSISTENT study [52] together with a self-expanding stent (Credo®, Acandis, Pforzheim, Germany) proved to be easily navigable in the posterior circulation and also suitable for stent release in the



► **Fig. 2** Recurrent symptomatic stenosis of the left middle cerebral artery in the M1 segment with doubled inhibition of thrombocyte function. TOF MR angiography exaggerates the degree of stenosis **a** and CT angiography **b** shows a filiform stenosis whose hemodynamic effect confirms CT perfusion **c** (CBF map shows underperfusion in the left medial canal). The DSA confirms the CTA findings **d**. PTA is performed with a 2.0/15 mm balloon that is minimally undersized to protect the lenticulostriate perforators and avoid vascular injury **e**. Implantation of a 3.5/15 mm self-expanding stent from the mediabifurcation to the beginning of the M1 segment **g**.

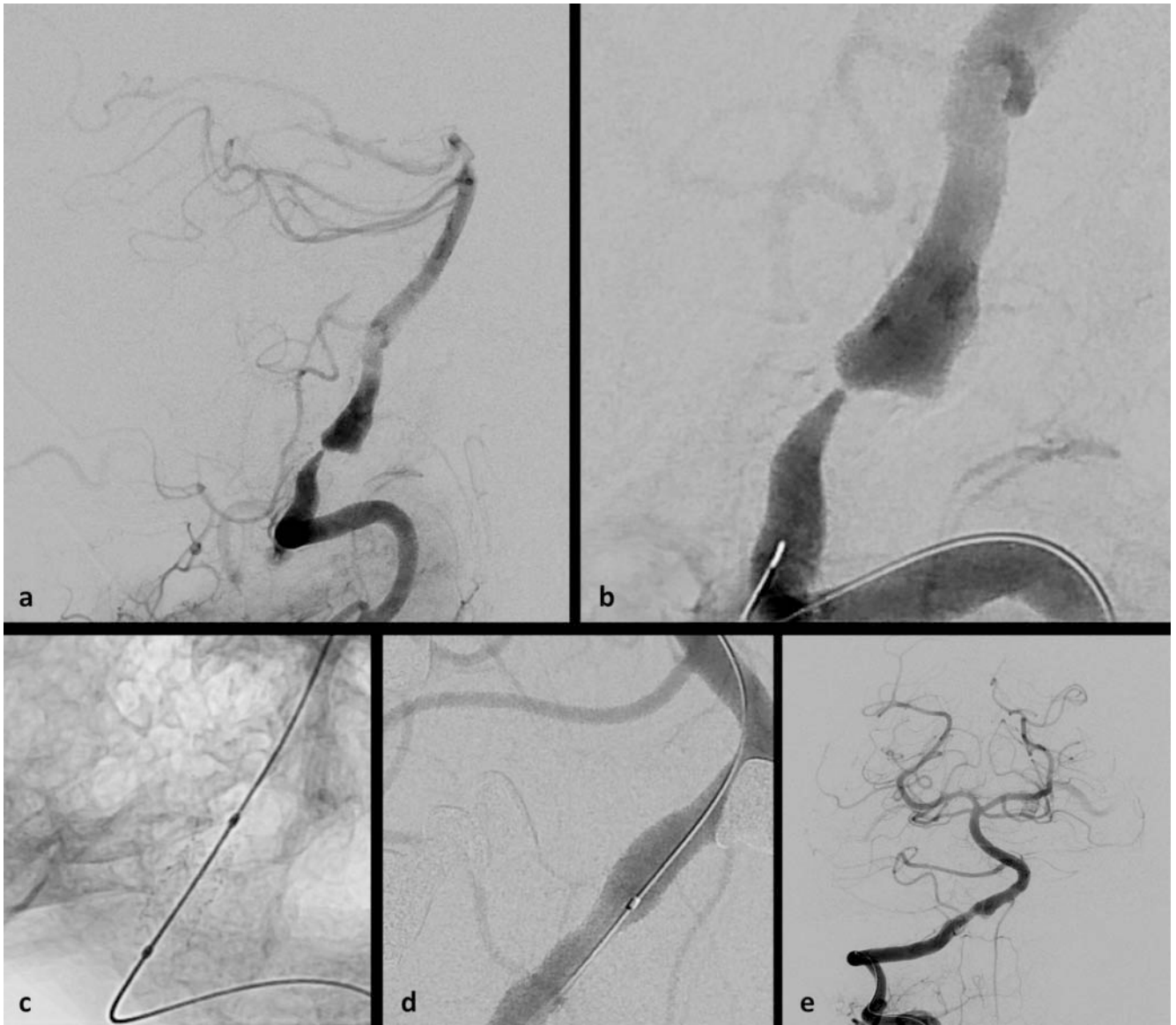
anterior circulation with less elongated extra- and intracranial progression of the internal carotid artery. The characteristics of the system were unsuitable in difficult anatomical conditions, so that patient inclusion in the study was suspended until the advanced system was available, and was restarted recently.

In the ACUTE study, also initiated by Acandis, the use of the NeuroSpeed balloon with the Credo stent will be used to treat acutely occluded intracranial stenoses following thrombectomy.

## Controversies and Statements of the Professional Societies

The somewhat sharp criticism of the SAMMPRIS study was rejected by the study authors [53, 54], and the results of the study had prompted the German Institute for Quality and Efficiency in Health Care (IQWiG) to publish on behalf of the Joint Federal

Committee (G-BA) a benefit assessment of stents for the treatment of symptomatic intracranial stenoses (Rapid Report N14–01) [55]. IQWiG stated in this report that “in the overall assessment, there is an indication of harm from stent PTA compared to purely drug treatment”. A critical reaction to this was expressed in two joint commentaries by the Professional Association of Neuroradiologists (BDNR), the German Society for Neuroradiology (DGNR), the German Society for Neurology (DGN) and the German Stroke Society (DSG) [56, 57], which clearly advocated at least two indications for the use of stents for the treatment of intracranial stenosis: in the acute treatment of intracranial vessel occlusion, and in patients under drug therapy with progressive stroke symptoms triggered by high-grade intracranial stenosis. On September 15, 2016, based on the above-mentioned IQWiG report, the Joint Federal Committee decided that the use of stents to treat intracranial vascular stenosis will be largely excluded from reimbursement [58]. The use of stents in patients with acute



► **Fig. 3** High-grade recurrent symptomatic hemodynamic stenosis of the distal V4 segment of the right vertebral artery with poststenotic ectasia and occlusion of the contralateral vertebral artery **a, b**. There is a wash-out phenomenon at the basilaris tip by competing supply via the posterior communicating arteries. The straight course of the stenosed segment allows unhindered navigation and implantation of a balloon-mounted stent (3.5/8 mm) **c, d**. Subsequent angiography shows a normalization of the flow up to the basilaris tip **e**; the initial wash-out can no longer be observed due to the improved hemodynamics.

vascular occlusion remained unaffected by the exclusion of benefits, based on high-grade intracranial stenosis and in the absence or failure of alternative therapy concepts and in patients with a stenosis level of  $\geq 70\%$ , which after a stenosis-related infarction at least one more infarct was experienced despite subsequent intensive drug therapy. Patients with hemodynamic infarction patterns are not included in the overall Joint Federal Committee assessment as a group unaffected by the exclusion as they were not included in the existing studies. On the other hand, in their statement the professional associations point out that the indication for stent angioplasty can also be a useful and life-saving measure for hemodynamically-relevant vascular constrictions (► **Fig. 2**) [57].

The US Food and Drug Administration (FDA) has also severely restricted the use of the Wingspan stent according to SAMMPRIS and only approved it for patients who meet all of the following 4 criteria [59]:

- 70 – 99% arteriosclerotic intracranial stenosis with repeated strokes
- Good functional condition with a value of 0 – 3 on the modified Rankin scale
- $\geq 2$  strokes under aggressive drug therapy
- Last stroke  $> 7$  days prior to the scheduled stenting

## Summary

There is a need for an interdisciplinary, clinically justified indication for the endovascular treatment of intracranial arteriosclerotic stenoses. The results of the clinical studies have shown that the conservative approach with best medical treatment after initial symptomatology is useful. However, negative results of the randomized trials should not lead to patients being deprived of the method when conservative therapy is insufficient. There is a need for further studies to identify subgroups, e. g. those who would benefit from endovascular therapy due to hemodynamic infarction or non-response to intensified drug therapy.

Balloon-mounted and self-expanding stents can be deployed intracranially, and recurrent stenoses can be reduced by using drug-coated balloons and stents. Technical and anatomical limitations lie in the nature of the materials used. In the future, the risk of distal wire perforations due to changing maneuvers could be reduced by using double-lumen balloons. The ASSISTENT and ACUTE studies will investigate the use of Credo stents for intracranial stenoses.

## Conflict of Interest

The authors declare that they have no conflict of interest.

## References

- Feigin VL, Forouzanfar MH, Krishnamurthi R et al. Global and regional burden of stroke during 1990–2010: findings from the Global Burden of Disease Study 2010. *Lancet* 2014; 383: 245–254
- Wang Y, Zhao X, Liu L et al. Prevalence and outcomes of symptomatic intracranial large artery stenoses and occlusions in China: the Chinese Intracranial Atherosclerosis (CICAS) Study. *Stroke* 2014; 45: 663–669
- Suri MFK, Qiao Y, Ma X et al. Prevalence of Intracranial Atherosclerotic Stenosis Using High-Resolution Magnetic Resonance Angiography in the General Population: The Atherosclerosis Risk in Communities Study. *Stroke* 2016; 47: 1187–1193
- Caplan LR. Intracranial branch atheromatous disease: a neglected, understudied, and underused concept. *Neurology* 1989; 39: 1246–1250
- Holmstedt CA, Turan TN, Chimowitz MI. Atherosclerotic intracranial arterial stenosis: risk factors, diagnosis, and treatment. *Lancet Neurol* 2013; 12: 1106–1114
- Kim JS, Nah HW, Park SM et al. Risk factors and stroke mechanisms in atherosclerotic stroke: intracranial compared with extracranial and anterior compared with posterior circulation disease. *Stroke* 2012; 43: 3313–3318
- Kern R, Steinke W, Daffertshofer M et al. Stroke recurrences in patients with symptomatic vs asymptomatic middle cerebral artery disease. *Neurology* 2005; 65: 859–864
- Kasner SE, Chimowitz MI, Lynn MJ et al. Predictors of Ischemic Stroke in the Territory of a Symptomatic Intracranial Arterial Stenosis. *Circulation* 2006; 113: 555–563
- Mazighi M, Tanasescu R, Ducrocq X et al. Prospective study of symptomatic atherothrombotic intracranial stenoses: the GESICA study. *Neurology* 2006; 66: 1187–1191
- Powers WJ, Clarke WR, Grubb RL et al. Extracranial-Intracranial Bypass Surgery for Stroke Prevention in Hemodynamic Cerebral Ischemia: The Carotid Occlusion Surgery Study: A Randomized Trial. *JAMA J Am Med Assoc* 2011; 306: 1983–1992
- The SSYLVA Study Investigators. Stenting of Symptomatic Atherosclerotic Lesions in the Vertebral or Intracranial Arteries (SSYLVA): Study Results. *Stroke* 2004; 35: 1388–1392
- Bose A, Hartmann M, Henkes H et al. A Novel, Self-Expanding, Nitinol Stent in Medically Refractory Intracranial Atherosclerotic Stenoses: The Wingspan Study. *Stroke* 2007; 38: 1531–1537
- Costalat V, Maldonado IL, Vendrell JF et al. Endovascular treatment of symptomatic intracranial stenosis with the Wingspan stent system and Gateway PTA balloon: a multicenter series of 60 patients with acute and midterm results. *J Neurosurg* 2011; 115: 686–693
- Costalat V, Maldonado IL, Zerlauth JB et al. Endovascular treatment of symptomatic intracranial arterial stenosis: six-year experience in a single-center series of 42 consecutive patients with acute and mid-term results. *Neurosurgery* 2010; 67: 1505–1513; discussion 1513–1514
- Gandini R, Chiaravalloti A, Pampana E et al. Intracranial atheromatous disease treatment with the Wingspan stent system: evaluation of clinical, procedural outcome and restenosis rate in a single-center series of 21 consecutive patients with acute and mid-term results. *Clin Neurol Neurosurg* 2013; 115: 741–747
- Chimowitz MI, Lynn MJ, Derdeyn CP et al. Stenting versus aggressive medical therapy for intracranial arterial stenosis. *N Engl J Med* 2011; 365: 993–1003
- Zaidat OO, Fitzsimmons BF, Woodward BK et al. Effect of a Balloon-Expandable Intracranial Stent vs Medical Therapy on Risk of Stroke in Patients With Symptomatic Intracranial Stenosis: The VISSIT Randomized Clinical Trial. *JAMA* 2015; 313: 1240
- Alexander M. WEAVE: Positive Phase 4 Results for Intracranial Stenting. *Int. Stroke Conf. ISC 2018 Late-Break. Abstr.* 13 Present. January 25 2018o. J.
- Genton E, Barnett HJ, Fields WS et al. XIV. Cerebral ischemia: the role of thrombosis and of antithrombotic therapy. Study group on antithrombotic therapy. *Stroke* 1977; 8: 150–175
- Chimowitz MI, Lynn MJ, Howlett-Smith H et al. Comparison of warfarin and aspirin for symptomatic intracranial arterial stenosis. *N Engl J Med* 2005; 352: 1305–1316
- Jung JM, Kang DW, Yu KH et al. Predictors of Recurrent Stroke in Patients With Symptomatic Intracranial Arterial Stenosis. *Stroke* 2012; 43: 2785–2787
- Markus HS, Droste DW, Kaps M et al. Dual Antiplatelet Therapy With Clopidogrel and Aspirin in Symptomatic Carotid Stenosis Evaluated Using Doppler Embolic Signal Detection: The Clopidogrel and Aspirin for Reduction of Emboli in Symptomatic Carotid Stenosis (CARESS) Trial. *Circulation* 2005; 111: 2233–2240
- Fox KAA, Mehta SR, Peters R et al. Benefits and Risks of the Combination of Clopidogrel and Aspirin in Patients Undergoing Surgical Revascularization for Non-ST-Elevation Acute Coronary Syndrome: The Clopidogrel in Unstable angina to prevent Recurrent ischemic Events (CURE) Trial. *Circulation* 2004; 110: 1202–1208
- Steinhubl SR, Berger PB, Iii JTM et al. Early and Sustained Dual Oral Antiplatelet Therapy Following Percutaneous Coronary Intervention: A Randomized Controlled Trial. *JAMA* 2002; 288: 2411–2420
- Wang Y, Zhao X, Lin J et al. Association Between CYP2C19 Loss-of-Function Allele Status and Efficacy of Clopidogrel for Risk Reduction Among Patients With Minor Stroke or Transient Ischemic Attack. *JAMA* 2016; 316: 70–78
- Schömig A. Ticagrelor – Is There Need for a New Player in the Antiplatelet-Therapy Field? *N Engl J Med* 2009; 361: 1108–1111
- Johnston SC, Amarenco P, Albers GW et al. Ticagrelor versus Aspirin in Acute Stroke or Transient Ischemic Attack. *N Engl J Med* 2016; 375: 35–43
- Efficacy and safety of ticagrelor versus aspirin in acute stroke or transient ischaemic attack of atherosclerotic origin: a subgroup analysis of SO... – PubMed – NCBI. o. J.



- [29] Akbari SH, Reynolds MR, Kadkhodayan Y et al. Hemorrhagic complications after prasugrel (Effient) therapy for vascular neurointerventional procedures. *J Neurointerventional Surg* 2013; 5: 337–343
- [30] Kwon SU, Cho YJ, Koo JS et al. Cilostazol Prevents the Progression of the Symptomatic Intracranial Arterial Stenosis: The Multicenter Double-Blind Placebo-Controlled Trial of Cilostazol in Symptomatic Intracranial Arterial Stenosis. *Stroke* 2005; 36: 782–786
- [31] Kwon SU, Hong KS, Kang DW et al. Efficacy and safety of combination antiplatelet therapies in patients with symptomatic intracranial atherosclerotic stenosis. *Stroke* 2011; 42: 2883–2890
- [32] Leung TW. Evolution of intracranial atherosclerotic disease under modern medical therapy. – PubMed – NCBI. o. J.
- [33] Nordmeyer H, Chapot R, Aycil A et al. Angioplasty and Stenting of Intracranial Arterial Stenosis in Perforator-Bearing Segments: A Comparison Between the Anterior and the Posterior Circulation. *Front Neurol* 2018; 9: 533
- [34] Qureshi AI, Chaudhry SA, Siddiq F et al. A randomized trial comparing primary angioplasty versus stent placement for symptomatic intracranial stenosis. *J Vasc Interv Neurol* 2013; 6: 34–41
- [35] Jiang WJ, Srivastava T, Gao F et al. Perforator stroke after elective stenting of symptomatic intracranial stenosis. *Neurology* 2006; 66: 1868–1872
- [36] Aycil A, Weber R, Chapot R et al. Comparison of periprocedural complications and long-term outcome of intracranial angioplasty alone or with stenting of perforator-bearing arteries in the anterior and posterior circulation. *Eur Stroke J* 2017; 2: 09–034
- [37] Park S, Kim JH, Kwak JK et al. Intracranial stenting for severe symptomatic stenosis: self-expandable versus balloon-expandable stents. *Interv Neuroradiol J Peritherapeutic Neuroradiol Surg Proced Relat Neurosci* 2013; 19: 276–282
- [38] Vajda Z, Schmid E, Güthe T et al. The modified Bose method for the endovascular treatment of intracranial atherosclerotic arterial stenoses using the Enterprise stent. *Neurosurgery* 2012; 70: 91–101; discussion 101
- [39] Jiang WJ, Cheng-Ching E, Abou-Chebl A et al. Multicenter Analysis of Stenting in Symptomatic Intracranial Atherosclerosis. *Neurosurgery* 2012; 70: 25–31
- [40] Groschel K, Schnaudigel S, Pilgram SM et al. A Systematic Review on Outcome After Stenting for Intracranial Atherosclerosis. *Stroke* 2009; 40: e340–e347
- [41] Jiang WJ, Du B, Hon SFK et al. Do patients with basilar or vertebral artery stenosis have a higher stroke incidence poststenting? *J Neurointerventional Surg* 2010; 2: 50–54
- [42] Derdeyn CP, Fiorella D, Lynn MJ et al. Mechanisms of Stroke After Intracranial Angioplasty and Stenting in the SAMMPRIS Trial. *Neurosurgery* 2013; 72: 777–795
- [43] Li TX, Gao BL, Cai DY et al. Wingspan Stenting for Severe Symptomatic Intracranial Atherosclerotic Stenosis in 433 Patients Treated at a Single Medical Center. *PLoS ONE* 2015; 10: e0139377
- [44] Di Lorenzo E, Sauro R, Varricchio A et al. Benefits of drug-eluting stents as compared to bare metal stent in ST-segment elevation myocardial infarction: four year results of the PaclitAxel or Sirolimus-Eluting stent vs bare metal stent in primary angioplasty (PASEO) randomized trial. *Am Heart J* 2009; 158: e43–e50
- [45] Stone GW, Lansky AJ, Pocock SJ et al. Paclitaxel-eluting stents versus bare-metal stents in acute myocardial infarction. *N Engl J Med* 2009; 360: 1946–1959
- [46] Costa MA, Simon DI. Molecular basis of restenosis and drug-eluting stents. *Circulation* 2005; 111: 2257–2273
- [47] Park S, Lee D, Chung WJ et al. Long-term Outcomes of Drug-eluting Stents in Symptomatic Intracranial Stenosis. *Neurointervention* 2013; 8: 9–14
- [48] Qureshi AI, Kirmani JF, Hussein HM et al. Early and intermediate-term outcomes with drug-eluting stents in high-risk patients with symptomatic intracranial stenosis. *Neurosurgery* 2006; 59: 1044–1051
- [49] Gruber P, Garcia-Esperon C, Berberat J et al. Neuro Elutax SV drug-eluting balloon versus Wingspan stent system in symptomatic intracranial high-grade stenosis: a single-center experience. *J NeuroInterventional Surg* 2018. doi:neurintsurg-2017-013699
- [50] Kurre W, Aguilar-Pérez M, Fischer S et al. Solving the Issue of Restenosis After Stenting of Intracranial Stenoses: Experience with Two Thin-Strut Drug-Eluting Stents (DES)–Taxus Element™ and Resolute Integrity™. *Cardiovasc Intervent Radiol* 2015; 38: 583–591
- [51] Möhlenbruch MA, Pfaff J, Herweh C et al. One-pass endovascular treatment of intracranial atherosclerotic stenosis with a novel PTA balloon and self-expanding microstent. *Neuroradiology* 2016; 58: 893–899
- [52] Thomalla G. ASSISTENT – Register: Ein Zwischenstand – Technische Herausforderungen und klinische Relevanz. o. J.
- [53] Abou-Chebl A, Steinmetz H. Critique of „Stenting Versus Aggressive Medical Therapy for Intracranial Arterial Stenosis“ by Chimowitz et al. in the New England Journal of Medicine. *Stroke* 2012; 43: 616–620
- [54] Chimowitz MI, Fiorella D, Derdeyn CP et al. Response to Critique of the Stenting and Aggressive Medical Management for Preventing Recurrent Stroke in Intracranial Stenosis (SAMMPRIS) Trial by Abou-Chebl and Steinmetz. *Stroke* 2012; 43: 2806–2809
- [55] IQWiG. Rapid Report N14-01, o. J.
- [56] Fiehler J. Studies in Intracranial Stenting: We Must Not Retire from the Game of Science. *Clin Neuroradiol* 2014; 24: 309–311
- [57] Kurre W, Berlis A, Diener HC et al. IQWiG Arbeitspapier GA15-02: „Stents zur Behandlung intrakranieller Stenosen: VISSIT Studie und Akutbehandlung in Deutschland“. *Clin Neuroradiol* 2015; 25: 445–449
- [58] G-BA. Einsatz von Stents zur Behandlung intrakranieller Gefäßstenosen weitgehend ausgeschlossen – Gemeinsamer Bundesausschuss. o. J.
- [59] FDA. Food and Drug Administration. FDA safety communication: narrowed indications for use for the Wingspan Stent System. August 8, 2012. o. J.