Published online: 2019-03-13

Treatment of multiple esophageal diverticula by peroral endoscopic myotomy

A 55-year-old man with persistent dysphagia and chest pain for 5 years was referred to our medical team. Gastroscopy (Olympus, Tokyo, Japan) revealed two distinct diverticula: one mid-esophageal diverticulum located 33 cm from the incisors and another "kissing" epiphrenic diverticula 43 cm from the incisors (▶ **Fig. 1**, preoperation). Barium swallow showed the size of the esophageal diverticula to be 4 mm, 19 mm and 22 mm, respectively (▶ **Fig. 2**, preoperation). Esophageal manometry showed no findings of a primary motility disorder (▶ **Fig. 3**).

The patient asked for minimally invasive therapy, so we used peroral endoscopic myotomy (POEM) (▶ **Video 1**). A 2-cm oblique mucosal incision was made between the "kissing" diverticula, at 3–5 cm above the diverticula, using a triangle-tip knife positioned at the tunnel entry. Another incision was made on the same side 3–5 cm above the single diverticulum, which was 33 cm from the incisors. For both diverticula, a submucosal longitudinal tunnel was made on each side of the septum and ended 1–2 cm distal to the bottom of the diverticulum. Circular muscle, longitudinal muscle, and base muscle between the esophageal lumen and diverticulum were dissected using the triangle-tip knife (▶ **Fig. 4**, ▶ **Fig. 5**). Finally, the mucosal incisions were closed with hemostatic clips.

The patient took semifluid food the following day, and was discharged from hospital on postoperative day 7 with symptoms completely resolved. A barium swallow test 1 week later showed a dramatically flatter diverticula bottom (▶ **Fig. 2**, postoperation). The 1-month follow-up gastroscopy showed increased esophageal lumen (▶ **Fig. 1**, postoperation), and the patient had gained 3 kg in weight.

The first application of POEM was reported in 2010 [1]. Since then, POEM has been applied to gastroparesis and esophageal diverticulum [2–3]. In the present

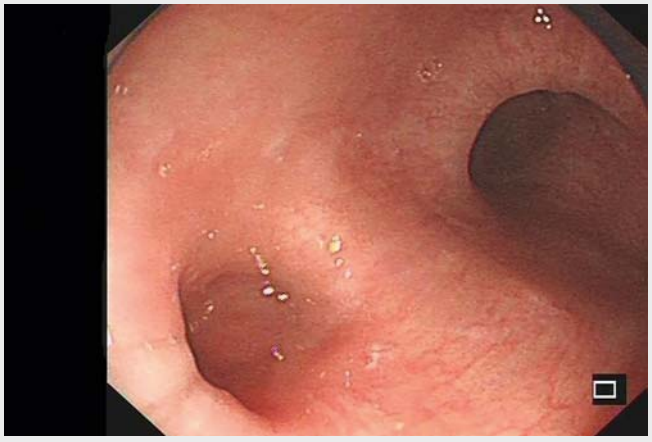

▶ **Video 1** Gastroscopy showed multiple esophageal diverticula, which were treated successfully by peroral endoscopic myotomy.

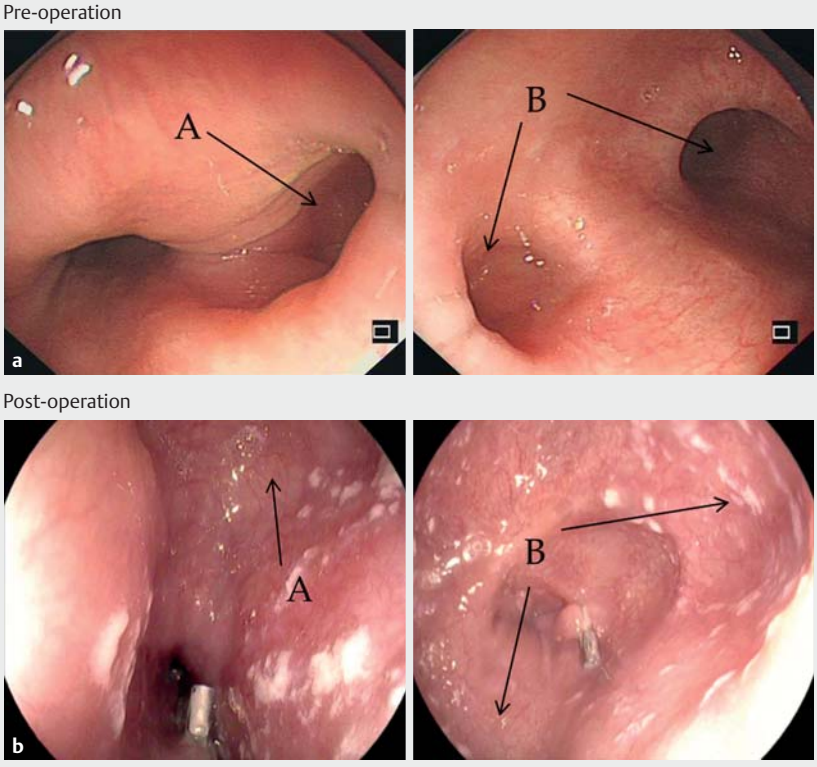

▶ **Fig. 1** Pre- (**a**) and postoperative (**b**) (1-month follow-up) gastroendoscopic images of two distinct esophageal diverticula: single esophageal diverticulum at 33 cm from the incisors (A); "kissing" esophageal diverticula at 43 cm from the incisors (B).

This document was downloaded for personal use only. Unauthorized distribution is strictly prohibited.

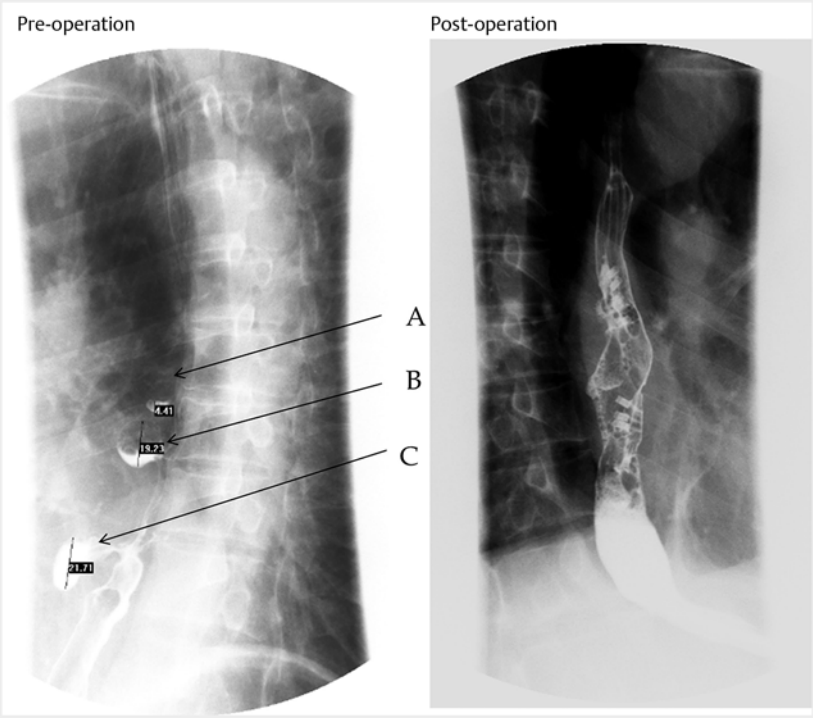

▶ **Fig. 2** Pre- and postoperative (1-week follow-up) barium swallow results. The sizes of the three esophageal diverticula were 4 mm (A), 19 mm (B), and 22 mm (C), respectively.

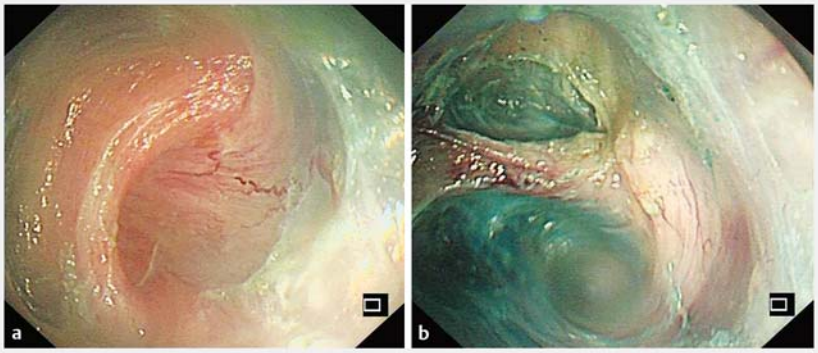

▶ **Fig. 4** Peroral endoscopic myotomy of the single diverticulum. **a** A submucosal tunnel was made in the single esophageal diverticulum at 33 cm from the incisors. **b** The base muscle between the esophageal lumen and the diverticulum was dissected.

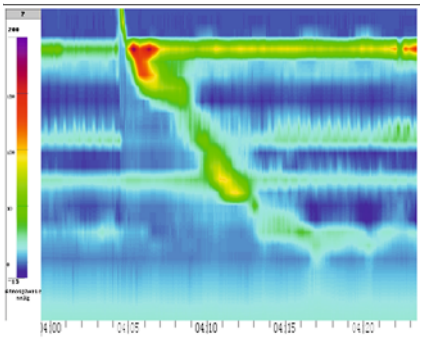

▶ **Fig. 3** Esophageal manometry results showed no findings of a primary motility disorder.

case, we successfully treated multiple esophageal diverticula by POEM, which expanded its application. Further studies on the long-term efficacy and follow-up after POEM are required.

Endoscopy_UCTN_Code_CCL_1AB_2AC_3AF

Competing interests

None

The authors

Li-Hua Ren, Ya-Dong Feng, Rui-Hua Shi
Department of Gastroenterology, Zhongda Hospital, School of Medicine, Southeast University, Nanjing, China

Corresponding author

Rui-Hua Shi, PhD, MD
Department of Gastroenterology, Zhongda Hospital, School of Medicine, Southeast University, No. 87 Dingjiaqiao Road, Jiangsu Province, Nanjing 210009, China
Fax: +86-025-83262835
ruihuashi@126.com

This document was downloaded for personal use only. Unauthorized distribution is strictly prohibited.

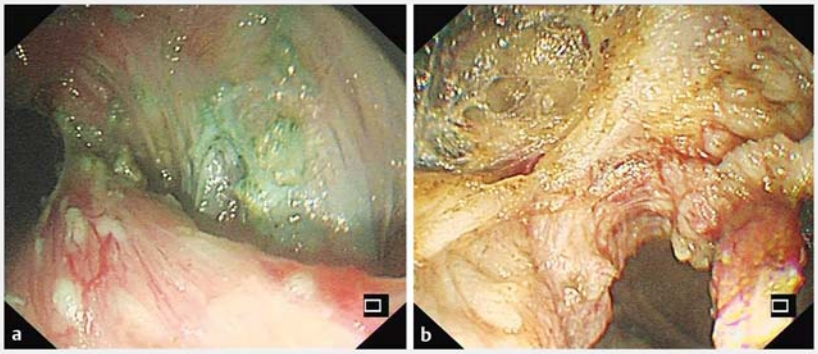

▶ **Fig. 5** Peroral endoscopic myotomy of the "Kissing" esophageal diverticula. **a** A submucosal tunnel was made at 43 cm from the incisors. **b** The base muscle between the esophageal lumen and diverticula was dissected.

References

[1] Inoue H, Minami H, Kobayashi Y et al. Peroral endoscopic myotomy (POEM) for esophageal achalasia. Endoscopy 2010; 42: 265–271

[2] Li QL, Chen WF, Zhang XC et al. Submucosal tunneling endoscopic septum division: a novel technique for treating Zenker's diverticulum. Gastroenterology 2016; 151: 1071–1074

[3] Wu C, Zhang Q, Liu W et al. Successful treatment of giant esophageal diverticulum by per-oral endoscopic myotomy. Endoscopy 2018; 50: E107–E108

Bibliography
DOI https://doi.org/10.1055/a-0836-2406
Published online: 13.3.2019
Endoscopy 2019; 51: E122–E124
© Georg Thieme Verlag KG
Stuttgart · New York
ISSN 0013-726X

ENDOSCOPY E-VIDEOS
https://eref.thieme.de/e-videos

Endoscopy E-Videos is a free access online section, reporting on interesting cases and new techniques in gastroenterological endoscopy. All papers include a high quality video and all contributions are freely accessible online.

This section has its own submission website at https://mc.manuscriptcentral.com/e-videos

This document was downloaded for personal use only. Unauthorized distribution is strictly prohibited.