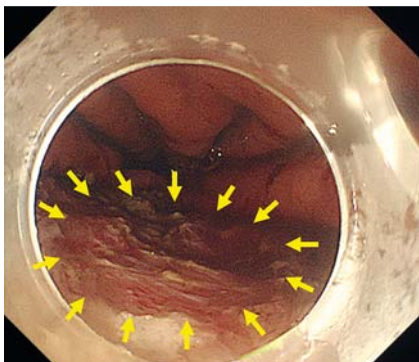


Endoscopic technique for closure of a large gastric tube perforation by using endoclips with line-assisted complete closure

Endoscopic submucosal dissection (ESD) is an acceptable treatment for gastric tube cancer after an esophagectomy [1]. However, treatment of lesions on the suture line is difficult and may cause perforations. It is sometimes difficult to



► **Fig. 1** Endoscopic view showing a large perforation (yellow arrowheads) in the gastric tube during endoscopic submucosal dissection.

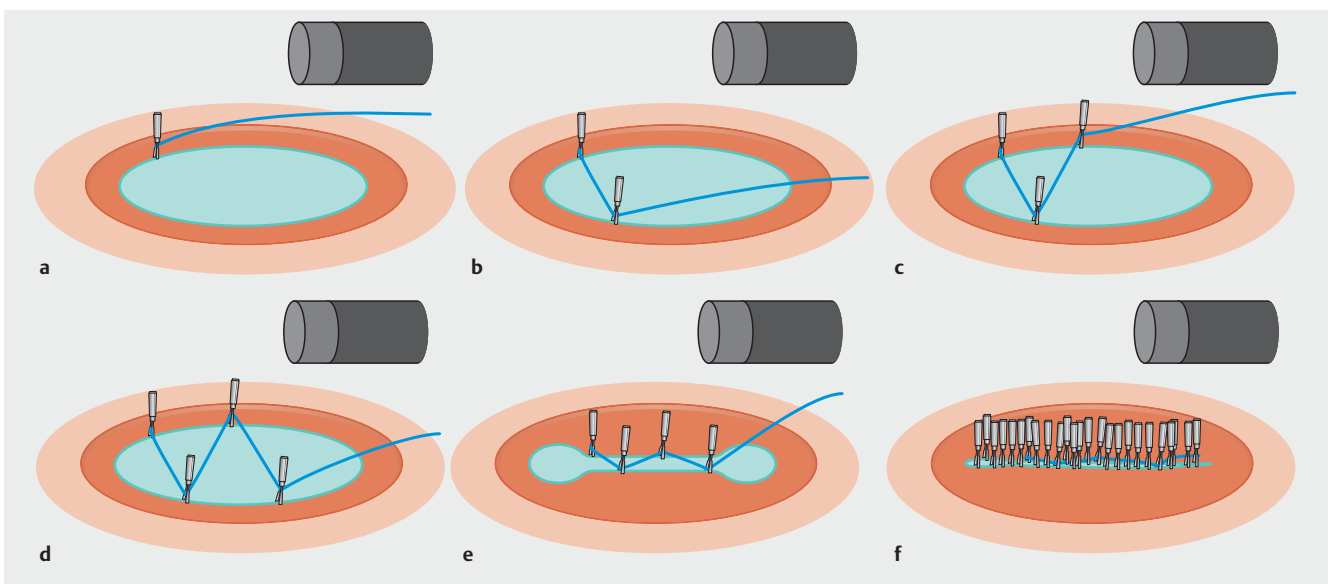
close a large perforation with endoclips. We report an endoscopic technique that enabled the closure of a large perforation by using the line-assisted complete closure (LACC) method [2–5].

An 87-year-old man with early gastric cancer located on the suture line of the lesser curvature of the gastric tube, after subtotal esophagectomy, underwent ESD. During ESD, severe fibrosis and staples were encountered in the submucosal layer of the suture line. To achieve en bloc resection, dissection was performed just below the staples. As a result, a large perforation occurred, exposing the mediastinum (► **Fig. 1**). The perforation could not be closed with endoscopic clip placement because of its large size. Therefore, we endoscopically closed the perforation by using endoclips with LACC (► **Fig. 2**, ► **Video 1**).

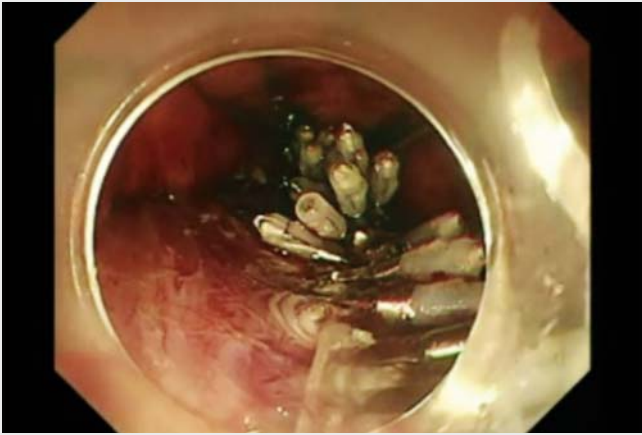
An endoclip (HX-610-090; Olympus, Tokyo, Japan) with 1-0 silk line was

placed at the side of the perforation site (► **Fig. 2a**, ► **Fig. 3a, b**). To anchor the line, another endoclip was placed on the other side (► **Fig. 2b**). The same procedure was repeated, and a total of four endoclips were placed along the perforation line (► **Fig. 2c, d**, ► **Fig. 3c**). Both sides of the perforation were gathered by pulling the anchor line (► **Fig. 2e**). Additional endoclips were placed to achieve complete closure (► **Fig. 2f**, ► **Fig. 3d**). After 7 days, an endoscopic examination revealed that the perforation site was filled with regenerating tissue. Therefore, we initiated oral intake, which the patient tolerated well. After 2 months, post-ESD ulcer scarring was observed. This technique of using endoclips with LACC could be performed relatively easily and is potentially useful in closing a large perforation in the gastrointestinal tract.

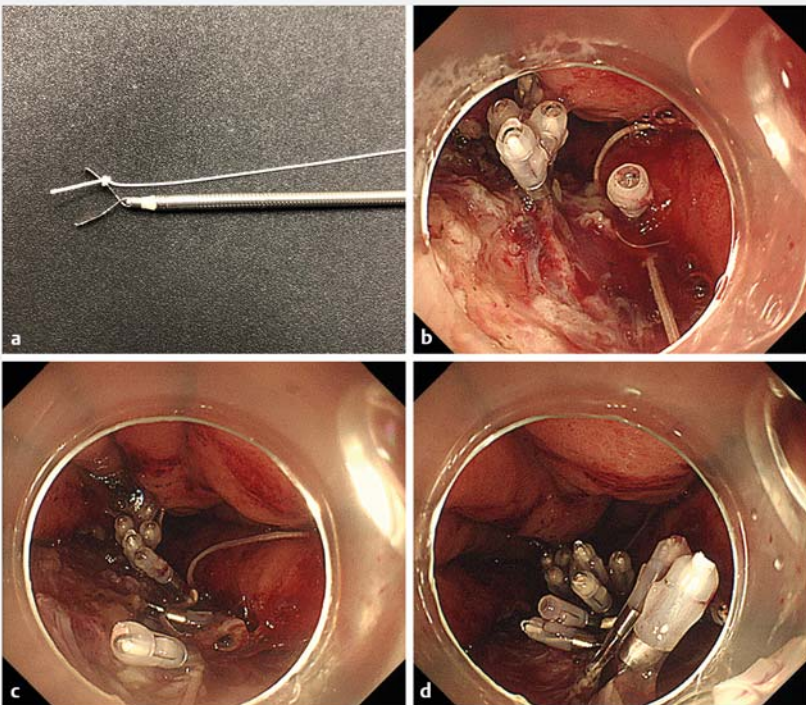
Endoscopy_UCTN_Code_CPL_1AH_2AZ



► **Fig. 2** Schematic diagram of endoscopic technique for closure of perforation using endoclips with the line-assisted complete closure method. **a** The first endoclip and line was placed on the right side of the perforation. **b** The line was anchored by the second endoclip to the left side of perforation. **c** The line was anchored by the third endoclip to the right side of the perforation, which was proximal to the first endoclip. **d** The line was anchored by the fourth endoclip to the left side of the perforation, which was proximal to the second endoclip. **e** Both sides of the perforation were gathered by pulling the anchor line. **f** Additional endoclips were placed to achieve complete closure.



▶ **Video 1** Endoscopic technique for closure of a large gastric tube perforation by using endoclips with line-assisted complete closure.



▶ **Fig. 3** Endoscopic technique for closure of perforation using endoclips with the line-assisted complete closure method. **a** A long silk line was tied to the arm of an endoclip. **b** The endoclip and line were placed on the side of the perforation. **c** The line was anchored alternately left and right by using additional endoclips, and both sides of the perforation were gathered by pulling the anchor line. **d** Additional endoclips were placed to achieve complete closure.

Competing interests

None

The authors

Masaki Ominami, Yasuaki Nagami, Chieko Tanaka, Taishi Sakai, Shusei Fukunaga, Toshio Watanabe, Yasuhiro Fujiwara
Department of Gastroenterology, Osaka City University Graduate School of Medicine, Osaka, Japan

Corresponding author

Yasuaki Nagami, MD

Department of Gastroenterology, Osaka City University Graduate School of Medicine, 1-4-3, Asahimachi, Abeno-ku, Osaka, 545-8585, Japan
Fax: +81-6-66453813
yasuaki1975@hotmail.com

References

- [1] Nonaka S, Oda I, Sato C et al. Endoscopic submucosal dissection for gastric tube cancer after esophagectomy. *Gastrointest Endosc* 2014; 79: 260–270
- [2] Yahagi N, Nishizawa T, Akimoto T et al. New endoscopic suturing method: string clip suturing method. *Gastrointest Endosc* 2016; 84: 1064–1065
- [3] Kato M, Takeuchi Y, Yamasaki Y. Line-assisted complete closure of a large colorectal mucosal defect after endoscopic submucosal dissection. *Dig Endosc* 2016; 28: 686
- [4] Kato M, Takeuchi Y, Yamasaki Y et al. Technical feasibility of line-assisted complete closure technique for large mucosal defects after colorectal endoscopic submucosal dissection. *Endosc Int Open* 2017; 5: E11–E16
- [5] Nakahira H, Takeuchi Y, Garcia JS et al. Line-assisted endoscopic complete closure of a large perforation during colonic endoscopic submucosal dissection. *Endoscopy* 2018; 50: E32–E33

Bibliography

DOI <https://doi.org/10.1055/a-0800-8502>
Published online: 14.12.2018
Endoscopy 2019; 51: E49–E50
© Georg Thieme Verlag KG
Stuttgart · New York
ISSN 0013-726X