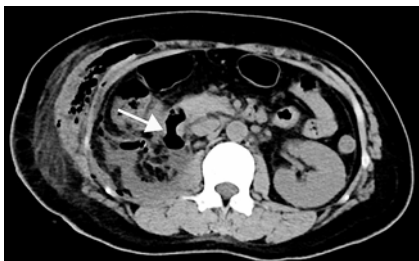


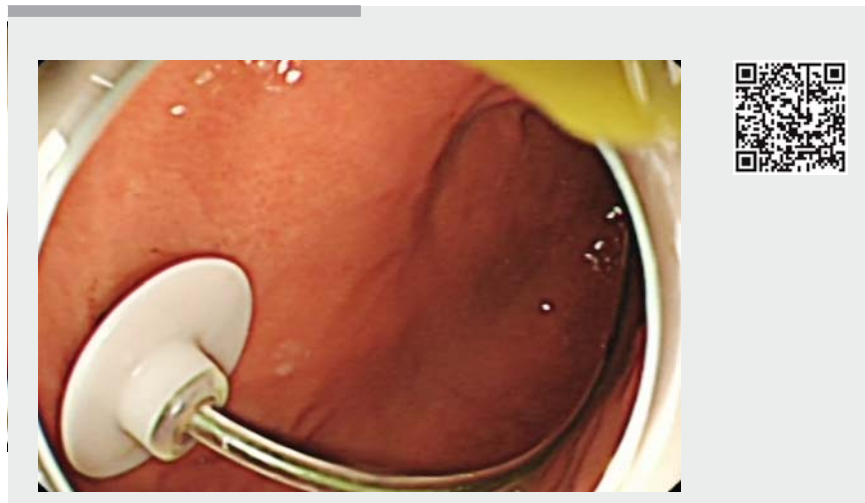
## Purse-string suture and double percutaneous endoscopic gastrostomies for treating a postoperative duodenal fistula



► **Fig. 1** The duodenal fistula (arrow) was demonstrated on abdominal computed tomography.

A 43-year-old woman was referred to our department owing to uncontained duodenal leak, drained from the retroperitoneal space (>500 mL/24 h) (► **Fig. 1**). Her medical history was significant for laparoscopic right nephrectomy owing to calculous pyonephrosis 7 days earlier. The patient refused surgery; thus, endoscopic intervention was performed (► **Video 1**).

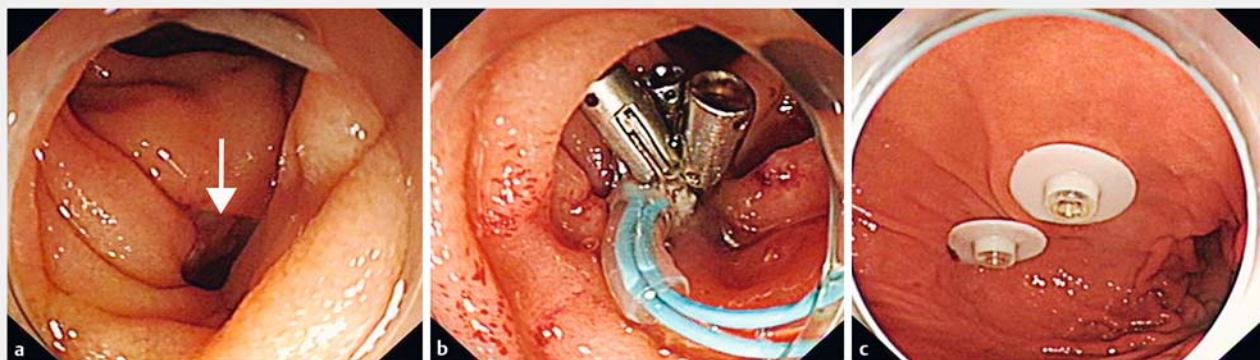
Upper endoscopy confirmed the presence of the fistula at the junction of the duodenal bulb and descending duodenum (► **Fig. 2a**). Successful closure of the defect was achieved using a purse-string suture after failed attempts with



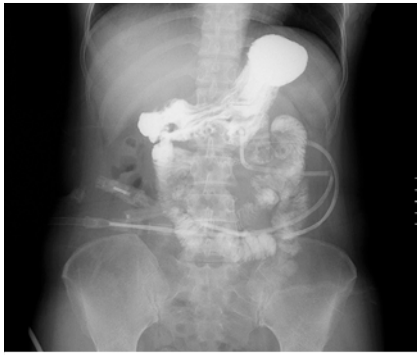► **Video 1** Purse-string suture and double percutaneous endoscopic gastrostomies for treating a postoperative duodenal fistula.

endoclips (► **Fig. 2b**). We then carried out double percutaneous endoscopic gastrostomies (PEG) (► **Fig. 2c**). One PEG with placement of a jejunal feeding tube was for enteral nutrition, whereas the other was connected to the negative pressure drainage bag for gastric decompression and drainage. A nasointestinal decompression tube with string attached

was placed near the fistula and fixed using an endoclip, for duodenal drainage. Conservative treatments were continued. The output from the retroperitoneal drainage tube reduced gradually, and no liquid was noted after 1 month. A gastrointestinal contrast study demonstrated no leaks (► **Fig. 3**). Repeat upper endoscopy also showed the healing of the duo-



► **Fig. 2** Endoscopic images. **a** The fistula (arrow) at the junction between the bulb and descending part of the duodenum was confirmed by upper endoscopy. **b** Closure of the fistula was conducted using a purse-string suture. **c** Double percutaneous endoscopic gastrostomies were performed for adequate drainage.



► **Fig. 3** No leak of contrast agent was noted on gastrointestinal imaging after 1 month.

denal fistula. The tubes were removed successively, and the patient resumed oral intake. During 9 months of follow-up, no abnormalities were reported. Duodenal fistulas are the most difficult to repair, and invasive surgical intervention remains the main treatment, especially for those with uncontained leaks [1]. Although many endoscopic techniques, including clipping and purse-string suture, have been used to close intraoperative perforations [2,3], duodenal fistulas closed by these methods may recur [1]. Fistula recurrence may be attributed to collected digestive juice, which harms the closed fistula and surrounding tissue. The current case demonstrated a method for adequate drain-

age of the stomach and the duodenum, to minimize additional contamination and injury. In addition, adequate nutritional support is also important for the healing of a duodenal fistula.

Endoscopy\_UCTN\_Code\_TTT\_1AO\_2AI

### Acknowledgment

This study was funded by the National Key R&D Program of China (2017YFC0112300).

### Competing interests

None

### The authors

**Liansong Ye<sup>\*</sup>, Xianhui Zeng<sup>\*</sup>, Xianglei Yuan, Linjie Guo, Yuyan Zhang, Yan Li, Bing Hu**  
Department of Gastroenterology, West China Hospital, Sichuan University, Chengdu, China

### Corresponding author

**Bing Hu, MD**  
Department of Gastroenterology, West China Hospital, 37 Guo Xue Alley, Wu Hou District, Chengdu City, Sichuan Province 610041  
Fax: +86-28-85423387  
hubingnj@163.com

\* These authors contributed equally to this work.

### References

- [1] Muniraj T, Aslanian HR. The use of Over-Stitch™ for the treatment of intestinal perforation, fistulas and leaks. *Gastrointest Interv* 2017; 6: 151 – 156
- [2] Rustagi T, McCarty TR, Aslanian HR. Endoscopic treatment of gastrointestinal perforations, leaks, and fistulae. *J Clin Gastroenterol* 2015; 49: 804 – 809
- [3] Li Q, Ji J, Wang F et al. ERCP-induced duodenal perforation successfully treated with endoscopic purse-string suture: a case report. *Oncotarget* 2015; 6: 17847 – 17850

### Bibliography

DOI <https://doi.org/10.1055/a-0800-8286>  
Published online: 11.1.2019  
*Endoscopy* 2019; 51: E55–E56  
© Georg Thieme Verlag KG  
Stuttgart · New York  
ISSN 0013-726X

**ENDOSCOPY E-VIDEOS**  
<https://eref.thieme.de/e-videos>



*Endoscopy E-Videos* is a free access online section, reporting on interesting cases and new techniques in gastroenterological endoscopy. All papers include a high quality video and all contributions are freely accessible online.

This section has its own submission website at  
<https://mc.manuscriptcentral.com/e-videos>