

Risk of cancer in 10–19 mm endoscopically detected colorectal lesions

Authors

Nasim Parsa¹, Prasanna Ponugoti², Heather Broadley², Jonathan Garcia², Douglas K. Rex²

Institutions

- 1 Department of Medicine, MedStar Harbor Hospital, Baltimore, Maryland, United States
- 2 Division of Gastroenterology and Hepatology, Indiana University School of Medicine, Indianapolis, Indiana, United States

submitted 16.1.2018

accepted after revision 25.10.2018

Bibliography

DOI <https://doi.org/10.1055/a-0799-9997>

Published online: 8.1.2019 | Endoscopy 2019; 51: 452–457

© Georg Thieme Verlag KG Stuttgart · New York

ISSN 0013-726X

Corresponding author

Douglas K. Rex, MD, Division of Gastroenterology and Hepatology, Indiana University School of Medicine, 550 North University Blvd, Suite 4159, Indianapolis, IN 46202, United States

Fax: +1-317-944-5449

drex@iupui.edu

ABSTRACT

Background Recent data indicate that the risk of cancer in colorectal lesions <10 mm is lower than previously reported, possibly reflecting improved detection of flat, low-volume

lesions with a low risk of cancer. Few studies have examined the prevalence of cancer in colorectal lesions 10–19 mm in size.

Methods We reviewed a prospectively collected database of all colorectal lesions removed at a single endoscopy center in order to identify lesions of 10–19 mm in size and review their histology. Lesions ≥20 mm were evaluated as a control group. We reviewed photographs of cancerous lesions to determine the frequency of endoscopic features of cancer.

Results A total of 5093 lesions ≥10 mm were removed from 4020 patients (mean age 63.2 years, 34.4% female). Among 3068 lesions 10–19 mm in size, 28 (0.9%) had adenocarcinoma, including 1.2% of conventional adenomas and 0.3% of serrated class lesions. These rates were lower than the 6.9% and 2.0% rates of cancer found in conventional adenomatous lesions and serrated lesions ≥20 mm, respectively. Cancer was suggested by endoscopic features in 52.0% of malignancies 10–19 mm in size compared with 79.2% of lesions ≥20 mm.

Conclusions The prevalence of cancer in 10–19 mm colorectal lesions was much lower than previously reported. The cancer risk was higher in conventional adenomas than in serrated lesions. Cancer was endoscopically evident prior to resection in slightly more than half of colorectal lesions 10–19 mm in size.

Introduction

Increasing colorectal polyp size has been consistently associated with a higher risk of invasive colorectal cancer [1–4]. Recent studies have focused on the prevalence of cancer in polyps <10 mm in size, and have identified a lower risk of invasive cancer compared with earlier studies [5–11]. Some recent studies have investigated this issue to determine the feasibility of a “resect and discard” strategy for diminutive polyps [7–9], as the prevalence of cancer in diminutive and small polyps is a determinant of the appropriateness of a resect and discard paradigm.

Declining rates of cancer in small and diminutive polyps may reflect improved optics in colonoscopes that expose large numbers of low-volume, flat adenomas with a much lower risk of

cancer [12–14] compared with the larger-volume polyps detectable with lower resolution and fiberoptic instruments used in older studies.

The anticipated risk of cancer in polyps ≥10 mm is also of importance to endoscopists, as polyps with a greater risk of cancer are optimally resected en bloc [15]. Thus, the risk of cancer may affect the resection approach. Furthermore, resected polyps with a higher cancer risk should be handled properly by the endoscopist and pathologist, so as to ensure proper orientation and optimal pathological assessment. Several studies have focused on cancer risk in colorectal polyps ≥20 mm [8, 16–17]. Although some studies have reported the risk of cancer in polyps 10–19 mm in size [8, 16–18], we considered that it would be useful to update the prevalence of cancer in polyps in this size range, as polyps of this size are common and this

issue has not been extensively studied using modern colonoscopes (► **Table 1**). We now report the largest study to address this issue.

Methods

We reviewed and analyzed a prospectively created database of polyps identified in the Indiana University Hospital endoscopy unit between January 2001 and June 2016. We included consecutive colonoscopies performed during the study period with the exception of those performed in patients with inflammatory bowel disease or polyposis syndrome. Patients with any other screening, surveillance, and diagnostic indications for colonoscopy were included in the database. Permission to review the database was granted on 6 December 2017 by the Institutional Review Board of our institution.

The database included patient demographic details, name of the endoscopist who performed the examination, polyp size (as measured by endoscopist estimate), polyp location in the colon (by endoscopist estimate), polyp morphology (by endoscopist recognition), polyp pathology (as reported in the routine pathology report), and the method of resection (endoscopic vs. surgical). For the purpose of this study, polyps ≥ 10 mm in size were grouped by size: 10–19 mm and ≥ 20 mm.

Conventional adenomas were defined as those interpreted pathologically as tubular, tubulovillous, or villous adenomas. Serrated class lesions were defined as those interpreted as hyperplastic polyp, sessile serrated polyp, sessile serrated adenoma,

serrated adenoma, and traditional serrated adenoma. Cancer was defined as submucosal invasion. Cancers other than adenocarcinomas of probable colonic origin were excluded. A total of 17 polyps ≥ 10 mm were excluded from the study because data were missing.

Endoscopic images of all lesions with cancer were reviewed by the senior author (D.K.R.) to determine whether the cancer was evident by endoscopic inspection alone. The endoscopist was blinded to whether the lesion had been resected endoscopically or surgically. Lesions were considered to have endoscopic evidence of cancer if they had areas of overt ulceration or areas of vascular disruption on the lesion surface.

Right colon location was defined as proximal to the splenic flexure (transverse colon, hepatic flexure, ascending colon, and cecum).

Descriptive statistical analysis was performed.

Results

During the study period, a total of 5093 lesions ≥ 10 mm were documented from 4112 endoscopies performed by 48 endoscopists in 4020 patients. The mean age of patients was 63.2 years (range 18–91) and 34.4% of patients were female.

A total of 189 polyps that were not considered conventional adenomas or serrated class lesions were excluded from further analysis. These included inflammatory polyps ($n=98$), granulation tissue ($n=15$), hamartoma ($n=14$), carcinoid tumor ($n=6$),

► **Table 1** Previously reported data on rate of cancer in colorectal polyps ≥ 10 mm.

Study [ref]	Cancer/Total polyps ≥ 10 mm, n (%)	Cancer/Total polyps 10–19 mm, n (%)	Cancer/Total polyps ≥ 20 mm, n (%)
Burnikel et al., 1954 [19]	48/106 (45.3)	31/72 (43.1)	17/34 (50.0)
Wilson et al., 1955 [20]*	–	– (18.0)	– (22.0)
Muto et al., 1975 [2]	253/1010 (25.0)	55/580 (9.5)	198/430 (46.0)
Shinya et al., 1979 [21]	275/4125 (6.7)	125/2738 (4.6)	150/1387 (10.8)
Matek et al., 1985 [22]	80/1277 (6.3)	45/906 (5.0)	35/371 (9.4)
Hermanek et al., 1987 [23]	659/2246 (2.9)	87/1164 (7.5)	572/1082 (52.9)
Pines et al., 1991 [24]	116/441 (26.3)	86/314 (27.4)	30/127 (23.6)
Netzer et al., 1998 [25]	11/65 (16.9)	6/37 (16.2)	5/28 (17.9)
Aldridge et al., 2001 [26]	23/228 (10.1)	13/122 (10.7)	10/106 (9.4)
Fong et al., 2003 [27]	5/70 (7.1)	4/62 (6.5)	1/8 (12.5)
Odom et al., 2005 [18]	22/155 (14.2)	3/124 (2.4)	19/31 (61.3)
Lieberman et al., 2008 [16]	25/1154 (2.2)	16/963 (1.7)	9/191 (4.7)
Zafar et al., 2012 [17]	7/123 (5.7)	2/83 (2.4)	5/40 (12.5)
Gupta et al., 2012 [8]	1/286 (0.3)	0/242 (0)	1/44 (2.3)
Pooled data	1525/11286 (13.5)	473/7407 (6.4)	1052/3879 (27.1)
Our study	138/4904 (2.8)	28/3068 (0.9)	110/1836 (6.0)

* Wilson et al., is excluded from the pooled analysis as the actual numbers were not reported.

metastatic cancer (n=7), granular cell tumor (n=45), neuroendocrine tumor (n=3), and sarcomatoid lesions (n=1) (► Fig. 1).

► **Table 2** shows the lesion size and histology including the prevalence of cancer. Of the lesions included in the study, 3068 (62.6%) were 10–19 mm and 1836 (37.4%) were ≥20 mm. Among the 3068 lesions 10–19 mm in size, there were 1997 (65.1%) conventional adenomas, of which 1547 (77.5%) were tubular adenomas, 421 (21.1%) were tubulovillous adenomas, 4 (0.2%) were villous adenomas, and 25 (1.2%) polyps had cancer. There were 1071 (34.9%) serrated class lesions, of which 389 (36.3%) were sessile serrated polyps, 679 (63.4%) were hyperplastic polyps, and 3 (0.3%) had cancer. Thus, among all 3068 lesions 10–19 mm in size, 28 (0.9%) had cancer.

There was no difference between the prevalence of cancer in lesions of 10–19 mm that were located in the right colon vs. the left colon (14/1813 [0.8%] vs. 14/1255 [1.1%]; $P=0.33$).

Among the 1836 lesions ≥20 mm in size, there were 1487 (81.0%) conventional adenomas, of which 721 (48.5%) were tubular adenomas, 644 (43.3%) were tubulovillous adenomas, 19 (1.3%) were villous adenomas, and 103 lesions (6.9%) had cancer. There were 349 (19.0%) lesions ≥20 mm in size in the serrated class, of which 194 (55.6%) were sessile serrated polyps, 148 (42.4%) were hyperplastic polyps, and 7 (2.0%) had cancer. Among 1836 total lesions ≥20 mm, 110 (6.0%) had cancer. Among 1420 total serrated class lesions and 3484 conventional adenomas ≥10 mm in size, the rate of cancer was 0.7% (10/1420) and 3.7% (128/3484), respectively.

► **Table 3** shows the results of the blinded review of lesion photographs to determine whether cancer was endoscopically evident prior to resection. Among the 28 cancers 10–19 mm in size, 3 had no endoscopic image available. Of the remaining 25 lesions, 13 (52.0%) had endoscopic changes indicating cancer, including ulceration, depression, and vascular disruption (► Fig. 2), and 11 (44.0%) were considered to have no overt endoscopic features of cancer on review. Among 110 cancers ≥20 mm in size, 4 lesions had no endoscopic image available. Of the remaining 106 lesions, 84 (79.2%) were considered to

Lesions ≥ 10 mm identified during colonoscopy between 2001 and 2016: 5093

Lesions that were not considered conventional adenomas or serrated class (n = 189)

- inflammatory polyps (n = 98)
- granular cell tumor (n = 45)
- granulation tissue (n = 15)
- hamartoma (n = 14)
- carcinoid tumor (n = 6)
- metastatic lesions (n = 7)
- neuroendocrine tumor (n = 3)
- sarcomatoid lesions (n = 1)

Final number of lesions included in the study: 4904

► Fig. 1 Study flow diagram.

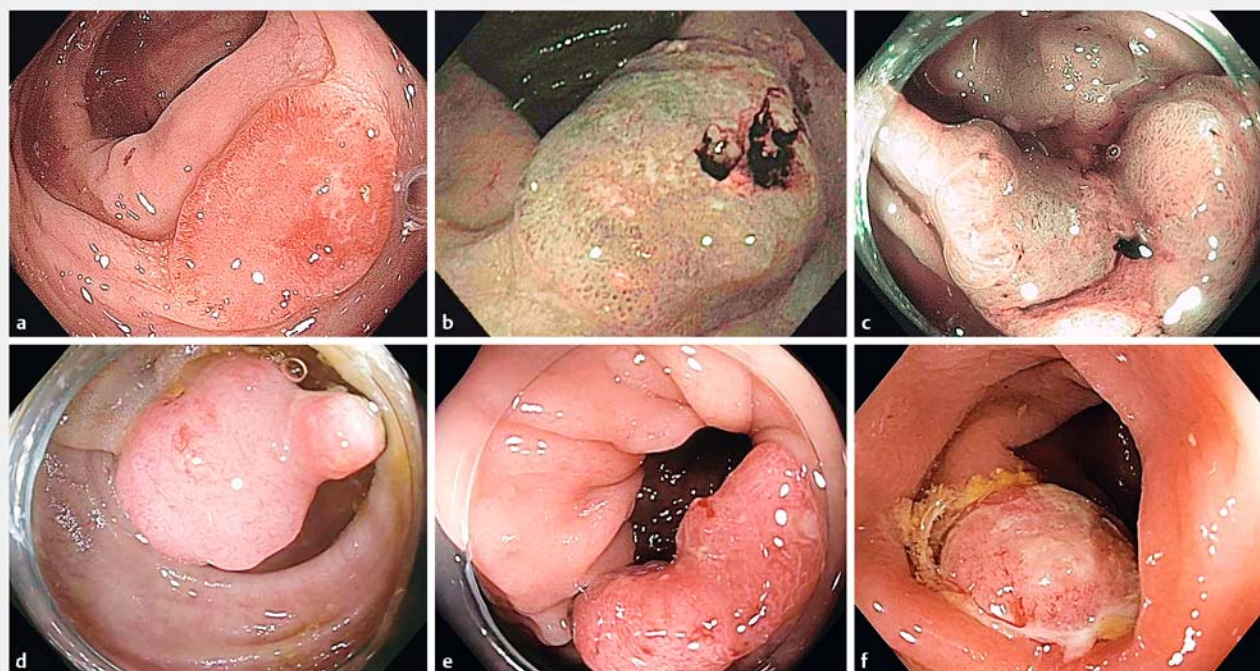
have endoscopic features of cancer on review and 16 (15.1%) did not.

► **Table 4** shows the method of resection for the cancers. In the 10–19 mm sized group, among the 13 lesions that had endoscopic features of cancer on review of photographs (► Fig. 2), 8 (61.5%) were treated by surgery and 5 (38.5%) were resected endoscopically (4 en bloc and 1 piecemeal). In the ≥20 mm group, among the 84 lesions that were endoscopically recognized as cancer on review of photographs, 80 (95.2%) were treated by surgery and 4 (4.8%) were resected endoscopically (all by piecemeal technique). Among the 16 lesions that were not recognized as cancer on review of photographic images, 14 (87.5%) were endoscopically resected and 2 (12.5%) were treated by surgery.

► **Table 2** Prevalence of cancer in colorectal lesions of 10–19 mm in the current study.

Polyp histology, n (%)	Conventional adenomas		Serrated class		Total
	10–19 mm	≥20 mm	10–19 mm	≥20 mm	
Total polyps, n	1997	1487	1071	349	4904
Tubular adenoma	1547 (77.5)	721 (48.5)	–	–	
Tubulovillous adenoma	421 (21.1)	644 (43.3)	–	–	
Villous adenoma	4 (0.2)	19 (1.3)	–	–	
Adenocarcinoma	25 (1.2)	103 (6.9)	3 (0.3)	7 (2.0)	138 (2.8)
Hyperplastic polyp	–	–	679 (63.4)	148 (42.4)	
Sessile serrated polyp	–	–	389 (36.3)	194 (55.6)	
Others*	–	–	–	–	39

* Others include polyps with fragments of both sessile serrated polyp and hyperplastic polyp (n=3), tubular and sessile serrated polyps (n=31), villous and sessile serrated polyps (n=5).



► **Fig. 2** Six representative lesions in the 10–19 mm size range with endoscopic features of cancer on photographic review. **a** 18 mm adenoma with central depression and cancer. **b** 13 mm sessile serrated polyp with central exudate and effacement of pit structure. **c** 19 mm lesion with surface features of adenoma on the right, and ulceration and vascular disruption consistent with cancer on the left. **d** 10 mm lesion with vascular disruption on the surface and a small nodular protrusion. **e** 18 mm adenoma with central depression and vascular disruption. **f** 11 mm sessile adenoma with surface exudate and vascular disruption.

► **Table 3** Endoscopic evidence of cancer based on review of photographs.

	10–19 mm	≥20 mm
Total cancers, n	28	110
Image not available, n (%)	3	4
Cancer likely based on photo, n (%)	13 (52.0)	84 (79.2)
Cancer not evident from photo, n (%)	11 (44.0)	16 (15.1)
Uncertain, n (%)	1 (4.0)	6 (5.7)

Discussion

This is the largest report of the prevalence of cancer in colorectal lesions 10–19 mm in size (► **Table 1**). We found that the prevalence of cancer in colorectal lesions 10–19 mm and ≥20 mm was 0.9% and 6.0%, respectively. The higher cancer rate in lesions ≥20 mm compared with lesions 10–19 mm confirms that the risk of cancer increases with increasing lesion size [1–4]. We reviewed images of malignant lesions for morphological features of cancer, and found that endoscopic features of cancer were present in a higher percentage of lesions ≥20 mm in size compared with lesions of 10–19 mm (79.2% vs. 52.0%). Furthermore, we found a lower prevalence of cancer in serrated class lesions compared with conventional adenomas ≥10 mm in

size (0.7% vs. 3.7%), which was consistent with previous observations [28].

Compared with older reports, we found a lower cancer rate in polyps 10–19 mm in size (► **Table 1**). Prior to the current study, Shinya et al. reported the largest database on the prevalence of cancer in polyps of 10–19 mm, with a cancer rate of 4.6% in 2738 polyps in this size range [21].

The trend toward decreasing rates of cancer in polyps 10–19 mm may reflect the improved imaging capabilities of colonoscopes and an increasing emphasis on identification of flat lesions with a low risk of cancer [12–14]. In addition, our endoscopists have achieved adenoma detection rates (ADRs) well above recommended standards; indeed, the endoscopist with the largest case volume, who performed more than half of the colonoscopies in the unit during the study period, has achieved ADRs of about 50% in multiple previous studies [29–31]. Thus, high ADRs, combined with improved resolution of instruments, are likely to have led to detection of an array of flat and serrated lesions that would have escaped detection by the endoscopists using lower resolution instruments in older studies. Indeed, a trend of declining rates is evident when examining prevalence rates of cancer according to publication dates (► **Table 1**) [2, 8, 16–27].

The strength of our study is the large size, which exceeds that of any previous study on this topic (► **Table 1**). Limitations include the retrospective nature of the study, though the database was accumulated prospectively. Polyp size was estimated

► Table 4 Clinical management (endoscopic vs. surgical resection) vs. blinded review of endoscopic photographs.

Size, mm	Total cancers with available imaging, n*	Cancer, n (%)	Biopsied and sent for surgery, n (%)	Resected by endoscopy, n (%)	Endoscopic resection method, n (%)
10–19	25				
		Evident on photo n = 13	8 (61.5)	5 (38.5)	En bloc: 4 (80) Piecemeal: 1 (20)
		Not evident n = 11	5 (45.5)	6 (54.5)	En bloc 3 (50) Piecemeal 3 (50)
≥20	106				
		Evident on photo n = 84	80 (95.2)	4 (4.8)	En bloc 0 (0) Piecemeal 4 (100)
		Not evident n = 16	2 (12.5)	14 (87.5)	En bloc 0 (0) Piecemeal 14 (100)

* Assessment of the endoscopic images was uncertain regarding features of cancer in 1 lesion 10–19 mm in size and 6 lesions ≥20 mm in size.

endoscopically, which can lead to errors in classification. We reviewed endoscopic images of malignant lesions retrospectively, and the findings of the review were consistent with the surgical vs. endoscopic management utilized at the time of diagnosis. Although pathological definitions of cancer have not changed over the study interval, classification of serrated lesions and awareness of sessile serrated polyps have evolved considerably [28,32]. We have shown with our center that expert pathological review of lesions previously identified as “hyperplastic” frequently results in reclassification of the lesions as sessile serrated polyps. As we did not have the study lesions reviewed by expert pathologists, our data certainly underestimate the fraction of serrated lesions that are sessile serrated polyps and overestimate the fraction that are hyperplastic. However, the prevalence of cancer and the numbers of conventional adenomas vs. lesions in the serrated class should be accurate. Additionally, with regard to histology, during most of the study period, our pathologists did not report certain pathological features that are currently sometimes or always considered informative, such as depth of invasion and the presence or absence of tumor budding. Furthermore, we do not have long term follow-up data on cancer patients in our database. Finally, our center provides some tertiary services. We cannot exclude the possibility that cancers were over- or underrepresented because of referral bias. However, the majority of our cases do not reflect lesions referred for endoscopic resection.

Our results suggest that conventional adenomas are more likely to harbor cancer than serrated lesions of similar size. Serrated lesions have received considerable attention in recent decades and contribute disproportionately to interval cancers [33–34]. However, our data suggest that the risk per individual lesion is higher for conventional adenomas than for serrated lesions.

In conclusion, the prevalence of invasive cancer in colorectal lesions 10–19 mm in size is low at 0.9%, and lower than previously reported. About half of cancers in lesions of 10–19 mm are evident based on endoscopic features prior to resection, and cancer is less likely to be endoscopically evident compared

with lesions ≥20 mm. Among all lesions ≥10 mm, cancer is more common in conventional adenomas than in serrated lesions of similar size.

Acknowledgment

This work was supported by a grant from Scott Schurz and his children of Bloomington, IN, to the Indiana University foundation in the name of Douglas K. Rex.

Competing interests

Dr. Rex is a consultant for Olympus Corp., Medtronic and Aries. He has consultancy and research support links with Boston Scientific and research support links with EndoAid, Olympus Corporation and Medivators. Ownership: Satis Corporation.

References

- [1] Kristjansson S, Jonasson JG, Cariglia N et al. Colonic adenomas found via colonoscopy: yield and risk factors for high-grade dysplasia. *Digestion* 2010; 82: 252–257
- [2] Muto T, Bussey HJ, Morson BC. The evolution of cancer of the colon and rectum. *Cancer* 1975; 36: 2251–2270
- [3] Kronborg O, Fenger C. Clinical evidence for the adenoma-carcinoma sequence. *Eur J Cancer Prev* 1999; 8: S73–86
- [4] Peipins LA, Sandler RS. Epidemiology of colorectal adenomas. *Epidemiol Rev* 1994; 16: 273–297
- [5] Butterly LF, Chase MP, Pohl H et al. Prevalence of clinically important histology in small adenomas. *Clin Gastroenterol Hepatol* 2006; 4: 343–348
- [6] Yoo TW, Park DI, Kim YH et al. Clinical significance of small colorectal adenoma less than 10 mm: the KASID study. *Hepatogastroenterology* 2007; 54: 418–421
- [7] Ponugoti PL, Cummings OW, Rex DK. Risk of cancer in small and diminutive colorectal polyps. *Dig Liver Dis* 2017; 49: 34–37
- [8] Gupta N, Bansal A, Rao D et al. Prevalence of advanced histological features in diminutive and small colon polyps. *Gastrointest Endosc* 2012; 75: 1022–1030

- [9] Denis B, Bottlaender J, Weiss AM et al. Some diminutive colorectal polyps can be removed and discarded without pathologic examination. *Endoscopy* 2011; 43: 81–86
- [10] Tsai FC, Strum WB. Prevalence of advanced adenomas in small and diminutive colon polyps using direct measurement of size. *Dig Dis Sci* 2011; 56: 2384–2388
- [11] Chaput U, Alberto SF, Terris B et al. Risk factors for advanced adenomas amongst small and diminutive colorectal polyps: a prospective monocenter study. *Dig Liver Dis* 2011; 43: 609–612
- [12] Kudo S, Lambert R, Allen JI et al. Nonpolypoid neoplastic lesions of the colorectal mucosa. *Gastrointest Endosc* 2008; 68: (Suppl. 04): S3–47
- [13] Bianco MA, Cipolletta L, Rotondano G et al. Prevalence of nonpolypoid colorectal neoplasia: an Italian multicenter observational study. *Endoscopy* 2010; 42: 279–285
- [14] Tsuda S, Veress B, Toth E et al. Flat and depressed colorectal tumours in southern Swedish population: a prospective chromoendoscopic and histopathological study. *Gut* 2002; 51: 550–555
- [15] Ferlitsch M, Moss A, Hassan C et al. Colorectal polypectomy and endoscopic mucosal resection (EMR): European Society of Gastrointestinal Endoscopy (ESGE) Clinical Guideline. *Endoscopy* 2017; 49: 270–297
- [16] Lieberman D, Moravec M, Holub J et al. Polyp size and advanced histology in patients undergoing colonoscopy screening: implications for CT colonography. *Gastroenterology* 2008; 135: 1100–1105
- [17] Zafar A, Mustafa M, Chapman M. Colorectal polyps: when should we tattoo? *Surg Endosc* 2012; 26: 3264–3266
- [18] Odom SR, Duffy SD, Barone JE et al. The rate of adenocarcinoma in endoscopically removed colorectal polyps. *Am Surg* 2005; 71: 1024–1026
- [19] Burnikel RH, Schutte AG. Adenomatous polyps of the rectum and distal sigmoid; a statistical analysis of 500 patients with polyps. *Am J Surg* 1954; 88: 378–383
- [20] Wilson GS, Dale EH, Brines OA. An evaluation of polyps detected in 20,847 routine sigmoidoscopic examinations. *Am J Surg* 1955; 90: 834–840
- [21] Shinya H, Wolff WJ. Morphology, anatomic distribution and cancer potential of colonic polyps. *Ann Surg* 1979; 190: 679–683
- [22] Matek W, Guggenmoos-Holzmann I, Demling L. Follow-up of patients with colorectal adenomas. *Endoscopy* 1985; 17: 175–181
- [23] Hermanek P. Dysplasia-carcinoma sequence, types of adenomas and early colo-rectal carcinoma. *Eur J Surg Oncol* 1987; 13: 141–143
- [24] Pines A, Bat L, Shemesh E et al. Clustering of colorectal neoplasia: characteristics of coexisting adenomas in patients with severely dysplastic polyps or invasive (malignant) polyps as compared to patients with benign adenomas or carcinomas. *Postgrad Med J* 1991; 67: 760–763
- [25] Netzer P, Forster C, Biral R et al. Risk factor assessment of endoscopically removed malignant colorectal polyps. *Gut* 1998; 43: 669–674
- [26] Aldridge AJ, Simson JN. Histological assessment of colorectal adenomas by size Are polyps less than 10 mm in size clinically important? *Eur J Surg* 2001; 167: 777–781
- [27] Fong TV, Chuah SK, Chiou SS et al. Correlation of the morphology and size of colonic polyps with their histology. *Chang Gung Med J* 2003; 26: 339–343
- [28] Rex DK, Ahnen DJ, Baron JA et al. Serrated lesions of the colorectum: review and recommendations from an expert panel. *Am J Gastroenterol* 2012; 107: 1315–1329
- [29] Rex DK, Helbig CC. High yields of small and flat adenomas with high-definition colonoscopes using either white light or narrow band imaging. *Gastroenterology* 2007; 133: 42–47
- [30] Kahi C, Anderson J, Waxman I et al. The American College of Gastroenterology high definition chromocolonoscopy study: findings and implications of colorectal cancer screening. *Am J Gastroenterol* 2009; 104: S559
- [31] Rex DK, Hardacker K, MacPhail M et al. Determining the adenoma detection rate and adenomas per colonoscopy by photography alone: proof-of-concept study. *Endoscopy* 2015; 47: 245–250
- [32] Hetzel J, Huang CS, Coukos JA et al. Variation in the detection of serrated polyps in an average risk colorectal cancer screening cohort. *Am J Gastroenterol* 2010; 105: 2656–2664
- [33] Arain MA, Sawhney M, Sheikh S et al. CIMP status of interval colon cancers: another piece to the puzzle. *Am J Gastroenterol* 2010; 105: 1189–1195
- [34] Sawhney MS, Farrar WD, Gudiseva S et al. Microsatellite instability in interval colon cancers. *Gastroenterology* 2006; 131: 1700–1705