

Salvage nitrous oxide cryotherapy of refractory colon neoplasia embedded within an endoclip



Authors

Arvind J. Trindade, Petros C. Benias, Maurice A. Cerulli

Institution

Zucker School of Medicine at Hofstra/Northwell, Northwell Health System, Division of Gastroenterology, Long Island Jewish Medical Center, New Hyde Park, New York, United States

submitted 5.8.2018

accepted after revision 24.9.2018

Bibliography

DOI <https://doi.org/10.1055/a-0777-2240> |

Endoscopy International Open 2018; 06: E1410–E1412

© Georg Thieme Verlag KG Stuttgart · New York

ISSN 2364-3722

Corresponding author

Arvind J. Trindade, MD, Director of Endoscopy, Zucker School of Medicine at Hofstra/Northwell, Long Island Jewish Medical Center, Northwell Health System, Division of

Gastroenterology, 270-05 76th Avenue, New Hyde Park, NY 11040

Fax: +1-718-470-5509

arvind.trindade@gmail.com

ABSTRACT

Background and study aims This is a case report on use of the CryoBalloon as a salvage technique for ablation of residual neoplasia at an endoscopic mucosal resection site. The site contained an embedded clip that could not be removed at two different sessions by three experienced endoscopists. On follow-up endoscopy, the clips and residual polyp no longer remained. The subtle scar that was present was biopsied and confirmed complete eradication of neoplasia and no polyp tissue. This case shows the potential of the CryoBalloon to ablate unwanted tissue outside of the esophagus.

Case report

A 59-year-old-male underwent an endoscopic mucosal resection (EMR) of a 4-cm cecum polyp 1 year earlier. At that time, the patient had three endo-clips placed to close the EMR defect that was created. The pathology from the EMR was a tubulovillous adenoma. The patient was lost to follow-up but returned 1 year later for endoscopic follow-up. At the site, a previously placed endoclip was present, with residual polyp tissue embedded at the site. Attempted removal of the clip by an experienced senior gastroenterologist with a snare was unsuccessful. Biopsy of the polyp showed high-grade dysplasia.

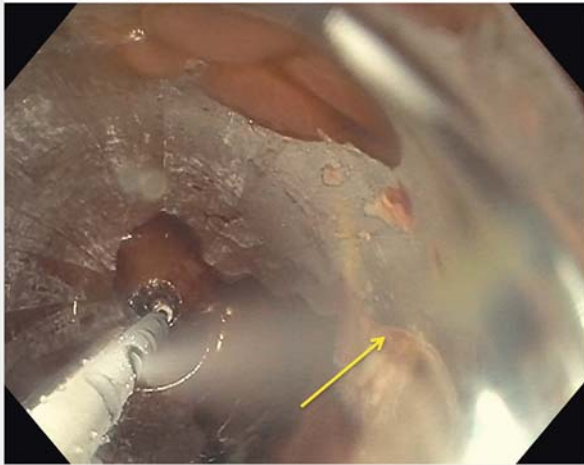
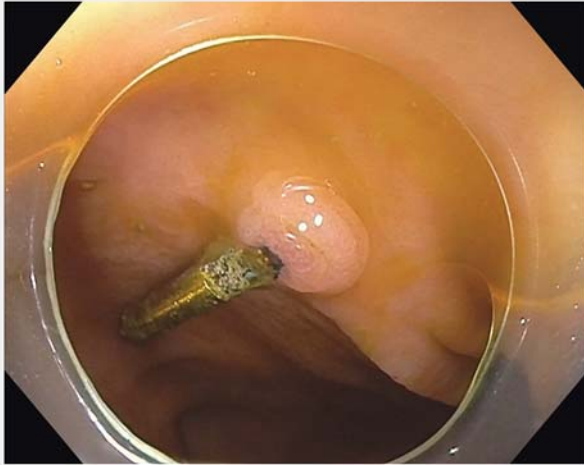
The patient refused surgery and thus a repeat colonoscopy was performed by an interventional endoscopist. The clip was in place and residual neoplasia was seen in the cecum (► Fig. 1a). Repeat attempts by two advanced endoscopists to remove the clip using a snare and grasper were unsuccessful, as the clip was deeply embedded in the tissue. The polyp was injected but a submucosal lift could not be obtained. Snare cautery removal was not attempted for fear of possible perforation because thermal injury to the cecum wall was a possibility. The decision was made to perform salvage nitrous oxide balloon-

based cryotherapy (C2 Therapeutics, Redwood City, California, United States). It is non-thermal and the balloon self-vents excess gas to avoid perforation.

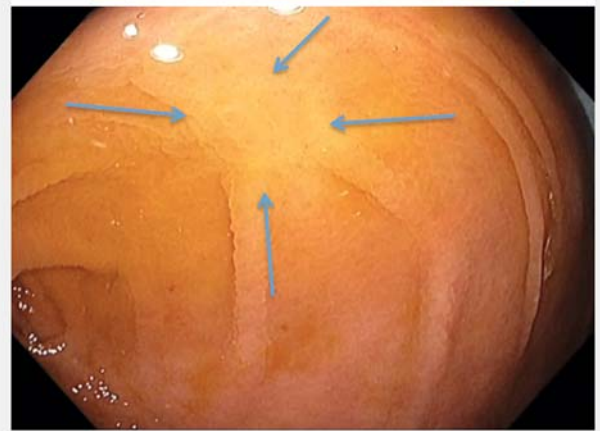
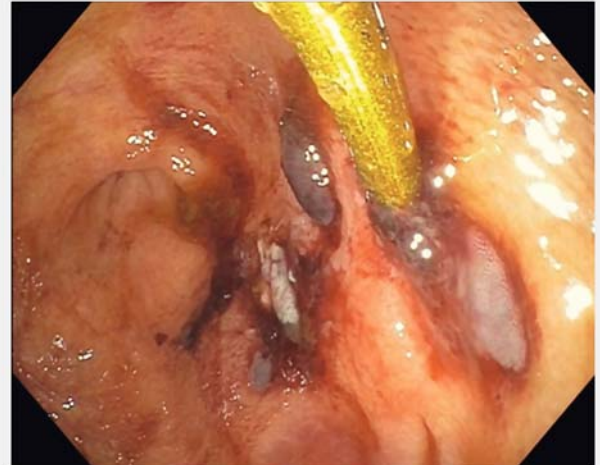
A therapeutic gastroscope was used for the procedure. The CryoBalloon was able to appose the residual polyp and clip. A dosimetry of 10 seconds was used to ablate the residual neoplasia (► Fig. 1b). Immediately after the cryotherapy, the area was erythematous consistent with post-ablation effects (► Fig. 2a). On 2-month follow-up, the cecum was free of the polyp and clip (► Fig. 2b). There was a subtle scar that could be seen (► Fig. 2b, blue arrows). The clip had previously been in place for 1 year and could not be removed by multiple endoscopists. However, the CryoBalloon ablation was successful in removing the clip and eradicating the residual neoplasia. Biopsies of the scar were negative for residual polyp tissue.

Discussion

This case shows that cryotherapy can be used to ablate unwanted tissue in the colon. The vast majority of the literature for use of the CryoBalloon has been for ablation of unwanted esophageal tissue, specifically Barrett's esophagus and esopha-



► **Fig. 1** **a** Residual polyp from a prior endoscopic mucosal resection, seen embedded within an endoclip at the cecum. **b** Balloon-based cryotherapy being performed as a salvage technique to ablate the residual neoplasia. The yellow arrow is pointing to the endoclip.



► **Fig. 2** **a** Residual neoplasia site post cryotherapy. **b** Follow-up colonoscopy 2 months after cryotherapy showing the cecum is free of polyp and the endo-clip. The arrows point to the subtle scar at the prior polyp site.

geal squamous dysplasia. A multicenter, prospective non-randomized trial of 39 patients with Barrett's esophagus dysplasia showed the device was feasible and safe [1]. In a different prospective trial, 41 patients (22 treatment-naïve) with Barrett's esophagus dysplasia were treated with the CryoBalloon [2]. At 1 year, rates of complete eradication of dysplasia and intestinal metaplasia rates were 95% and 88%, respectively. A multicenter trial currently of more than 100 treatment-naïve patients with Barrett's esophagus dysplasia who underwent CryoBalloon therapy currently is nearing completion.

The CryoBalloon has also been evaluated for treatment of esophageal squamous neoplasia. In a retrospective study of 10 patients, the device was used for ablation [3]. At 3 months follow-up, complete eradication was observed in all patients. Results from a large Asian prospective trial are anticipated in manuscript form soon. The abstract presented at Digestive Disease Week 2018 showed the CryoBalloon was well tolerated and highly effective [4].

The CryoBalloon has been used outside the esophagus in the stomach for ablation of gastric antral vascular ectasia (GAVE) [5]. In a multicenter retrospective study of 23 patients with GAVE refractory to argon plasma coagulation, the CryoBalloon was highly effective [6]. At 6 months, 83% of patients were transfusion-independent and 87% had more than 75% of the GAVE successfully eradicated.

This is the first report of use of the CryoBalloon in the colon. The main limitation of this case is that usually endoclips can be easily removed, and this was the reason for the difficulty in eradicating the residual neoplasia. However, this clip was unusual in that it remained for more than a year and thus was likely deeply embedded. In addition a senior gastroenterologist and two additional interventional endoscopists could not remove this clip despite exhaustive attempts.

It should be noted that the CryoBalloon can only be used with a therapeutic gastroscope, which limits its applications in the colon. However in our experience, especially with difficult colonoscopy, the vast majority of the colon can be examined with a gastroscope [7]. Large feasibility and safety studies are

needed prior to endorsing its routine use in the colon. However, this case shows that this is a viable salvage technique for use in the colon when standard techniques fail.

Competing interests

Dr Trindade is a consultant for C2 Therapeutics.

References

- [1] Schölvinck DW, Künzli HT, Kestens C et al. Treatment of Barrett's esophagus with a novel focal cryoablation device: a safety and feasibility study. *Endoscopy* 2015; 47: 1106–1112
- [2] Canto MI, Shaheen NJ, Almario JA et al. Multifocal nitrous oxide cryoballoon ablation with or without EMR for treatment of neoplastic Barrett's esophagus (with video). *Gastrointest Endosc* 2018; 88: 438–446.e2
- [3] Canto MI, Abrams JA, Künzli HT et al. Nitrous oxide cryotherapy for treatment of esophageal squamous cell neoplasia: initial multicenter international experience with a novel portable cryoballoon ablation system (with video). *Gastrointest Endosc* 2018; 87: 574–581
- [4] Ke Y, van Munster SN, Chen J et al. Endoscopic cryoballoon ablation is safe, well-tolerated and highly effective in the eradication of esophageal squamous cell neoplasia. *Gastrointest Endosc* 2018; 87: AB141–AB142
- [5] Trindade AJ, Inamdar S, Sejjal DV. Nitrous oxide CryoBalloon therapy of refractory gastric antral vascular ectasia. *Endoscopy* 2017; 49: 923–924
- [6] Patel AA, Trindade AJ, Diehl DL et al. Nitrous oxide cryotherapy ablation for refractory gastric antral vascular ectasia. *United Eur Gastroenterol J* 2018; 6: 1155–1160
- [7] Trindade AJ, Lichtenstein DR, Aslanian HR et al. Devices and methods to improve colonoscopy completion (with videos). *Gastrointest Endosc* 2018; 87: 625–634