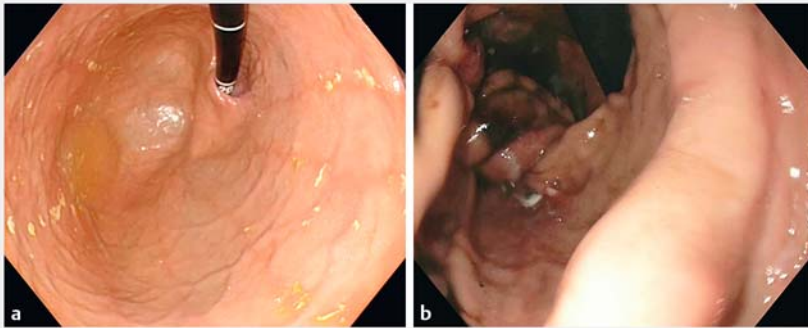
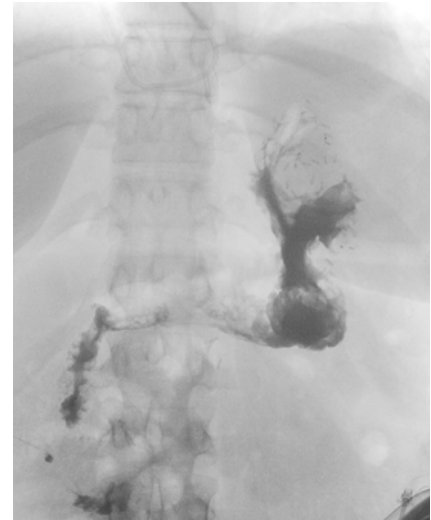


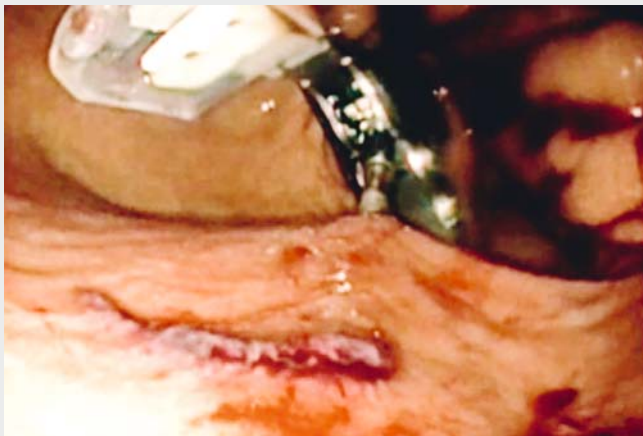
## Endoscopic sleeve gastropasty for severe obesity by full-thickness suturing using the GERDX device



► **Fig. 1** Endoscopic view of the stomach before and after the application of 18 transmurals sutures using the GERDX device (G-Surg GmbH, Seon-Seebruck, Germany), showing the reduction in gastric volume. **a** Before the procedure. **b** After the procedure.



► **Fig. 2** Contrast swallow two days after endoscopic sleeve gastropasty, confirming the sleeve configuration of the stomach and showing no signs of perforation.



► **Video 1** A new treatment option for obesity. Use of the GERDX device (G-Surg GmbH, Seon-Seebruck, Germany) for application of transmurals sutures in the stomach in order to perform endoscopic sleeve gastropasty.

Obesity is an increasing health problem worldwide. Endoscopic therapies have emerged as treatment option in addition to lifestyle modification and bariatric surgery. One possible endoscopic approach is to reduce the size of the stomach [1, 2]. This approach has been demonstrated to be feasible and efficient using different endoscopic suturing devices [3,4]. The GERDX device (G-Surg GmbH, Seon-

Seebruck, Germany) allows full-thickness suturing in the upper gastrointestinal tract and was originally used for endoscopic antireflux therapy [5]. The transmurals sutures have proven to be durable and to remain in situ even after long follow-up.

In this 41-year old woman, who suffered from severe obesity (168 cm, 121 kg, body mass index [BMI] 42.9 kg/m<sup>2</sup>), we

aimed to use the GERDX device to perform an endoscopic sleeve gastropasty. The device was inserted into the stomach and an ultraslim endoscope was introduced through the device's working channel to provide visualization. Next, the gastric wall was retracted with a tissue retractor and the full-thickness suture was applied. This was repeated 18 times from the fundus to the distal corpus (► **Video 1**). This resulted in a markedly reduced stomach volume.

The procedure was performed under general anesthesia and peri-interventional antibiotic therapy was initiated. The gastric volume reduction was successfully performed using the GERDX device (► **Fig. 1**) and no procedure-related complications occurred.

The next day a control endoscopy was performed, which confirmed the volume reduction and showed no signs of bleeding or perforation. A contrast swallow test confirmed the sleeve configuration of the stomach (► **Fig. 2**). A normal diet was resumed within days and the patient

was discharged on Day 5 without any further complications.

After 8 weeks, the patient had lost 12 kg of weight, resulting in a change in BMI of  $-4.3 \text{ kg/m}^2$  or a percent excess weight loss of 24.0%.

Endoscopic sleeve gastroplasty using the GERDX device was feasible, safe, and efficient in this patient. This technique could potentially emerge as a minimally invasive treatment for obesity.

Endoscopy\_UCTN\_Code\_TTT\_1AO\_2AJ

### Competing interests

None

### The authors

**Andreas Wannhoff<sup>1</sup>, Christopher Hofmann<sup>1</sup>, Benjamin Meier<sup>1</sup>, Dieter Birk<sup>2</sup>, Karel Caca<sup>1</sup>**

1 Internal Medicine I, Klinikum Ludwigsburg, Ludwigsburg Germany

2 Department of General and Visceral Surgery, Krankenhaus Bietigheim, Bietigheim-Bissingen, Germany

### Corresponding author

**Karel Caca, MD**

Internal Medicine I, Klinikum Ludwigsburg,  
Posilipostrasse 4, 71640 Ludwigsburg,  
Germany  
Fax: +49-7141-9967219  
Karel.Caca@kliniken-lb.de

### References

- [1] Kumar N. Endoscopic therapy for weight loss: gastroplasty, duodenal sleeves, intra-gastric balloons, and aspiration. *World J Gastrointest Endosc* 2015; 7: 847–859
- [2] ASGE Bariatric Endoscopy Task Force; ASGE Technology Committee, Abu Dayyeh BK et al. Endoscopic bariatric therapies. *Gastrointest Endosc* 2015; 81: 1073–1086
- [3] Sharaiha RZ, Kedia P, Kumta N et al. Initial experience with endoscopic sleeve gastroplasty: technical success and reproducibility in the bariatric population. *Endoscopy* 2015; 47: 164–166
- [4] Espinos JC, Turro R, Mata A et al. Early experience with the Incisionless Operating Platform (IOP) for the treatment of obesity: the Primary Obesity Surgery Endolumenal (POSE) procedure. *Obes Surg* 2013; 23: 1375–1383
- [5] von Renteln D, Schiefke I, Fuchs KH et al. Endoscopic full-thickness plication for the treatment of GERD by application of multiple Plicator implants: a multicenter study (with video). *Gastrointest Endosc* 2008; 68: 833–844

### Bibliography

DOI <https://doi.org/10.1055/a-0756-7921>

Published online: 11.12.2018

*Endoscopy* 2019; 51: E34–E35

© Georg Thieme Verlag KG

Stuttgart · New York

ISSN 0013-726X

### ENDOSCOPY E-VIDEOS

<https://eref.thieme.de/e-videos>



*Endoscopy E-Videos* is a free access online section, reporting on interesting cases and new

techniques in gastroenterological endoscopy. All papers include a high quality video and all contributions are freely accessible online.

This section has its own submission website at

<https://mc.manuscriptcentral.com/e-videos>