Thieme

Endoscopic management of stent displacement after pancreatic pseudocyst drainage

A 50-year-old man who had experienced acute alcoholic pancreatitis 2 years earlier presented with abdominal pain. An abdominal computed tomography (CT) scan revealed a pseudocyst, 16 × 8 cm in size, in the pancreatic tail (▶ **Fig. 1**). After multidisciplinary discussion, the patient was referred for endoscopic pseudocyst drainage.

Transgastric puncture of the pseudocyst was performed using a 19-gauge fine-needle aspiration needle, under endoscopic ultrasound (EUS) guidance. A 0.035-inch guidewire was advanced through the needle and the tract was dilated to 6 mm. A fully covered double-flanged metal stent (40 × 14 mm) was then deployed across the tract under endoscopic, EUS, and fluoroscopic guidance. The deployment was complicated by complete intracystic migration of the stent. We decided to place a fully covered biliary metal stent (60 × 10 mm) in an attempt to save the performed cystogastrostomy, and planned to retrieve the migrated stent at a later time. The patient was discharged with no symptoms.

The patient was readmitted to our department 1 week later with fever and upper abdominal pain. Abdominal CT scan showed complete migration of the two stents into the pseudocyst cavity (12 × 6 cm) (▶ **Fig. 2**).

Under endoscopic, EUS, and fluoroscopic guidance, we placed another fully covered double-flanged metal stent (40 × 14 mm) through the patent cystogastrostomy (▶ **Fig. 3**). The two intracystic migrated stents were then removed through the third stent using a foreign body forceps. Effective drainage of the pseudocyst was observed and the patient became asymptomatic (▶ **Video 1**).

At follow-up 1 month later, after an abdominal CT scan showed complete resolution of the pseudocyst (▶ **Fig. 4**), the stent was removed endoscopically (▶ **Fig. 5**).

▶ **Video 1** Endoscopic management of stent displacement after pancreatic pseudocyst drainage. 1) View of the intragastric portion of double-flanged metal stent. 2) Access to the cystic cavity through the double-flanged metal stent. 3) View of the two intracystic migrated stents. 4) Removal of the biliary and double-flanged metal stents.

▶ **Fig. 1** Abdominal computed tomography scan showing a well-defined cystic lesion (arrow), 16 × 8 cm in diameter, in the tail of the pancreas.

This document was downloaded for personal use only. Unauthorized distribution is strictly prohibited.

▶ **Fig. 2** Abdominal computed tomography scan in axial view showing complete migration of the first two stents into the pseudocyst cavity.

▶ **Fig. 3** Fluoroscopic image showing the third stent through the cystogastrostomy and the first two stents in the pseudocyst cavity.

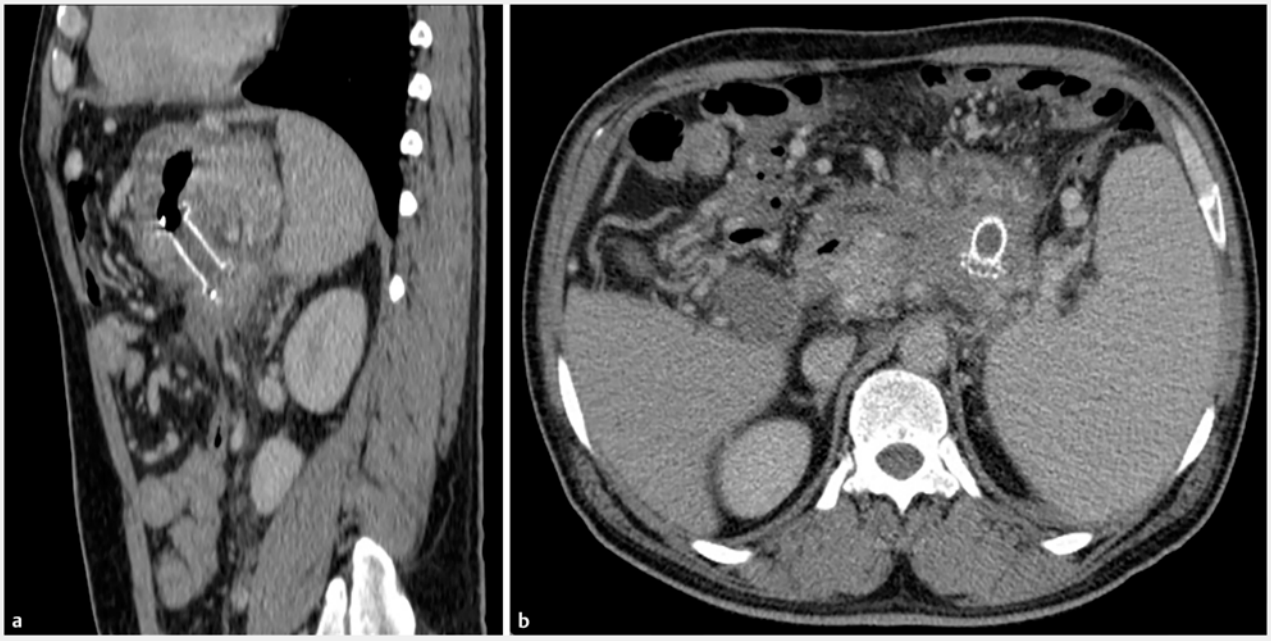

▶ **Fig. 4** Abdominal computed tomography scan. **a** Coronal view, showing a correctly positioned fully covered double-flanged metal stent. **b** Axial view, showing complete resolution of the pancreatic pseudocyst.

This document was downloaded for personal use only. Unauthorized distribution is strictly prohibited.

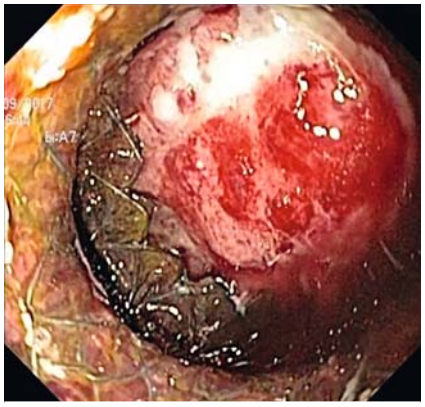

▶ **Fig. 5** Endoscopy image showing collapsed perigastric cavity consistent with complete resolution of the pseudocyst.

Intracystic stent migration is a rare (< 1 %) complication of endoscopic drainage. It seems to be more frequent in transgastric drainage of pseudocysts of the pancreatic tail owing to variable luminal compression during the creation of cystogastrostomy [1].

We propose an alternative endoscopic method to solve intracystic stent migration, avoiding surgery [2].

Endoscopy_UCTN_Code_CPL_1AK_2AG

Competing interests

None

The authors

Juliana M. Costa[1], Bruno M. Gonçalves[1], Rita S. Costa[1], Filipa Costeira[2], Nuno Dias[1], Raquel Gonçalves[1], João B. Soares[1]

1 Department of Gastroenterology, Hospital de Braga, Braga, Portugal

2 Department of Radiology, Hospital de Braga, Braga, Portugal

Corresponding author

Juliana M. Costa, MD
Gastroenterology Department, Hospital de Braga, Sete Fontes – São Victor, 4710-243 Braga, Portugal
Fax: +35-253-027999
julianamcosta87@gmail.com

References

[1] Varadarajulu S, Christein JD, Wilcox CM. Frequency of complications during EUS-guided drainage of pancreatic fluid collections in 148 consecutive patients. J Gastroenterol Hepatol 2011; 26: 1504 – 1508

[2] Wang GX, Liu X, Wang S et al. Stent displacement in endoscopic pancreatic pseudocyst drainage and endoscopic management. World J Gastroenterol 2015; 21: 2249 – 2253

Bibliography
DOI https://doi.org/10.1055/a-0655-1912
Published online: 8.8.2018
Endoscopy 2018; 50: E304–E306
© Georg Thieme Verlag KG
Stuttgart · New York
ISSN 0013-726X

ENDOSCOPY E-VIDEOS
https://eref.thieme.de/e-videos

Endoscopy E-Videos is a free access online section, reporting on interesting cases and new techniques in gastroenterological endoscopy. All papers include a high quality video and all contributions are freely accessible online.

This section has its own submission website at https://mc.manuscriptcentral.com/e-videos

This document was downloaded for personal use only. Unauthorized distribution is strictly prohibited.