

Insertability comparison of passive bending single-balloon prototype versus standard single-balloon enteroscopy: a multicenter randomized non-blinded trial ▶

OPEN
ACCESS

Authors

Naoki Hosoe¹, Kazuo Ohtsuka^{2,3}, Yutaka Endo⁴, Makoto Naganuma⁵, Noriyuki Ogata², Yuichiro Kuroki⁶, Seiko Sasanuma², Kaoru Takabayashi¹, Shin-Ei Kudo², Hiroshi Takahashi⁶, Haruhiko Ogata¹, Takanori Kanai⁵

Institutions

- 1 Center for Diagnostic and Therapeutic Endoscopy, School of Medicine, Keio University, Tokyo, Japan
- 2 Digestive Disease Center, Showa University Northern Yokohama Hospital, Yokohama, Japan
- 3 Departments of Endoscopy, Tokyo Medical and Dental University, Tokyo, Japan
- 4 Center for Gastroenterology and Inflammatory Bowel Disease, Ofuna Chuo Hospital, Kamakura, Japan
- 5 Division of Gastroenterology and Hepatology, Department of Internal Medicine, School of Medicine, Keio University, Tokyo, Japan
- 6 Department of Gastroenterology, Fujigaoka Hospital, Showa University, Yokohama, Japan

submitted 1.1.2018

accepted after revision 9.5.2018

Bibliography

DOI <https://doi.org/10.1055/a-0650-4168> |
Endoscopy International Open 2018; 06: E1184–E1189
© Georg Thieme Verlag KG Stuttgart · New York
ISSN 2364-3722

Corresponding author

Naoki Hosoe, MD, PhD, Center for Diagnostic and Therapeutic Endoscopy, School of Medicine, Keio University, 35 Shinanomachi, Shinjuku, Tokyo 160-8582, Japan
Fax: +81-3-3357-2778
nhosoe@keio.jp

ABSTRACT

Background and study aims Traversing the ileocecal valve (ICV) is technically challenging with a retrograde approach to single-balloon enteroscopy (SBE). A novel technique called responsive insertion technology (RIT) colonoscopy was developed to obtain a higher cecal intubation rate in this setting. A prototype long SBE equipped with RIT (P-SBE) was developed to obtain superior insertability. The aim of this study was to compare the insertability of a standard single-balloon enteroscope (S-SBE) versus a P-SBE.

Patients and methods This study was a multicenter, randomized, non-blinded, trial of 62 patients with small bowel pathologies. All procedures were performed with SBE via the trans-anal route. Procedure success was defined as stable intubation of the terminal ileum (TI) 20 cm beyond the ICV. The primary variable was time to reach stable TI intubation 20 cm beyond the ICV (TSTII). If stable TI intubation was not achieved within 10 minutes, the initial SBE was removed through the indwelling overtube and replaced with another SBE.

Results Sixty patients were examined with two patients excluded from this study. TSTII using P-SBE was significantly decreased compared to S-SBE (mean P-SBE vs S-SBE: 98.3 vs 169.4 second, $P=0.006$). The completion rates for stable intubation within 10 minutes of using P-SBE and S-SBE were 96.8% and 86.2%, respectively ($P=0.19$). On endoscope replacement, all patients had achieved stable TI intubation.

Conclusions SBE with RIT improves insertability when traversing the ileocecal valve in retrograde SBE.

Introduction

Double-balloon enteroscopy (DBE) has been shedding light on the dark small intestine since 2001 [1]. After developing DBE, single-balloon enteroscopy (SBE) was subsequently introduced for investigation and treatment of small bowel pathologies [2, 3]. The retrograde approach to balloon-assisted enteroscopy (BAE) is technically difficult because of the length and tortuos-

ity of the colon and the need to traverse the ileocecal valve (ICV) with sharp angulation [4, 5].

Two novel techniques for responsive insertion technology (RIT) colonoscopy have been developed to obtain a higher cecal intubation rate [6]. The first technique, called passive bending, aims to improve insertion through sharp flexure in the colon. The second technique utilizes a high force transmission insertion tube, enabling the endoscopist to manipulate the proximal

control force that efficiently transfers torque and lateral forces along the distal end of the insertion tube, even when angulated. Several clinical trials have compared patient tolerability and insertability of a standard colonoscope versus a colonoscope with RIT (XCF-Q160AW prototype, XCF-Q180AY2L, PCF-Y0014-L, PCF-PQ260L; Olympus Medical Systems, Tokyo, Japan) [7–11]. These reports concluded that use of a colonoscope with RIT significantly reduced patient pain; however, the cecal intubation rate and time to cecum were equivalent to those for a standard colonoscope [7, 8, 10, 11]. One comparative study conducted by Sato et al reported that use of a colonoscope with RIT increased cecal intubation and lesion detection rates and decreased pain severity in patients with incomplete colonoscopy (CS) due to sharp angulations, loop formation, or pain [9].

Recently, short-type SBE (SIF-Y0004-V01, SIF-H290S; Olympus Medical Systems, Tokyo, Japan) has been developed and is used to perform endoscopic retrograde cholangiopancreatography (ERCP) in patients with surgically altered gastrointestinal anatomy. In performing ERCP in postoperative patients, adhesions and sharp bends at anastomoses have been known to impede endoscope progression. To overcome these issues, short-type SBE equipped with RIT has been developed [12, 13].

We hypothesized that RIT may improve insertability even in the setting of conventional SBE. We present experience with the long SBE prototype equipped with RIT developed by Olympus (SIF-Y0002; Olympus Medical Systems, Tokyo, Japan).

The aim of this study was to compare insertability of a standard SBE versus a newly developed prototype long SBE equipped with a passive bending, high force transmission insertion tube.

Patients and methods

Study design

Three institutions (Keio University Hospital, Showa University Northern Yokohama Hospital and Showa University Fujigaoka Hospital) participated in a multicenter, randomized, non-blinded, controlled trial. The study was carried out in accordance with approval of the ethics committee of each institution. This study was registered through the registries approved by the International Committee of Medical Journal Editors (UMIN000007851). Written informed consent was obtained from all patients. Patient enrollment began in May 2012 and was completed in June 2013.

Eligible inclusion criteria consisted of patients requiring retrograde enteroscopy age 20 or older at the time of enrollment. Exclusion criteria included post-ileoceleal resection, known ileocecal valve stenosis, and severe inflammation of the ileocecal region. All SBE procedures were performed by expert endoscopists (NH, KO, YE, MN, NO, YK, SS) who had each performed more than 100 retrograde SBE procedures. All endoscopists performed more than 10 retrograde enteroscopies by using prototype long SBE (P-SBE) as initial training prior to the study. All endoscopists were not blinded to the applicable SBE and patient backgrounds. Randomization was carried out using a sealed opaque envelope method, and examinations were randomly assigned to either the P-SBE or standard SBE (S-SBE)

group. Three sets of sealed envelopes were prepared and randomization was completed for each facility.

Prototype SBE and SBE procedure

The only difference between P-SBE and S-SBE was presence or absence of RIT. Both used the same sliding tube with a balloon (ST-SB1; Olympus), and a balloon control unit [2, 3]. All patients ingested adequate polyethylene glycol (PEG) solution. PEG solution (NIFLEC, Ajinomoto Pharmaceuticals Co. Ltd., Tokyo, Japan) was taken orally at a rate of approximately 1 L per hour, beginning approximately 4 hours prior to the procedure (maximum 4 L of PEG total). All patients were sedated with pethidine hydrochloride (50 mg) and midazolam (2–8 mg) or flunitrazepam (0.2–0.6 mg), with vital signs intermittently monitored during the procedure. To prevent bowel spasms, the antispasmodic agent scopolamine butylbromide (20 mg) or glucagon (1 mg) was administered intravenously during the examination. CO₂ insufflation was used for all examinations. The procedures were performed utilizing an allocated SBE via the trans-anal route.

In this study, procedure success was defined as stable intubation of the terminal ileum (TI) 20 cm beyond the ICV [5], and its primary variable was the time to stable TI intubation 20 cm beyond the ICV. Time to stable TI intubation was defined as the time interval between approaching the ICV and achieving stable TI intubation 20 cm beyond the ICV confirmed by endoscopic progression and fluoroscopy. When stable TI intubation could not be achieved within 10 minutes of using the initial allocated SBE, it was removed through the indwelling overtube with its balloon inflated at the cecum and subsequently replaced by another SBE with time to stable TI intubation measured accordingly. In these patients, stable TI intubation time was limited to 10 minutes, and subsequent procedures were performed with another SBE. These patients were excluded in the analysis of stable TI intubation time and total procedure time. Secondary variables included the completion rate of stable TI intubation and total procedure time. Total procedure time was defined as the time interval between insertion into and removal of the endoscope from the patient. All measurement times were measured with stopwatches.

Sample size calculation and interim analysis

The primary variable in this study was time to stable TI intubation. Sample size could not be determined due to lack of previous research data. Sixty patients (30 patients/group, 20 patients/institution) were tentatively enrolled. The sample size calculation of the interim analysis was predicated on enrollment of 40 patients using the primary variable. In the interim analysis, sample size was based on a two-tailed significance level of 0.05 and power of 0.90, $\beta = 0.1$, and an anticipated effect size of $d = \text{difference of means/standard deviation} = -0.91$. The required sample size was 22 in each group for a total of 44. Sixty eligible patients demonstrating statistical significance were scheduled for enrollment.

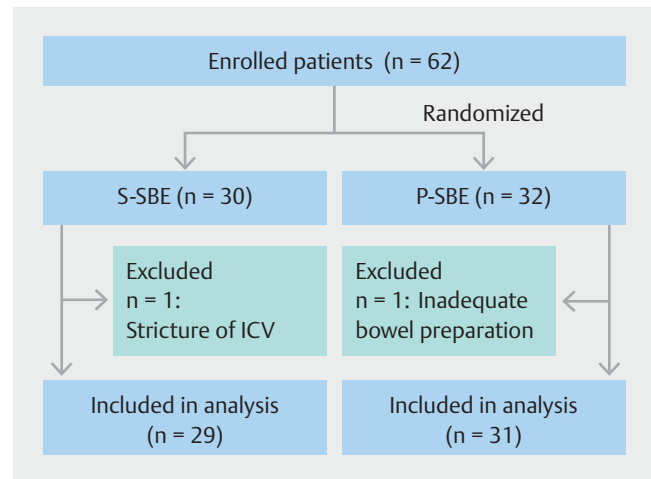
Statistical analysis

Data were analyzed using a per-protocol analysis. Statistical analyses were performed using the chi-square test for percentages, Student's *t*-test to assess differences in parameters showing a normal distribution and a non-normal distribution data set were applied using the Mann-Whitney U test with *P* values <0.05 considered significant. SPSS version 22 software (IBM Armonk, New York, United States) was used for all statistical analyses.

Results

No adverse events related to the procedure were reported in any cases. Sixty eligible patients demonstrating statistical significance were scheduled for enrollment. A flow diagram of the study's enrolled patients is shown in ► **Fig. 1**. Thirty patients were assigned to the S-SBE group, and the remaining 32 patients were assigned to the P-SBE group. One patient in the S-SBE group was excluded as a result of unidentified stenosis prior to examination due to an unknown ICV stricture before the study enrollment. Another patient in the P-SBE group was excluded due to inadequate preparation. In total, 60 patients were included in the analysis. Details about the background of each enrolled patient are shown in ► **Table 1**. There were no differences in background variables between each group (► **Table 1**).

The primary outcome of time to stable TI intubation of each endoscopy procedure is shown in ► **Fig. 2**. Time to stable TI intubation with P-SBE was significantly reduced compared to S-SBE (mean time of P-SBE vs S-SBE: 98.3 vs 169.4 second, *P* = 0.006). The completion rates for stable intubation within 10 minutes of using P-SBE and S-SBE were 96.8% (30/31) and 86.2% (25/29), respectively (*P* = 0.19) (► **Table 2**). Upon SBE endoscope replacement, all patients achieved stable TI intuba-



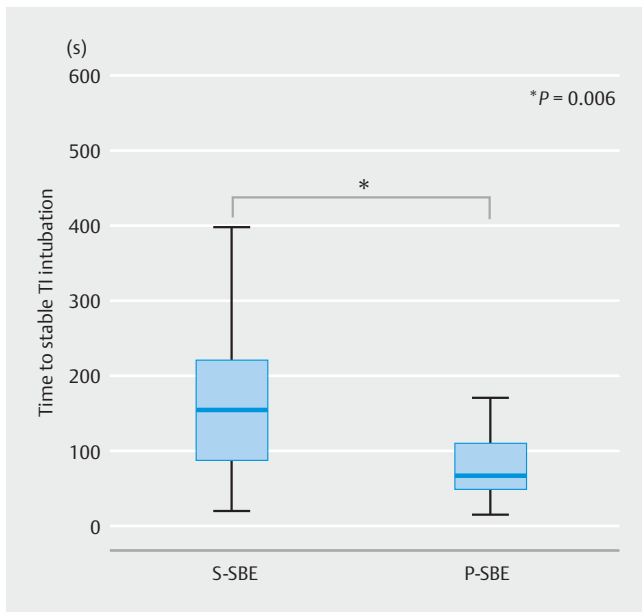
► **Fig. 1** Flow diagram of enrolled patients. S-SBE, standard single balloon enteroscope; P-SBE, prototype single-balloon enteroscope; ICV, ileocecal valve

tion within 10 minutes (► **Table 2**). Total procedure time was not significantly different between the two endoscope groups (► **Fig. 3**). A representative video of fluoroscopy is shown (see ► **Video 1**). In the S-SBE, loop formation was observed in the transverse colon with sharp angulation in the ascending colon and ileum precluding progression of the endoscopic tip to the deeper layers of the ileum (white delta indicates ICV). In contrast, in the P-SBE, the passive bending section of the endoscope employing the push and pull method helped to overcome sharp angulations allowing the tip to progress to the deeper layers of the ileum (white delta indicates ICV).

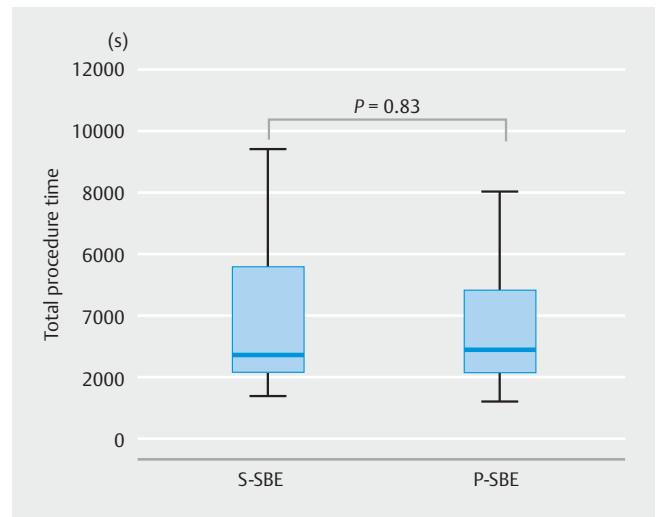
► **Table 1** Demographic characteristics of analyzed patients.

	S-SBE	P-SBE	<i>P</i> value
Number of patients	29	31	0.58
Male: female	19:10	22:9	0.15
Age (mean [SD])	54.3 (19.4)	47.6 (16.2)	0.28
Height (mean [SD]) (cm)	162.2 (9.3)	164.7 (8.1)	0.47
Body weight (mean [SD]) (kg)	57.1 (11.8)	59.2 (10.4)	0.58
Presence of previous abdominal surgery (%)	37.9	22.6	0.20
Indication for SBE (n)			
Investigation of diagnosed CD	10	13	0.40
OGIB	7	3	
Investigation of small intestinal inflammation	5	4	
Others	7	11	

S-SBE, standard single-balloon enteroscope; P-SBE, prototype single-balloon enteroscope; SBE, single-balloon enteroscope; CD, Crohn's disease; OGIB, obscure gastrointestinal bleeding



► **Fig. 2** Time to stable terminal ileum intubation of each endoscopy. Box plots show median value, interquartile range (IQRs), and 95% ranges (extremes and outliers are not shown). TI; terminal ileum; S-SBE, standard single-balloon enteroscope; P-SBE, prototype single-balloon enteroscope



► **Fig. 3** Total procedure time for each endoscopy. Box plots show median value, interquartile range (IQRs), and 95% ranges (extremes and outliers are not shown). S-SBE, standard single-balloon enteroscope; P-SBE, prototype single-balloon enteroscope

Discussion

Retrograde insertion of BAE is still technically challenging due to colonic loop formation, and the difficulties of passing through the ICV. Variable success rates for retrograde insertion of BAE have been reported. Yamamoto et al reported successful intubation of the ICV in all cases [1]. However, success rates with retrograde BAE procedures are variable [14, 15]. Difficulties entering the TI are primarily attributed to sharp angulation of the ileocolic angle [16]. The technique for TI intubation described by Yamamoto et al [17] involves visualizing the ileocecal valve (ICV) while the overtube balloon is inflated in the ascending colon, followed by pull-back of the balloon to reduce the ileocolic angle (thus exposing the ICV), and then intubation of the ileum with the enteroscope, all in the forward view. However, TI intubation is still incomplete even when performing this method. To overcome this bottleneck, several techniques and devices have been reported including preliminary colonoscopy [14], transparent hood [18], and pulling method with scope

balloon [16]. These reports are retrospective and descriptive in nature, but the efficacy of these interventions for ileal intubation with BAE has yet to be elucidated.

One possible solution to improve scope insertion into the deeper ileum utilizes RIT. Olympus has developed a prototype SBE with RIT. In the current prospective study, time to stable TI intubation with RIT was significantly decreased when compared to the non-RIT group. Consequently, we observed a reduction of approximately 70 seconds when applying RIT. Although not statistically significant, there was an approximate 10% increase in the rate of completion of achieving stable TI intubation within 10 minutes of RIT. Moreover, in the S-SBE group, it was possible to achieve stable TI intubation in all four failed cases when an SBE scope was replaced with RIT. In the P-SBE group, only one case was unable to achieve stable TI intubation. The potential cause of insertion failure in that case may have been unsuitability for stable ileal insertion with certain intestinal conditions such as an extremely redundant bowel. Mehdizadeh et al showed that the mean time to stable TI intubation was 28.2 minutes. By comparison, our results showed an extremely short mean time to stable TI intubation at 98.3 seconds. This inconsistency may be attributed to differences in the experience of participating endoscopists. All of the endoscopists in

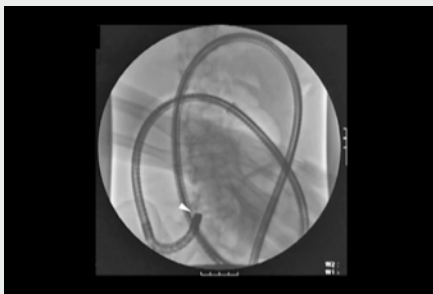► **Table 2** Completion rate of stable intubation within 10 minutes: results after endoscope replacement with two types of single-balloon enteroscopes.

	S-SBE	P-SBE	P value
Number of procedures	29	31	
Completion rate for stable TI intubation within 10 minutes	86.2% (25/29)	96.8% (30/31)	0.19
Completion rate for stable TI intubation after scope replacement	100.0% (4/4)	100.0% (1/1)	NA
Time to stable TI intubation after scope replacement (min – max, second)	38 – 191	63	NA

S-SBE, standard single-balloon enteroscope; P-SBE, prototype single-balloon enteroscope; TI, terminal ileum; NA, not assessed

the current study were highly trained experts; however, in the aforementioned report, participating physicians included novice endoscopists. In the current study, an approximate 70-second reduction was achieved when expert endoscopists utilized RIT. Therefore, novice endoscopists may expect an even greater time reduction based on these results. A decreased trend of the total procedure time using RIT was observed, however, statistical significance was not demonstrated. To elucidate the efficacy of RIT on total procedure time, it is important to conduct additional clinical trials that include novice endoscopists and a larger sample size.

Mehdizadeh et al also reported that stable TI intubation failure was more common among patients with prior abdominal or pelvic surgery, and time to achieve stable ileal intubation was prolonged in these patient cohorts. The recently developed short-type SBE is equipped with RIT, and its efficacy with surgically altered gastrointestinal anatomy has been reported [12]. We conducted a sub-analysis using postsurgical cases exclusively; however, similar trends were observed in terms of time to stable TI intubation and total procedure time (data not shown). Previous reports using the colonoscope with RIT concluded that RIT significantly reduced patient pain [7–11]. Although patient pain intensity scales were not evaluated in the current study, these results suggest pain may be reduced by using SBE with RIT. The efficacy of RIT in postoperative patients and its role in reducing patient pain should be evaluated in future studies. We excluded post-ileoceleal resection patients, however, post-colonic partial resection patients were included in the study. The variable of the insertion time from rectum to cecum was not measured. Several reports concluded that using a colonoscope with RIT, the cecal intubation rate and time to cecum were equivalent to those for a standard colonoscope. On the other hand, because the SBE is a thin and long scope, it is sometimes harder to reach the cecum. SBE with RIT might reduce insertion time from rectum to cecum.



Video 1 In the S – SBE group, loop formation was observed in the transverse colon with sharp angulation in the ascending colon and ileum precluding progression of the endoscopic tip to the deeper layers of the ileum (white delta indicates ICV). In contrast, in the P – SBE group, the passive bending section of the endoscope employing the push and pull method helped to overcome sharp angulations allowing the tip to progress to the deeper layers of the ileum (white delta indicates ICV).

Limitations

Harder endpoints such as depth of maximal insertion and diagnostic and therapeutic yield were not evaluated in the current study. In the study cohort, 10 patients with obscure gastrointestinal bleeding required deep insertion; however, the remaining patients did not require deep enteroscopy to observe targeted inflammation, and/or to obtain biopsy samples. Thus, variability of depth of maximal insertion was not appropriate for a primary endpoint. In the next study, depth of maximal insertion should be evaluated to confirm the performance of the SBE with RIT. We observed a reduction of time to stable TI intubation of approximately 70 seconds when applying RIT. However, the clinical significance of this reduction is still unknown. Initially, we attempted to conceal the allocated endoscope, however, one expert easily recognized the scope based upon the rigidity of the scope tip. As a result, this is a limitation of our research, which was conducted as an open-label study.

Conclusion

In conclusion, SBE with RIT improves insertability when entering the TI in retrograde BAE.

Competing interests

The prototype single-balloon enteroscope was provided by Olympus.

References

- [1] Yamamoto H, Sekine Y, Sato Y et al. Total enteroscopy with a nonsurgical steerable double-balloon method. *Gastrointest Endosc* 2001; 53: 216–220
- [2] Ohtsuka K, Kashida H, Kodama K et al. Diagnosis and treatment of small bowel diseases with a newly developed single balloon endoscope. *Dig Endosc* 2008; 20: 134–137
- [3] Tsujikawa T, Saitoh Y, Andoh A et al. Novel single-balloon enteroscopy for diagnosis and treatment of the small intestine: preliminary experiences. *Endoscopy* 2008; 40: 11–15
- [4] Manno M, Barbera C, Bertani H et al. Single balloon enteroscopy: Technical aspects and clinical applications. *World J Gastrointest Endosc* 2012; 4: 28–32
- [5] Mehdizadeh S, Han NJ, Cheng DW et al. Success rate of retrograde double-balloon enteroscopy. *Gastrointest Endosc* 2007; 65: 633–639
- [6] Saito Y, Kimura H. Responsive insertion technology. *Dig Endosc* 2011; 23: (Suppl. 01): 164–167
- [7] Hoff G, Bretthauer M, Huppertz-Hauss G et al. Evaluation of a novel colonoscope designed for easier passage through flexures: a randomized study. *Endoscopy* 2005; 37: 1123–1126
- [8] Sato K, Ito S, Shigiyama F et al. A prospective randomized study on the benefits of a new small-caliber colonoscope. *Endoscopy* 2012; 44: 746–753
- [9] Sato K, Shigiyama F, Ito S et al. Colonoscopy using a small-caliber colonoscope with passive-bending after incomplete colonoscopy due to sharp angulation or pain. *Surg Endosc* 2013; 27: 4171–4176

- [10] Prieto-de-Frias C, Munoz-Navas M, Carretero C et al. Comparative study of a responsive insertion technology (RIT) colonoscope versus a variable-stiffness colonoscope. *Rev Esp Enferm Dig* 2013; 105: 208–213
- [11] Garborg KK, Loberg M, Matre J et al. Reduced pain during screening colonoscopy with an ultrathin colonoscope: a randomized controlled trial. *Endoscopy* 2012; 44: 740–746
- [12] Yamauchi H, Kida M, Okuwaki K et al. Passive-bending, short-type single-balloon enteroscope for endoscopic retrograde cholangiopancreatography in Roux-en-Y anastomosis patients. *World J Gastroenterol* 2015; 21: 1546–1553
- [13] Shimatani M, Takaoka M, Ikeura T et al. Evaluation of endoscopic retrograde cholangiopancreatography using a newly developed short-type single-balloon endoscope in patients with altered gastrointestinal anatomy. *Dig Endosc* 2014; 26: (Suppl. 02): 147–155
- [14] Han S, Bhattacharya K, Cave DR. Preliminary colonoscopy facilitates retrograde double-balloon enteroscopy. *Endosc Int Open* 2014; 2: E241
- [15] Christian KE, Kapoor K, Goldberg EM. Performance characteristics of retrograde single-balloon endoscopy: A single center experience. *World J Gastrointest Endosc* 2016; 8: 501–507
- [16] Despott E, Fraser C. Achieving successful ileal intubation during retrograde double balloon enteroscopy: description of a novel, alternative technique (with video). *Endoscopy* 2009; 41: (Suppl. 02): 309
- [17] Sugano K, Kita H. *Double-balloon endoscopy: theory and practice*. Tokyo: Springer; 2006
- [18] Dufault DL, Brock AS. Cap-assisted retrograde single-balloon enteroscopy results in high terminal ileal intubation rate. *Endosc Int Open* 2016; 4: E202