Thieme

Endoscopy E-Videos

Endoscopic ultrasound-guided angiotherapy in refractory gastrointestinal bleeding from large isolated gastric varices: a same-session combined approach

A 36-year-old Asian man with severe portal hypertension due to hepatitis B virus-related cirrhosis had been previously treated for acute gastrointestinal bleeding from a large isolated gastric varix (IGV-1) by injection of endoscopic cyanoacrylate glue at a local hospital (▶ **Fig. 1**). Following an episode of massive recurrent hematemesis, the patient was hemodynamically stabilized and referred to our institute. Radiological evaluation revealed the presence of numerous collaterals in the gastric fundus with a large-caliber splenorenal shunt.

▶ **Fig. 1** Endoscopic view of a large isolated gastric varix (IGV-1) with signs of recent glue injection.

With the patient under general anesthesia, it was found that the portal gradient did not decrease significantly with a transjugular intrahepatic portosystemic shunt (TIPS) positioned across the left hepatic and left intrahepatic veins [1], confirming that blood outflow was predominantly diverted towards the shunt (▶ **Fig. 2 a**). We then decided to use a same-session combined technique involving balloon-occluded retrograde transvenous obliteration (B-RTO) of the left renal vein [2] and selective endoscopic ultrasound (EUS)-guided variceal embolization [3, 4] by coils and n-butyl-2-cyanoacrylate (CYA) injection.

A B-RTO was performed to obliterate the left renal vein before EUS-guided selective treatment in order to protect the pulmonary circulation from systemic embolization (▶ **Fig. 2 b**). Gastric varices (IGV-1) were then visualized from the stomach with a linear-array echoendoscope. Selective EUS-guided intravascular puncture was performed with a 22-gauge fine needle aspiration (FNA) needle (EZ Shot 3 Plus; Olympus Europe) and three 0.018-inch coils (MReye Embolization Coil; Cook Medical) were released through the needle under EUS and fluoroscopic control (▶ **Video 1**), the endovascular coils being advanced into the targeted vessel using the pushing ac-

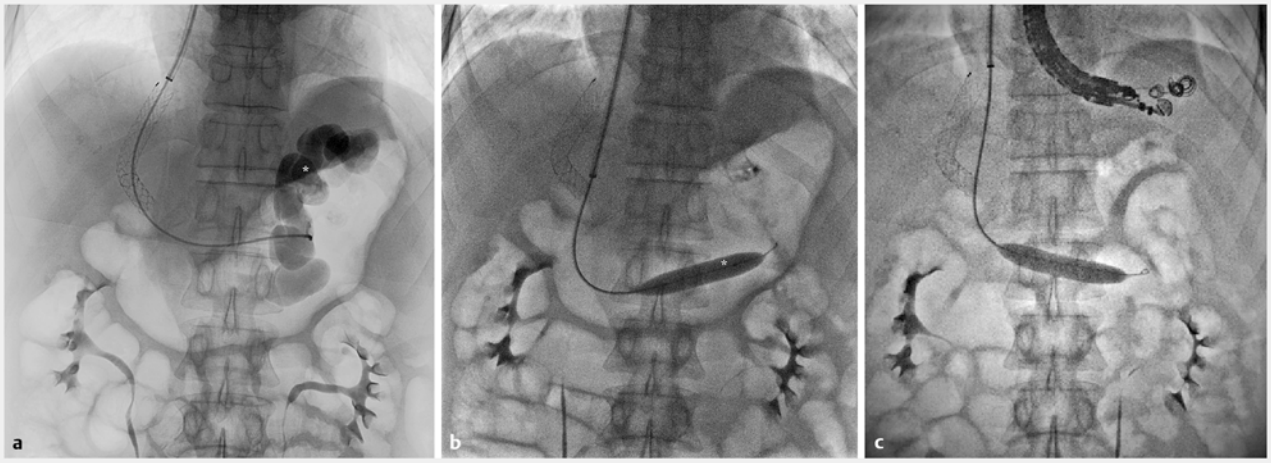

▶ **Fig. 2** Radiographic images showing: **a** contrast medium injected via a catheter inserted through the transjugular intrahepatic portosystemic shunt (TIPS) into the splenic vein, which confirmed portal outflow in the direction of a large splenorenal shunt (asterisk); **b** a balloon-occlusion catheter (asterisk) that had been advanced through the internal jugular access and positioned in the left renal vein to give protective closure of the efferent limbs of gastric varices; **c** EUS-guided selective embolization, with spiral coils (from 4 – 8 cm in length) having been selectively released according the size and axis of the gastric varix.

Video 1 Refractory bleeding from isolated gastric varices is successfully treated in a same-session combined approach using transjugular intrahepatic shunt (TIPS) placement, balloon-occluded retrograde transvenous obliteration (B-RTO), and endoscopic ultrasound (EUS)-guided variceal embolization by coils and cyanoacrylate glue injection.

tion of the stylet. Following the complete deployment of each coil, 1 mL of CYA, 3 mL of Lipiodol, and 10 mL of 5% glucose solution were injected through the needle into the varix creating a full thrombosis. We released a total of three coils (▶ **Fig. 2 c**) with complete variceal embolization as confirmed by a negative color Doppler scan. No adverse events or rebleeding had been reported at 12 months of follow-up.

EUS-guided coil placement with CYA injection is a feasible and effective additional procedure following TIPS placement in selected patients with severe portal hypertension and refractory bleeding from large IGV-1 varices.

Endoscopy_UCTN_Code_TTT_1AS_2AG

Competing interests

None

The authors

Ilaria Tarantino[1], Roberto Miraglia[2], Michele Amata[1], Dario Ligresti[1], Fabio Cipolletta[1], Luigi Maruzzelli[2], Mario Traina[1]

1 Endoscopy Service, IRCCS ISMETT, Palermo, Italy
2 Radiology Department, IRCCS ISMETT, Palermo, Italy

Corresponding author

Ilaria Tarantino, MD
Endoscopy Service, IRCCS ISMETTT, Palermo, Italy
itarantino@ismett.edu

References

[1] Garcia-Tsao G, Abraldes JG, Berzigotti A et al. Portal hypertensive bleeding in cirrhosis: Risk stratification, diagnosis, and management: 2016 practice guidance by the American Association for the study of liver diseases. Hepatology 2017; 65: 310 – 335
[2] Sabri SS, Saad WE. Balloon-occluded retrograde transvenous obliteration (BRTO): Technique and intraprocedural imaging. Semin Intervent Radiol 2011; 28: 303 – 313
[3] Bhat YM, Weilert F, Fredrick RT et al. EUS-guided treatment of gastric fundal varices with combined injection of coils and cyanoacrylate glue: a large U.S. experience over 6 years (with video). Gastrointest Endosc 2016; 83: 1164 – 1172
[4] Weilert F, Binmoeller KF. Cyanoacrylate glue for gastrointestinal bleeding. Curr Opin Gastroenterol. DOI: 10.1097/MOG.0000000000000294

Bibliography
DOI https://doi.org/10.1055/s-0043-107611
Online-Publikation: 3.7.2018
Endoscopy 2018; 50: 1033–1034

ISSN 0013-726X