

Neoadjuvant Therapy of Cervical Carcinoma with the Angiogenesis Inhibitor Bevacizumab: a Single-Centre Analysis

Neoadjuvante Therapie des Zervixkarzinoms mit dem Angiogeneseinhibitor Bevacizumab: eine monozentrische Auswertung



Authors

Philip Junker^{1*}, Julian Puppe^{1*}, Fabinsky Thangarajah¹, Christian Domröse¹, Angela Cepic¹, Bernd Morgenstern¹, Dominik Ratiu¹, Martin Hellmich², Peter Mallmann¹, Marina Wirtz¹

Affiliations

- 1 Uniklinik Köln, Klinik und Poliklinik für Gynäkologie und Geburtshilfe, Köln, Germany
- 2 Uniklinik Köln, Institut für Medizinische Statistik, Informatik und Epidemiologie, Köln, Germany

Key words

bevacizumab, VEGF antibody, cervical cancer, neoadjuvant chemotherapy

Schlüsselwörter

Bevacizumab, VEGF-Antikörper, Zervixkarzinom, neoadjuvante Chemotherapie

received 2.3.2018

revised 7.6.2018

accepted 8.6.2018

Bibliography

DOI <https://doi.org/10.1055/a-0641-5588>
Geburtsh Frauenheilk 2018; 78: 768–774 © Georg Thieme
Verlag KG Stuttgart · New York | ISSN 0016-5751

Correspondence

Dr. Julian Puppe
Uniklinik Köln, Klinik und Poliklinik für Frauenheilkunde und Geburtshilfe
Kerpener Straße 34, 50931 Köln, Germany
Julian.puppe@uk-koeln.de

Deutsche Version unter:
<https://doi.org/10.1055/a-0641-5588>

ABSTRACT

Introduction Cervical cancer is the fourth most frequent cancer in women worldwide. Addition of the VEGF antibody bevacizumab in combination with platinum-containing chemotherapy achieved an improvement in overall survival in advanced cervical cancer. To date there are no data on neoadjuvant use of bevacizumab. We therefore studied the benefit of neoadjuvant combined therapy with bevacizumab in a group of cervical cancer patients.

Patients and Methods This retrospective cohort study analysed 14 patients with cervical cancer FIGO stages 1b1 to IV who received neoadjuvant platinum-containing chemotherapy in combination with bevacizumab. The comparative cohort consisted of 16 patients who were treated with neoadjuvant platinum-containing chemotherapy alone. The response rates were determined by means of preoperative clinical examination, diagnostic imaging (RECIST), changes in tumour markers (SCC) and by histopathology.

Results A clinical response was found in 93.8% (n = 15) of patients after bevacizumab-free therapy and in 100% (n = 14) of the patients who were treated with bevacizumab in addition. Combined therapy with bevacizumab led to a higher rate of clinical complete remission (42.9 vs. 12.5%; p = 0.072) and significantly improved the reduction in tumour size (Δ longest diameter: 3.7 vs. 2.5 cm; p = 0.025). Downgrading was observed in 100% of all patients treated with bevacizumab compared with 75% in the control arm. The rate of pathological complete remission (pCR) was not altered significantly (28.6% [n = 4] vs. 37.5% [n = 6]; p = 0.460).

Discussion Overall, combined therapy with bevacizumab led to a better clinical response. Operability was therefore improved more often. Because of the small patient cohort, larger prospective studies are necessary to validate the effect of neoadjuvant combined therapy with bevacizumab.

ZUSAMMENFASSUNG

Einleitung Das Zervixkarzinom ist weltweit die vierthäufigste Krebserkrankung der Frau. Die Hinzugabe des VEGF-Antikörpers Bevacizumab in Kombination mit einer platinhaltigen

* contributed equally

Chemotherapie konnte bei fortgeschrittenen Zervixkarzinomen eine Verbesserung des Gesamtüberlebens erreichen. Zum neoadjuvanten Einsatz von Bevacizumab existieren bislang keine Daten. Daher haben wir an einem Kollektiv von Zervixkarzinompatientinnen den Nutzen einer neoadjuvanten Kombinationstherapie mit Bevacizumab untersucht.

Patienten und Methoden Für diese retrospektive Kohortenstudie wurden 14 Patientinnen mit Zervixkarzinomen der FIGO-Stadien 1b1 bis IV ausgewertet, die eine neoadjuvante platinhaltige Chemotherapie in Kombination mit Bevacizumab erhielten. Als Vergleichskohorte wurden 16 Patientinnen eingeschlossen, die mit einer alleinigen neoadjuvanten platinhaltigen Chemotherapie therapiert wurden. Die Ansprechraten wurden mittels präoperativer klinischer Untersuchung, radiologischer Diagnostik (RECIST), dem Tumormarkerverlauf (SCC), sowie durch pathologische Aufarbeitung ermittelt.

Ergebnisse Es zeigte sich ein klinisches Ansprechen bei 93,8% (n = 15) der Patientinnen nach Bevacizumab-freier The-

rapie und bei 100% (n = 14) der Patientinnen, die zusätzlich mit Bevacizumab behandelt wurden. Die Kombinationstherapie mit Bevacizumab führte zu einer höheren Rate von klinischen Komplettremissionen (42,9 vs. 12,5%; p = 0,072) und signifikant verbesserten Reduktion der Tumorgroße (Δ längster Durchmesser: 3,7 vs. 2,5 cm; p = 0,025). Ein Downgrading war in 100% aller mit Bevacizumab therapierten Fälle im Vergleich zur 75% im Kontrollarm zu beobachten. Die Rate an pathologischen Komplettremissionen (pCR) war nicht signifikant verändert (28,6% [n = 4] vs. 37,5% [n = 6]; p = 0,460).

Diskussion Insgesamt führte die Kombinationstherapie mit Bevacizumab zu einem besseren klinischen Ansprechen. Dadurch konnte häufiger die Operabilität verbessert werden. Aufgrund der kleinen Patientenzahl sind größere prospektive Studien notwendig, um den Effekt einer neoadjuvanten Kombinationstherapie mit Bevacizumab zu validieren.

Introduction

Cervical cancer is the fourth most frequent cancer in women worldwide and has high mortality [1]. In Germany, roughly 4500 women per year developed cervical cancer consistently in recent years [2]. According to the German S3 guideline, surgery remains the standard treatment of early cervical cancer, while primary surgery is omitted when at least three defined risk factors are present and the patient should then receive chemoradiotherapy. For locally advanced or metastatic cervical cancer, the option of primary chemotherapy followed by surgery is usually an alternative to chemoradiotherapy [3]. Neoadjuvant platinum-based chemotherapy at shortened intervals is intended to shrink the tumour, thus improving operability and reducing operative morbidity, and to prolong progression-free and overall survival [3, 4]. Women especially with primary cervical cancer and defined risks such as bulky disease or suspicious lymph node status may benefit from a neoadjuvant concept, in which the drug chemotherapy reduces the probable necessity for adjuvant chemoradiotherapy. This possible benefit must be balanced against the risks and side effects of systemic therapy [5].

In the last few years, good treatment results have been achieved with the use of bevacizumab in various solid tumours [6, 7]. The human papilloma viruses usually involved in their development are an important factor in efficacy, especially in the treatment of cervical cancer [3, 8]. Their high oncogenic potential is based on stimulation of angiogenesis through different points of attack [8]. Bevacizumab is a recombinant human monoclonal VEGF antibody, which inhibits the formation of new vessels in the tumour through competitive inhibition of VEGF receptors [9–11]. Initial experience with the use of bevacizumab in advanced cervical cancer by Monk et al. showed a significant improvement in median overall survival and progression-free survival [12]. The basis for approval of bevacizumab in advanced cervical cancer was the GOG-240 study by Tewari et al., in which 452 patients with recurrent or metastatic cervical cancer received either pure chemo-

therapy (combination of paclitaxel and cisplatin or paclitaxel and topotecan) or chemotherapy combined with bevacizumab [13, 14]. Significant improvements with regard to overall survival and progression-free survival were achieved [13, 14]. Good results were also shown for the combination of bevacizumab with conventional platinum-containing chemoradiotherapy [15]. To date, there is no experience with the use of bevacizumab in the neoadjuvant treatment of cervical cancer.

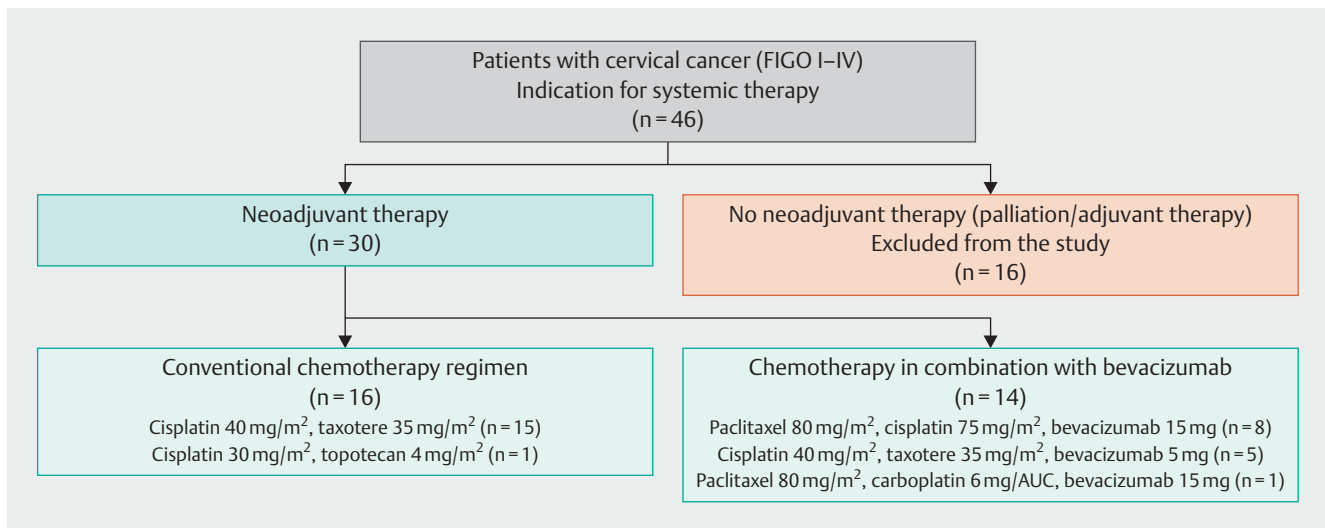
In this article, we would therefore like to report our initial clinical experiences with platinum-containing chemotherapy in combination with the angiogenesis inhibitor bevacizumab in the neoadjuvant treatment of cervical cancer. We also studied the effect of the addition of bevacizumab on remission rates and operability, comparing this with a bevacizumab-free group of patients.

Patients and Methods

Patients and therapy regimen

For this retrospective cohort study, 46 patients with histologically confirmed cervical cancer who received systemic treatment in the period from 2007 to 2016 in the oncology outpatient clinic of the department of obstetrics and gynaecology of Cologne University Hospital were screened. 30 patients who received neoadjuvant platinum-containing chemotherapy were included in the study (► Fig. 1).

Fourteen patients received neoadjuvant chemotherapy combined with bevacizumab. Eight patients received combined therapy consisting of paclitaxel (80 mg/m² q7), cisplatin (75 mg/m² q21) and bevacizumab (15 mg/kg q21). We gave an average of 12 cycles of paclitaxel (80 mg/m²), 4 cycles of cisplatin (75 mg/m²) and 4 cycles of bevacizumab (15 mg/kg). Five patients were given a combination of cisplatin (40 mg/m² q7), docetaxel (35 mg/m² q7) and bevacizumab (5 mg/kg q7). An average of 8 cycles of cisplatin (40 mg/m²), 8 cycles of docetaxel (35 mg/m²) and 6 cycles of bevacizumab (5 mg/kg) was given. One pa-



► **Fig. 1** Structure of the cohort study: the flow chart illustrates the number of cervical cancer patients screened for this study ($n = 46$) and included and excluded patients ($n = 30$), and describes the treatment regimen used in the two cohorts (NACT \pm bevacizumab).

tient received a treatment combination started elsewhere consisting of paclitaxel ($80 \text{ mg/m}^2 \text{ q7}$), carboplatin (6 mg/AUC q21) and bevacizumab (15 mg/kg q21). The cost of treatment was reimbursed by the health insurance companies following individual applications.

For the comparative cohort, 16 patients with bevacizumab-free therapy were analysed. Fifteen women received weekly therapy with cisplatin (40 mg/m^2) and docetaxel (35 mg/m^2), and one patient received cisplatin ($30 \text{ mg/m}^2 \text{ q7}$) and topotecan ($4 \text{ mg/m}^2 \text{ q7}$). The patients received an average of 8 cycles of cisplatin 40 mg/m^2 and 8 cycles of docetaxel 35 mg/m^2 . In the cisplatin/topotecan regimen, 8 cycles of cisplatin ($30 \text{ mg/m}^2 \text{ q7}$) and 8 cycles of topotecan ($4 \text{ mg/m}^2 \text{ q7}$) were given.

Study methods

Following the conclusion of the neoadjuvant chemotherapy, all patients had re-evaluation of tumour status by clinical examination and imaging appropriate to the primary tumour stage. Above FIGO stage IB2, extrapelvic spread was assessed by CT of the thorax/abdomen and locoregional spread by MRI of the pelvis, in accordance with the S3 guideline [3]. The scans were assessed radiologically according to the Response Evaluation Criteria In Solid Tumors (RECIST) [16]. A tumour that could no longer be detected compared with the pre-treatment imaging was defined as clinical complete remission (cCR). A tumour that regressed in size by more than 30% compared with the previous imaging was defined in accordance with RECIST criteria as partial remission (cPR). Lesions that regressed but could not be defined as partial remission according to RECIST criteria were recorded as response [17]. If histopathologic examination did not detect any residual invasive tumour, this was recorded as pathologic complete remission (pCR). In patients with a carcinoma smaller than FIGO IB2, re-evaluation after chemotherapy was not by radiologic imaging but by clinical ultrasonography [3]. The longest diameter in cm (LD) was used to measure tumour size. The change in tumour size was calculated as

the mean of the difference (ΔLD) before and after therapy. In 7 patients in the conventional therapy regimen and one patient in the cohort treated with bevacizumab, the diameter could not be determined from the available imaging. When there was a squamous epithelial tumour component, the serological response was reported as the mean change in the squamous cell carcinoma antigen (SCC) in the serum ($\mu\text{g/l}$) before and after the last cycle of neoadjuvant chemotherapy (ΔSCC). In 5 patients, there was no further information about the SCC course.

Statistical analysis

A structured medical database was set up through different clinical information systems (ORBIS® OpenMED, AGFA HealthCare NV, Cato®) and analysed through Excel® 2010 (Microsoft Corporation, Redmond, USA) and SPSS Statistics 22 (IBM Corporation, Armonk, New York, USA). Statistical calculation of the p-values was performed with Fisher's exact test and with Barnard's test [18].

Results

In the study period, 30 cervical cancer patients in total were treated with neoadjuvant chemotherapy containing platinum. Fourteen of these patients received chemotherapy combined with bevacizumab. This cohort was compared with 16 patients who were treated without bevacizumab. The demographic characteristics of the patient cohorts are listed in ► **Table 1**.

Combined therapy with bevacizumab increases the clinical response rates

► **Table 2** shows a comparison of the response rate after neoadjuvant therapy with or without bevacizumab. Neoadjuvant therapy with bevacizumab led to an improved clinical response (100% [$n = 14$] vs. 93.8% [$n = 15$], $p = 0.442$). The rate of clinical complete remission was higher in the patients treated with bevacizumab. A statistical trend in favour of the combined therapy with

► **Table 1** Clinical and histopathological tumour characteristics of the patients (n = 30): comparison of the bevacizumab-free treatment cohort (NACT) with the combined bevacizumab therapy (NACT + bevacizumab).

Variable		Total	NACT n (%)	NACT + bevacizumab n (%)	p-value
Total		30	16	14	0.967
Age			45.2	44.4	
Histologic type	Adenocarcinoma	9	7 (43.8)	2 (14.3)	0.118
	Squamous cell carcinoma	20	9 (56.2)	11 (78.6)	
	Clear cell carcinoma	1	0 (0)	1 (7.1)	
Grading (G)	G2	20	11 (68.9)	9 (64.3)	1
	G3	10	5 (31.1)	5 (35.7)	
Tumour stage (FIGO)	cT1	8	5 (31.3)	3 (21.4)	0.649
	cT2	15	9 (56.3)	6 (42.9)	
	cT3	2	0 (0)	2 (14.3)	
	cT4	5	2 (12.4)	3 (21.4)	
Nodal status	cN0	12	8 (50)	4 (28.6)	1
	cN+	18	8 (50)	10 (71.4)	
Metastasis	M0	27	14 (87.5)	13 (92.9)	
	M+	3	2 (12.5)	1 (7.1)	

► **Table 2** Response rates and progress parameters depending on neoadjuvant therapy with or without bevacizumab (NACT ± bevacizumab). The change in tumour size and SCC course were calculated as the means of the differences (Δ LD/ Δ SCC) before and after therapy.

Variable		NACT n (%)	NACT + bevacizumab n (%)	p-value
Total	30	16	14	0.917
Response	no	1 (6.3)	0 (0)	1.000
	yes	15 (93.7)	14 (100)	
cPR	no	4 (25)	6 (42.9)	0.442
	yes	12 (75)	8 (57.1)	
cCR	no	14 (87.5)	8 (57.1)	0.072
	yes	2 (12.5)	6 (42.9)	
pCR	no	10 (62.5)	10 (71.4)	0.460
	yes	6 (37.5)	4 (28.6)	
Downgrading	no	4 (25)	0 (0)	0.103
	yes	12 (75)	14 (100)	
R0 resection	no	2 (12.5)	0 (0)	1.000
	yes	14 (87.5)	14 (100)	
Δ LD (cm)		2.5	3.7	0.025
Δ SCC (μ g/l)		8.3	7.4	0.978

cPR: clinical partial remission; cCR: clinical complete remission; pCR: pathologic complete remission; LD: longest diameter in cm; SCC: squamous cell carcinoma antigen in the serum (μ g/l)

bevacizumab could be identified (42.9% [n = 6/14] vs. 12.5% n = 2/16]; p = 0.072). Clinical complete remission was achieved in the bevacizumab-free cohort up to stage FIGO IIb, while clinical complete remission was observed in higher stages also in the bevacizumab-treated cohort (► **Fig. 3**). Histopathological examina-

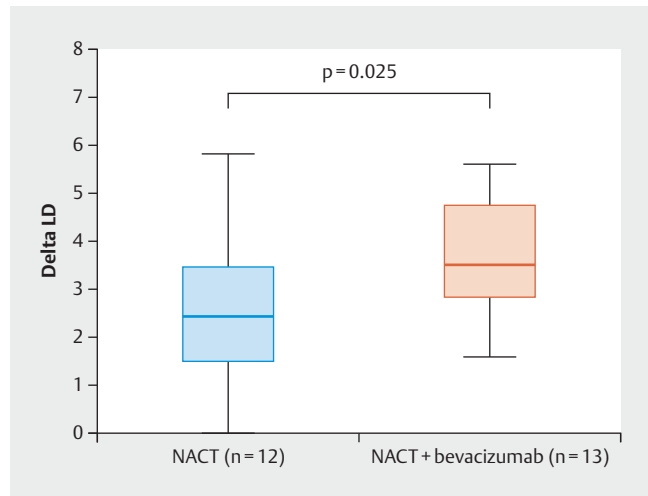
tion of the operation specimens showed downgrading in the sense of a positive change in tumour stage in 100% (n = 14) of patients treated with bevacizumab. This proportion was 75% (n = 12/16; p = 0.103) in the conventionally treated patients. The rate of pathologic complete remission (pCR) was not altered sig-

nificantly (28.6% [n = 4] vs. 37.5% [n = 6]; p = 0.460) (► **Table 2**). However, pCR was achieved even in FIGO stage IV in one case by the addition of bevacizumab. In this case there was a primary squamous cell carcinoma of the cervix with hepatic and lymphogenous metastases. By contrast, pCR after conventional therapy was observed only up to FIGO stage IIb. R0 resection was achieved in all patients treated with bevacizumab (100% [n = 14/14] vs. 87.5% [n = 14/16]; p = 1.0).

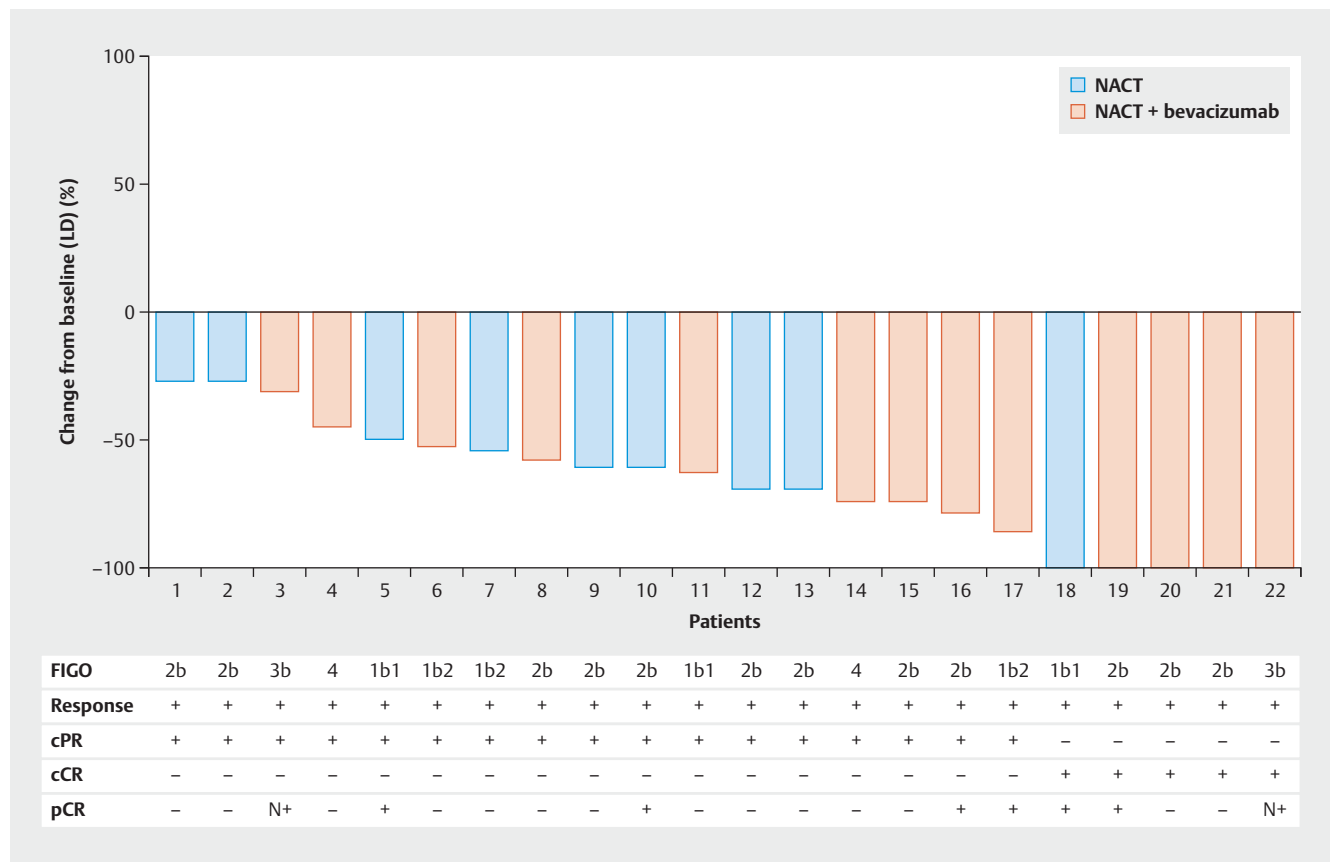
Addition of bevacizumab significantly improves tumour reduction

In the majority of patients (22/30), the pre- and post-treatment tumour size could be assessed objectively by imaging (MRI, CT) according to RECIST criteria (longest diameter – LD). Significantly better tumour reduction was achieved by combined bevacizumab therapy (p = 0.025, ► **Figs. 2 and 3**).

A markedly elevated SCC level in the serum was apparent before the start of therapy, especially with large cancers. Although the marked fall in the elevated SCC serum level with large cervical cancers was not statistically significant in our study (Δ SCC: 7.4 vs. 8.3 μ g/l; p = 0.978), we recorded remissions that were also confirmed serologically. As an example, one patient in stage IIIb (pa-



► **Fig. 2** Boxplot diagram shows better tumour reduction by addition of bevacizumab (Δ LD in cm = 2.5 \pm 1.6 vs. 3.7 \pm 1.2; p = 0.025). Fisher’s exact test with a significance level of α = 0.05.



► **Fig. 3** The waterfall plot shows the change in tumour size (LD) in percent before and after treatment with/without bevacizumab. The table shows the corresponding response rates and tumour stages. In 7/16 patients in the conventional group and 1/14 patients in the bevacizumab group information about the post-therapy tumour size was lacking and was excluded accordingly (abbreviations: cPR: clinical partial remission; cCR: clinical complete remission; pCR: pathological complete remission).

► **Table 3** List of registered side effects after bevacizumab combination therapy. They were classified according to CTCAE (Common Terminology Criteria for Adverse Events).

	Patients (n = 14)			
	None n (%)	Grade I n (%)	Grade II n (%)	Grade III n (%)
Anaemia	2 (14)	9 (64)	3 (21)	0 (0)
Neutropenia	3 (21)	4 (29)	7 (50)	0 (0)
Thrombocytopenia	7 (50)	5 (36)	2 (14)	0 (0)
Diarrhoea	9 (64)	5 (36)	0 (0)	0 (0)
Mucositis	3 (21)	9 (64)	2 (14)	0 (0)
Fistula/perforation	0 (0)	0 (0)	0 (0)	0 (0)
Hypertension	3 (21)	5 (36)	5 (36)	1 (7)
Proteinuria	6 (43)	3 (21)	5 (36)	0 (0)
Thromboembolic events	0 (0)	0 (0)	0 (0)	0 (0)
Fatigue	0 (0)	7 (50)	6 (43)	1 (7)

tient 22, ► **Table 3**) who received combined bevacizumab therapy had a fall in SCC from 21.4 µg/l initially to 1.5 µg/l and a reduction in tumour size (LD) from 5.6 initially to 0 cm, in the sense of a clinical complete remission.

No treatment-limiting side effects due to additional administration of bevacizumab

In our cohort, there were no treatment-limiting side effects overall on combined therapy with bevacizumab (► **Table 3**). The vast majority of the patients had blood count changes during ongoing combined therapy. Fatigue and exhaustion states occurred equally often on the treatment. One patient had grade III fatigue and had to be hospitalised for supportive treatment, but the next cycle was delivered without a delay. No fistulas or thromboembolic events were found in the entire cohort. 57% of all women had grade I and II proteinuria during therapy. Hypertensive changes occurred with similar frequency. One patient with pre-existing hypertension had an exacerbation of blood pressure levels to CTC grade III on bevacizumab. The chemotherapy with bevacizumab was continued with antihypertensive therapy.

Discussion

The aim of this retrospective analysis was to study the effect of bevacizumab in combination with neoadjuvant chemotherapy in cervical cancer. We observed that neoadjuvant chemotherapy with bevacizumab can significantly improve tumour regression in our patients, thereby possibly achieving increased response rates.

Even if no significant difference was found in overall response ($p = 1.000$), we were able to show a trend in the rate of clinical complete remission in favour of the bevacizumab cohort ($p = 0.072$). A similar observation was made in the GOG-240 study, where higher response rates of 50% were obtained in the cisplatin-paclitaxel-bevacizumab arm compared with 45% in the cisplatin-paclitaxel arm, though the difference was not significant ($p = 0.51$) [13]. Pathologic complete remission appears to have a relevant influence on overall survival as well as on progression-

free survival [19,20]. We therefore examined the rate of pathologic complete remission (pCR) also but did not achieve any significant improvement in the bevacizumab cohort. This non-significant difference is possibly attributable to the small patient cohort. In addition, it should be noted that the bevacizumab cohort contained more patients with advanced disease (cT3/cT4 carcinoma; $n = 5$), in whom pathologic complete remission is more difficult to achieve.

All patients treated with bevacizumab had R0 surgery. Moreover, downgrading was found in all. Thus, the addition of bevacizumab might possibly achieve better operability especially of large and initially inoperable tumours. Further prospective studies should examine the predictive value of tumour size in bevacizumab treatment.

The significantly greater anti-tumour effect on tumour size ($p = 0.025$) due to the addition of bevacizumab can be explained by pathophysiological processes. It is well known that the proliferation of new blood vessels plays a crucial role in the growth of a tumour [21]. VEGF expression and microvascular density are surrogate markers of angiogenesis and microvascular density correlates with the expression of VEGF [22]. High microvascular density has already been identified as an unfavourable marker for disease prognosis [23]. Saijo et al. showed in 2015 that high microvascular density was present in squamous cell cancers, especially at advanced stages, and in adenocarcinomas at any stage [24]. This increased vascular density is believed to enable chemotherapy to be more effective locally, with a better response to radiation due to increased oxygenation [25]. This explains the rationale for neoadjuvant therapy with bevacizumab. Lee et al. demonstrated a significant correlation between the reduction in tumour size and the fall in SCC after radiotherapy of cervical cancer [26]. We confirmed this observation to some extent in our bevacizumab-treated patients.

The small number of patients and non-homogeneous patient characteristics were weak points in this study. All patients received platinum-containing chemotherapy with or without bevacizumab but the dosage and therapy cycles were not uniform.

Nevertheless, a significant effect on tumour size and a trend in clinical response rates were observed due to the addition of bevacizumab, which indicates a corresponding treatment effect. Assessment of the resection status and of the clinical response rates could have been influenced by the subjective assessment and inter-observer variability. To reduce these confounding factors, the change in tumour size and response rates in patients re-evaluated radiologically were analysed according to RECIST criteria.

The side effect profile of bevacizumab includes hypertension and proteinuria in particular [27]. Similarly to the experience of the GOG-240 study, bevacizumab-associated side effects were apparent in our patients, but these were readily treatable and did not lead to discontinuation of the treatment [13].

Conclusion

Overall, combined therapy with bevacizumab led to a better clinical response and improved operability. The results should be interpreted cautiously because of the small case numbers but are encouraging for further prospective studies to validate the success of neoadjuvant combined bevacizumab therapy.

Conflict of Interest

The authors declare that they have no conflict of interest.

References

- [1] Ferlay J, Soerjomataram I, Dikshit R et al. Cancer incidence and mortality worldwide: Sources, methods and major patterns in GLOBOCAN 2012: Globocan 2012. *Int J Cancer* 2015; 136: E359–E386
- [2] Robert-Koch Institut. Krebs in Deutschland. Zentrum für Krebsregisterdaten des Robert-Koch-Institut. 3.16 Gebärmutterhals. 2016. Online: https://www.krebsdaten.de/Krebs/DE/Content/Publikationen/Krebs_in_Deutschland/kid_2017/kid_2017_c53_gebaermutterhals.pdf;jsessionid=1871430DA6305EC0F3DCFEC3A8675578.2_cid290?__blob=publicationFile; last access: 05.06.2018
- [3] Beckmann M, Mallmann P. S3-Leitlinie Diagnostik, Therapie und Nachsorge der Patientin mit Zervixkarzinom Version 1. – September 2014. Online: https://www.awmf.org/uploads/tx_szleitlinien/032-0330LL_S3_Zervixkarzinom_2014-10.pdf; last access: 05.06.2018
- [4] Rydzewska L, Tierney J, Vale CL et al. Neoadjuvant chemotherapy plus surgery versus surgery for cervical cancer. *Cochrane Database Syst Rev* 2010; (1): CD007406
- [5] Kim HS, Sardi JE, Katsumata N et al. Efficacy of neoadjuvant chemotherapy in patients with FIGO stage IB1 to IIA cervical cancer: an international collaborative meta-analysis. *Eur J Surg Oncol* 2013; 39: 115–124
- [6] Jackson MW, Rusthoven CG, Fisher CM et al. Clinical potential of bevacizumab in the treatment of metastatic and locally advanced cervical cancer: current evidence. *Oncotargets Ther* 2014; 7: 751–759
- [7] Carmeliet P. VEGF as a key mediator of angiogenesis in cancer. *Oncology* 2005; 69 (Suppl. 3): 4–10
- [8] Vici P, Mariani L, Pizzuti L et al. Emerging biological treatments for uterine cervical carcinoma. *J Cancer* 2014; 5: 86–97
- [9] Goel S, Wong AH, Jain RK. Vascular normalization as a therapeutic strategy for malignant and nonmalignant disease. *Cold Spring Harb Perspect Med* 2012; (3): a006486. doi:10.1101/cshperspect.a006486
- [10] Beckmann M. Bevacicumab beim fortgeschrittenen Zervixkarzinom: erste zielgerichtete Therapie mit signifikantem Überlebensvorteil bei fortgeschrittenem Zervixkarzinom. *Thieme Drug Report*. Stuttgart: Thieme; 2015
- [11] Yuan F, Chen Y, Dellian M et al. Time-dependent vascular regression and permeability changes in established human tumor xenografts induced by an anti-vascular endothelial growth factor/vascular permeability factor antibody. *Proc Natl Acad Sci U S A* 1996; 93: 14765–14770
- [12] Monk BJ, Sill MW, Burger RA et al. Phase II trial of bevacizumab in the treatment of persistent or recurrent squamous cell carcinoma of the cervix: a gynecologic oncology group study. *J Clin Oncol* 2009; 27: 1069–1074
- [13] Tewari KS, Sill MW, Long HJ et al. Improved survival with bevacizumab in advanced cervical cancer. *N Engl J Med* 2014; 370: 734–743
- [14] Tewari K, Sill M, Penson R et al. LBA26 ESMO 2014: Final Overall Survival Analysis of the Phase III Randomised Trial of Chemotherapy With and Without Bevacizumab for Advanced Cervical Cancer: A NRG Oncology-Gynecologic Oncology Group Study. *Ann Oncol* 2014. doi:10.1093/annonc/mdu438.27
- [15] Schefter T, Winter K, Kwon JS et al. RTOG 0417: efficacy of bevacizumab in combination with definitive radiation therapy and cisplatin chemotherapy in untreated patients with locally advanced cervical carcinoma. *Int J Radiat Oncol Biol Phys* 2014; 88: 101–105
- [16] Therasse P, Arbuck SG, Eisenhauer EA et al. New guidelines to evaluate the response to treatment in solid tumors. European Organization for Research and Treatment of Cancer, National Cancer Institute of the United States, National Cancer Institute of Canada. *J Natl Cancer Inst* 2000; 92: 205–216
- [17] Eisenhauer EA, Therasse P, Bogaerts J et al. New response evaluation criteria in solid tumours: revised RECIST guideline (version 1.1). *Eur J Cancer* 2009; 45: 228–247
- [18] Barnard GA. A New Test for 2 × 2 Tables. *Nature* 1945; 156: 783–784
- [19] Beskow C, Agren-Cronqvist AK, Granath F et al. Pathologic complete remission after preoperative intracavitary radiotherapy of cervical cancer stage Ib and IIa is a strong prognostic factor for long-term survival: analysis of the Radiumhemmet data 1989-1991. *Int J Gynecol Cancer* 2002; 12: 158–170
- [20] Kong S, Huang K, Zeng C et al. The association between short-term response and long-term survival for cervical cancer patients undergoing neoadjuvant chemotherapy: a system review and meta-analysis. *Sci Rep* 2018. doi:10.1038/s41598-018-19948-0
- [21] Folkman J, Watson K, Ingber D et al. Induction of angiogenesis during the transition from hyperplasia to neoplasia. *Nature* 1989; 339: 58–61
- [22] Tokumo K, Kodama J, Seki N et al. Different angiogenic pathways in human cervical cancers. *Gynecol Oncol* 1998; 68: 38–44
- [23] Cooper RA, Wilks DP, Logue JP et al. High tumor angiogenesis is associated with poorer survival in carcinoma of the cervix treated with radiotherapy. *Clin Cancer Res* 1998; 4: 2795–2800
- [24] Saijo Y, Furumoto H, Yoshida K et al. Clinical Significance of Vascular Endothelial Growth Factor Expression and Microvessel Density in Invasive Cervical Cancer. *J Med Invest* 2015; 62: 154–160
- [25] Randall LM, Monk BJ, Darcy KM et al. Markers of angiogenesis in high-risk, early-stage cervical cancer: A Gynecologic Oncology Group study. *Gynecol Oncol* 2009; 112: 583–589
- [26] Lee KC, Kim HJ, Sung K et al. The Predictive Value of Tumor Size, Volume, and Markers During Radiation Therapy in Patients With Cervical Cancer. *Int J Gynecol Cancer* 2017; 27: 123–130
- [27] Fachinformation Avastin®. Juni 2017