Dental Imaging – A basic guide for the radiologist

Dentale Bildgebung – Eine Einführung für den Radiologen

Authors

Max Masthoff[1], Mirjam Gerwing[1], Malte Masthoff[2], Maximilian Timme[3], Johannes Kleinheinz[3], Markus Berninger[4], Walter Heindel[1], Moritz Wildgruber[1], Christoph Schülke[1]

Affiliations

1 Institute of Clinical Radiology, Medical Faculty – University of Muenster – and University Hospital Muenster, Muenster, Germany
2 Dental Group Practice Masthoff and Trapmann, Marl, Germany
3 Clinic for Oral and Maxillofacial Surgery, Medical Faculty – University of Muenster – and University Hospital Muenster, Muenster, Germany
4 Department of Trauma Surgery, BG Trauma Center Murnau, Germany

Key words

dental imaging techniques, endodontology, periodontology, implantology, dental trauma

received 22.02.2018
accepted 04.05.2018

Bibliography

DOI https://doi.org/10.1055/a-0636-4129
Published online: 2019
Fortschr Röntgenstr 2019; 191: 192–198

ISSN 1438-9029

Correspondence

Dr. Max Masthoff
Institute of Clinical Radiology, Westfälische Wilhelms Universität Münster Medizinische Fakultät, Albert-Schweitzer-Campus 1, 48149 Münster, Germany
Tel.: ++ 49/2 51/8 35 62 79
max.masthoff@ukmuenster.de

ABSTRACT

Background As dental imaging accounts for approximately 40 % of all X-ray examinations in Germany, profound knowledge of this topic is essential not only for the dentist but also for the clinical radiologist. This review focuses on basic imaging findings regarding the teeth. Therefore, tooth structure, currently available imaging techniques and common findings in conserving dentistry including endodontology, periodontology, implantology and dental trauma are presented.

Methods Literature research on the current state of dental radiology was performed using Pubmed.

Results and Conclusion Currently, the most frequent imaging techniques are the orthopantomogram (OPG) and single-tooth radiograph, as well as computer tomography (CT) and cone beam CT mainly for implantology (planning or postoperative control) or trauma indications. Especially early diagnosis and correct classification of a dental trauma, such as dental pulp involvement, prevents from treatment delays or worsening of therapy options and prognosis. Furthermore, teeth are commonly a hidden focus of infection.

Since radiologists are frequently confronted with dental imaging, either concerning a particular question such as a trauma patient or regarding incidental findings throughout head and neck imaging, further training in this field is more than worthwhile to facilitate an early and sufficient dental treatment.

Key points

1. This review focuses on dental imaging techniques and the most important pathologies.
2. Dental pathologies may not only be locally but also systemically relevant.
3. Reporting of dental findings is important for best patient care.

Citation Format

- Masthoff M, Gerwing M, Masthoff M et al. Dental Imaging – A basic guide for the radiologist. Fortschr Röntgenstr 2019; 191: 192–198

ZUSAMMENFASSUNG

Hintergrund Da die dentale Bildgebung etwa 40 % aller Röntgenuntersuchungen in Deutschland ausmacht, sind fundierte Kenntnisse für den klinischen Radiologen auf diesem Gebiet essenziell. Der Fokus dieser Übersichtsarbeit liegt auf der Bildgebung des Zahnes. Hierfür werden Zahnaufbau, derzeit verfügbare Bildgebungstechniken und häufige Befunde der konservierenden Zahnheilkunde einschließlich der Endodontologie, Parodontologie und der Implantologie sowie nach dentalem Trauma vorgestellt.

Methode Es erfolgte eine Literaturrecherche zur dentalen Radiologie mittels Pubmed.

Ergebnisse und Schlussfolgerung Bildgebungstechniken erster Wahl sind weiterhin das Orthopantomogramm (OPG) sowie die Einzelzahnaufnahme. Ergänzend werden die Computertomografie (CT) und die digitale Volumentomografie (DVT), vorrangig für die Implantologie (Behandlungsplanung und Verlaufskontrolle) oder verunfallte Patienten, eingesetzt.

Insbesondere beim dentalen Trauma vermeidet eine exakte Diagnostik und korrekte Klassifikation, beispielsweise bezüglich einer Beteiligung der Zahnpulpa, Therapieverzögerungen oder deren Prognoseverschlechterung. Zudem können Zähne einen häufigen Infekt-Fokus darstellen.

Da Radiologen häufig mit der dentalen Bildgebung konfrontiert werden, sei es als dezidierte Fragestellung bei einem Trauma-Patienten oder bei Zufallsbefunden im Rahmen der Kopf-/ Halsbildgebung, ist eine „Blickschulung" für häufige Befunde lohnenswert, um frühzeitig eine suffiziente zahnärztliche Behandlung zu bahnen.

Introduction

Dental imaging is a frequent part of radiological practice, whether involving detection in the course of other issues or as a purposeful examination such as in patients with dental or orofacial trauma. Although the dental health of the population has improved in recent decades through optimized oral hygiene and prevention in dentistry [1], diseases of the tooth and its supporting structures continue to be associated with significant effects on, and limitations of, the quality of life for the affected patients. Early detection of these diseases is an important task for the radiologist as well. This review is therefore intended to provide a structured introduction to dental imaging.

Tooth Structure

Teeth are evolved ectodermal hard structures. The tooth is divided into the crown (corona), neck (cervix) and root (radix) (▶ **Fig. 1a**). On the crown, enamel surrounds the dentin. The pulp is in the center, tapering to the apex, and contains the vascular and nerve network. The root is anchored by a special form of syndesmosis (gomphosis). This dental supporting structure (periodontium) comprises the periodontal membrane, cement, alveolar wall and the gum (gingiva). Radiographically, the enamel, dentin and pulp can be distinguished from these structures due to their increased radiotransparency as well as the clearly visible periodontal cleft at the lamina dura at the transition to the alveolar process.

In adults, each half of the upper and lower jaw usually contains two incisors and one canine as well as two premolars and three molars.

Imaging Techniques

Imaging techniques available for dental radiology particularly include projection radiography with orthopantomogram (OPG) and targeted tooth images, digital volume tomography (DVT), CT and, in experimental approaches, MRI.

OPG is based on conventional X-ray tomography using a semicircular counter-rotating movement of the X-ray tube and image detector, and includes the teeth of the upper and lower jaw, the temporomandibular joints and parts of the maxillary sinus. Quality features of an OPG image include 1) a free, symmetrical projection of the mandibular ramus including the condylar process as an indicator of proper head tilt and rotation, 2) gray scale differentiation, and 3) a "real" size representation of the dental crowns of the maxillary anterior teeth as an indicator of a correct distance of the light beam localizer. A semicircular image can result in various artifacts, for example a fuzzy projection on the opposite side due to foreign materials such as earrings.

In Europe, orientation of the OPG is usually based on numbering according to the World Dental Federation (Fédération Dentaire Internationale, FDI) (▶ **Fig. 1b**). The first number marks the corresponding quadrant, starting in the right upper jaw (1) and finally following the clockwise direction to the right lower jaw (4); the second number indicates the teeth within the quadrant, starting at the first anterior tooth. In deciduous dentition, quadrant numbering 5 to 8 is used. Based on the individual tooth, the orientation is indicated as buccal (in the direction of the cheek), lingual or palatal (in the direction of the tongue or palate), mesial (in the direction of the anterior teeth) and distal (in the direction of the molar). Further directional indicators used are apical (toward the apex of the root) or coronal and occlusal (toward the occlusal surface).

Known as cone beam CT in English-speaking countries, digital volumetric tomography (DVT) is a method frequently employed in dental imaging to provide a superimposed, three-dimensional representation of the facial skull [2]. In this procedure, a cone-shaped X-ray beam and a two-dimensional image receptor are used to generate secondary slices as well as the corresponding 3 D reconstructions based on the volumetric data set. The DVT is primarily used for the planning of dental implants or surgical tooth extractions (especially for the determination of the distance to the inferior alveolar nerve, see ▶ **Fig. 1c**), but can also be used in the assessment of the paranasal sinuses or to aid assessment of the position of implants in the middle or inner ear [3]. Although initial studies discuss the use of DVT for soft tissue diagnostics [4], the radiation dose has to be significantly increased, however. Therefore, apart from dental (trauma) imaging, there are potential applications for DVT primarily in the imaging of bony structures and pathologies [5 – 7]. The effective DVT radiation dose was long considered to be about 10 times lower than that used in CT [8, 9]. However, according to the latest recommendations of the International Commission on Radiological Protection (ICRP), guidelines of the European Commission or various studies, this general statement must at least be discussed [10 – 12]. The effective radiation dose could be significantly reduced by adapting the CT scan parameters to dental issues instead of using classical scan protocols (cranial or paranasal sinuses) [13 – 15]. Such low-dose CT protocols showed in part a higher resolution and image quality compared to DVT, with faster acquisition and thus reduced movement artifacts [14, 16]. Furthermore, several studies have shown a significant (approximately 20-fold) range of the effective radiation dose when using different DVT equipment; some devices reached or even exceeded the dose values of CT [17 – 20]. Regarding the use of the individual modalities for three-dimensional dental imaging, it is not necessary to choose between DVT or CT, even taking into account the effective radiation dose;

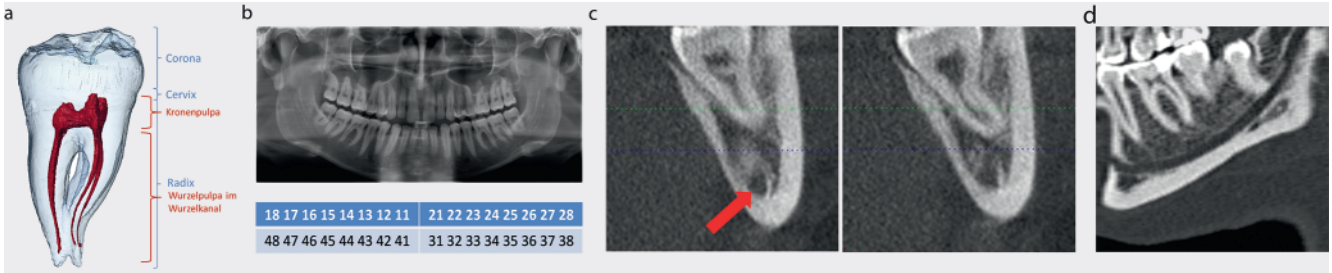

▶ **Fig. 1** **a** 3 D reconstruction of a 9.4 T MRI of an extracted tooth shows corona, cervix and radix. The dental pulp can be divided in crown and radix pulp. The root canal narrows to the apex, with completed root canal development the foramen apicale encloses. **b** Orthopantomogram with normal dentition. The table underneath shows the classification of adult dental numbering according to the FDI standard starting with 11 for the first incisor in the upper right quadrant to 48 for the wisdom tooth of the lower right quadrant. **c** Two exemplary preoperative cone-beam CT images prior to extraction of 38 to identify the position of the nervus alveolaris inferior in the canalis mandibularis (red arrow). **d** CT curved reconstruction along the left mandibular canal. Amongst other indications CT can be used for 3 D orientation regarding the distance of the root apex to the mandibular canal. In this example root apex 38 is in close proximity to the canal.

instead, the goal should be optimization of the scan parameters with respect to the dental issue. In contrast to computer tomographs, digital volume tomographs may also be used by dentists after acquiring corresponding specialist knowledge.

Using standard computed tomography, paracoronary and paraaxial reconstructions or virtual OPG views specially adapted to dental diagnostics can be calculated, or curved reconstructions made with dedicated post-processing programs tailored to dental diagnostic imaging (▶ **Fig. 1c**). Like DVT, this imaging technique can also be used for planning implant procedures and follow-up. As with DVT, a special X-ray template is usually used during imaging which is necessary for later implant planning. CT provides advantages over DVT with respect to soft tissue contrast; an MRI examination may also be used for this, if needed [21]. To date dental MRI has been used for experimental approaches [22].

Conservative Dentistry

The main focus in conservative dentistry is on cariology and endodontology. Caries is a biofilm-induced and sugar-driven multifactorial disease of the teeth resulting from alternating degeneration and remineralization of the hard tooth tissue [23]. Carious lesions appear as a circumscribed lightening of the tooth crown (▶ **Fig. 2a**) and, to the extent that there is no clinically irreversible damage to the pulp, are replaced by plastic fillers or inlays. Common plastic filler materials are amalgams, composites and glass ionomer cements that are not radiologically distinguishable from one another. Regular clinical and radiographic follow-ups are required due to the average material service life of approx. 10 years [24]. In addition to frequent secondary caries, defined as occurring caries in existing restoration, material failure or endodontic complications, for example, can necessitate replacement of the filling [25]. In imaging, a filling is more radiopaque that the physiological tooth and has no linear boundary (▶ **Fig. 2b**). Special attention should be given to the transition from the filling material to the hard tooth tissue in order to detect secondary caries or a protruding filling ledge as a risk factor in a timely manner (▶ **Fig. 2c**).

Endodontology focuses on diseases of the pulp-dentin complex and periapical tissue. Inflammation of these regions can be a

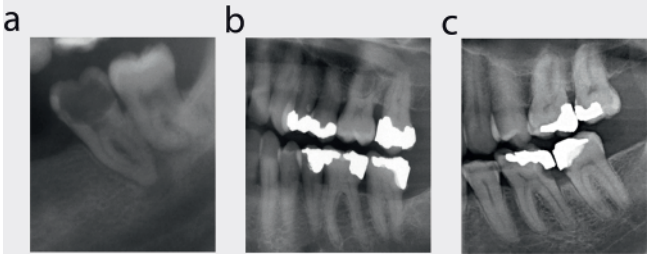

▶ **Fig. 2** **a** Extensive caries lesion with lucency of the corona. Apical lucency is also suspicious of a consecutive apical parodontitis with typical osteolysis. **b** Sufficient fillings of multiple teeth in line with the margin of the teeth. **c** Insufficient fillings with secondary caries at 27, 36 and 37 with a lucency close to the filling edges, which protrude in case of 36 and 37. This is a risk factor for accumulation of food rest, resulting in a higher risk of secondary caries lesions.

significant (unnoticed) source of infection and can significantly affect many medical or surgical treatments (immune or stem cell therapy, organ transplantation, etc.). The cause is usually a bacterial infection, as the entryway is often a carious defect. Pulpitis results when this inflammation spreads to the dental pulp. A distinction is made between reversible and irreversible forms. In the case of irreversible pulpitis, the entire endodontium (crown and root pulp) is considered to be irreversibly damaged, so that in contrast to reversible pulpitis, root canal treatment is generally also performed. After chemical and mechanical root canal treatment, the root canals are packed with filling material (usually gutta-percha), which is rendered radiopaque by the use of metal sulphates. A filling that ends 0 – 2 mm from the anatomical apex and is wall-tight and continuous is considered adequate (▶ **Fig. 3a**) [26]. Treatment complications include too short filling of the root (▶ **Fig. 3b**), overfilling the material apically from the root canal (also called "puff"), overlooked root canals, instrumental fractures (▶ **Fig. 3c**) or creation of a false passage.

Periapical inflammation results from the progression of pulpitis through the root canal or deep periodontal pockets to the root tip. Although acute forms may initially be inconspicuous in imaging, most of the time periapical lightening appears over time

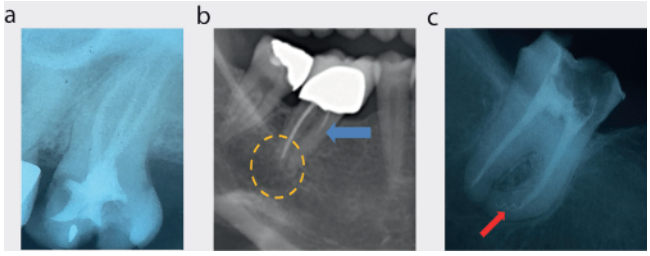

▶ **Fig. 3** **a** Sufficient root canal treatment to the root apex. **b** Insufficient root canal treatment of the mesial root (blue arrow). Additionally, the apical region shows a slight lucency, suspicious of a consecutive apical inflammatory reaction (yellow circle). **c** The wavelike hyperdensity at the apex of the mesial root represents remaining impurity after an instrument fracture during root canal treatment (red arrow).

(▶ **Fig. 3b**). As with pulpitis, the therapeutic option of choice is root canal treatment.

Periodontics

Periodontics is the branch of dental medicine dealing with the diagnosis and therapy of the structures supporting the teeth. Periodontitis, inflammation of the periodontal structures, is classified as chronic and aggressive forms [27]. Chronic periodontitis affects 52 % of 35 to 44 year-olds and more than 90 % of 75 to 100 year-olds [1]. Chronic periodontitis is further subdivided into a localized (< 30 % of teeth affected) and a generalized form (> 30 %), taking into account three degrees of severity (mild, moderate, severe) [27]. These degrees of severity are classified radiologically on the basis of the measurable bone loss (proportion of exposed root components in relation to the total root length). In the mild form there is a bone loss of 10 – 20 % of the root length (▶ **Fig. 4a**); moderate severity shows 20 – 50 % (▶ **Fig. 4b**), the severe form reflects more than 50 % loss (▶ **Fig. 4c**). The diagnosis of aggressive periodontitis is not clearly defined, but refers to a severe form, especially in young patients [27].

Various studies – some with contradictory results – discuss whether periodontal disease could have negative effects on various systemic diseases, such as rheumatoid arthritis [28], diabetes mellitus [29 – 32] and cardiovascular diseases [33], or even pose an increased risk of premature birth [22]. Thus, against this background, a sensitive diagnosis by the radiologist is useful.

Implantology

Dental implants serve as dental prostheses and are usually anchored endosseously in the jawbone. Such anchoring is also called osseointegration whereby osteoblasts integrate directly onto the implant surface [34]. Prior to implantation, sufficient distance from the mandibular nerve and the maxillary sinus and adjacent teeth must be taken into account during radiological planning (▶ **Fig. 5a**). After implantation, imaging is used to detect complications, especially implant and screw fractures or peri-implantitis caused by microbiological agents (▶ **Fig. 5b**) [35]. In order to diagnose peri-implantitis, among other things the vertical bone loss at the implant is evaluated radiologically [36].

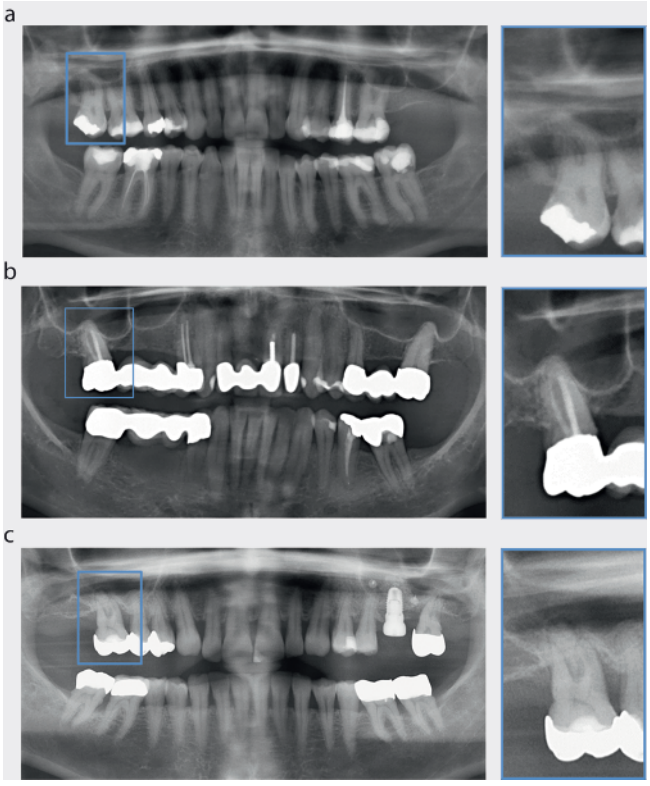

▶ **Fig. 4** Periodontitis can be classified according to a three level score. Exemplary detail images are shown on the right clearly indicating an advancing bone loss from **a** mild periodontitis with a bone loss of 10 – 20 % of the radix length to **b** intermediate (with 20 – 50 %) and **c** heavy periodontitis with more than 50 % bone loss.

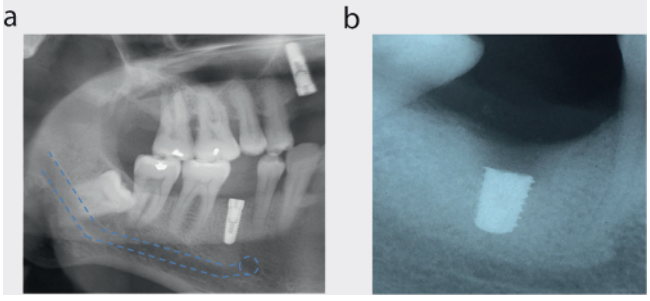

▶ **Fig. 5** **a** Two regular dental implants with correct axis alignment respecting the nervus alveolaris inferior (blue dotted line) and the maxillary sinus, respectively. Additional findings are an impacted wisdom tooth and an intermediate parodontitis. **b** Dental implant fracture with a remaining fragment within the bone.

Trauma

Traumas of the tooth are classified according to the ICD of WHO [37]. OPG and single-tooth images are the first modalities of choice and can be expanded to include DVT or CT if necessary [38, 39]. After concussion of the tooth, post-traumatic pain is present without additional clinical or radiological correlation. There is a distinction between tooth fractures and dislocations [39]. In dental fractures, the involvement of the pulp is crucial for further treatment (▶ **Fig. 6a**), therefore the findings should

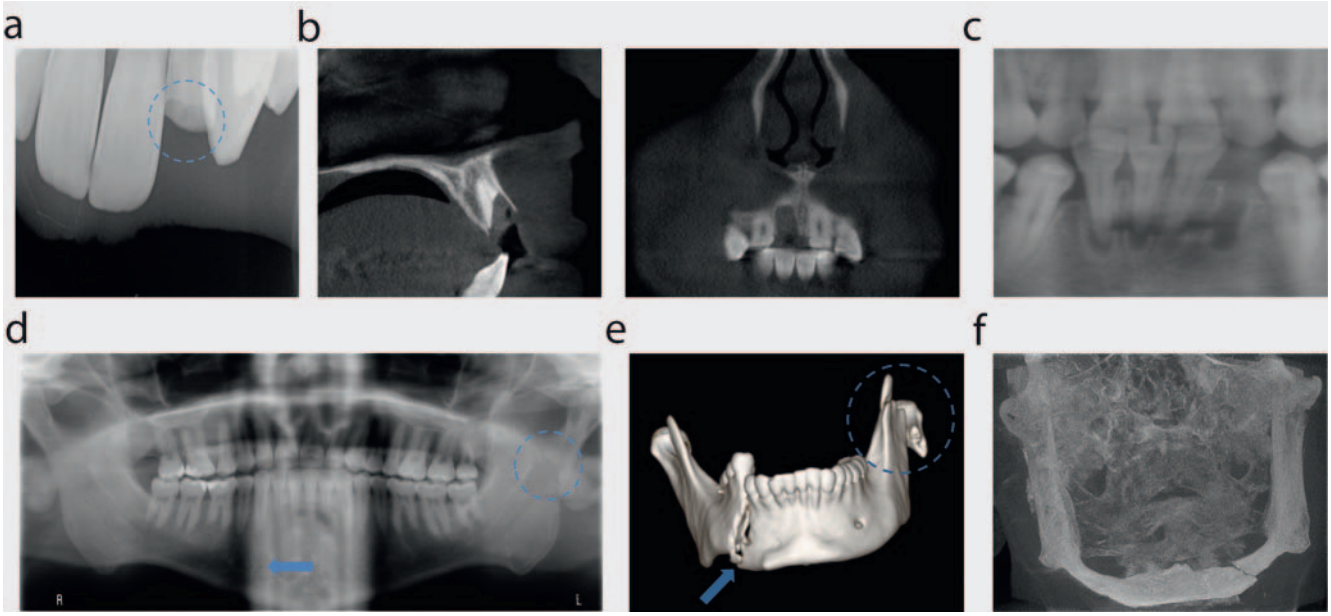

▶ **Fig. 6** **a** Traumatic horizontal tooth crown fracture 22 with involvement of the dental pulp (blue circle). **b** Two cone-beam CT images in sagittal (left) and coronar (right) view of a horizontal root fracture of 11 with complete crown dislocation. **c** Traumatic horizontal alveolar process fracture 31, 32, 41 and 42 with complete avulsion of 32 and extrusion of 31, 41 and 42. The periodontal space is consecutively widened. **d** Traumatic fracture of the processus condylaris on the left (blue circle), there is a second non-displaced fracture of the mandible onthe paramedian right (blue arrow). **e** 3 D CT reconstruction of the same pathomechanism in a different patient with dislocated mandibular fracture on the paramedian right (blue arrow) and dislocated fracture of proccesi condylaris and processus coronoideus on the left (blue circle). **f** Cone-beam CT volume reconstruction of a fracture in atrophied mandibula.

include both the involved tooth substances (enamel, dentin, pulp) and the fracture location (tooth crown, neck, root) (▶ **Fig. 6a, b**). A DVT can simply the diagnosis of the fracture (▶ **Fig. 6b**). In root fractures, longitudinal and transverse fractures are differentiated, with longitudinal fractures showing a poorer prognosis [38]. While the periodontal cleft is visibly compressed in traumatic dental intrusions, it is expanded during dislocation [39]. In lateral dental dislocations, the periodontal cleft is widened according to the direction of dislocation (▶ **Fig. 6c**), and there are often adjacent fractures of the alveolar process [39]. Eccentrically obtained dental films facilitate diagnostics in this case. Dental avulsion represents the maximum form of dislocation (▶ **Fig. 6c**). Repositioning followed by imaging should be performed as soon as possible. Teeth without completed root development, radiologically corresponding to an open apical foramen, have a significantly better prognosis during replantation. In the course of dental trauma, teeth can be ankylosed or resorbed; therefore regular projection radiographic follow-ups are indicated.

Depending on the trauma mechanism, dental injuries are often associated with jaw fractures, which may require an expansion of applied diagnostics (e. g. CT, DVT). It should be noted that, especially in lateral lower jaw fractures, additional (para-)median fissures with possible irradiation into the alveolar processes of the front teeth or incisors are possible (▶ **Fig. 6d, e**). A 3 D or volume reconstruction of the CT or DVT can also facilitate the fracture representation in this case (▶ **Fig. 6e, f**).

Conclusions

Dental imaging is an important component of clinical radiology for the detection of pathologies of the teeth and the periodontium, in order to enable early detection, prevention or dental treatment. It is therefore important to understand dental pathologies not only as local diseases but also with respect to their potential systemic impact.

Please note: Affiliation No. 3 was changed on July 4, 2018.

Conflict of Interest

The authors declare that they have no conflict of interest.

References

[1] Jordan RA, Bodechtel C, Hertrampf K et al. The Fifth German Oral Health Study (Funfte Deutsche Mundgesundheitsstudie, DMS V) – rationale, design, and methods. BMC Oral Health 2014; 14: 161

[2] Oenning AC, Jacobs R, Pauwels R et al. Cone-beam CT in paediatric dentistry: DIMITRA project position statement. Pediatr Radiol 2017. doi:10.1007/s00247-017-4012-9

[3] Miracle AC, Mukherji SK. Conebeam CT of the head and neck, part 2: clinical applications. Am J Neuroradiol 2009; 30: 1285 – 1292

[4] Uhlig J, Fischer U, Surov A et al. Contrast-enhanced cone-beam breast-CT: Analysis of optimal acquisition time for discrimination of breast lesion malignancy. Eur J Radiol 2018; 99: 9 – 16

[5] Casselman JW, Gieraerts K, Volders D et al. Cone beam CT: non-dental applications. JBR-BTR 2013; 96: 333 – 353

[6] Posadzy M, Desimpel J, Vanhoenacker F. Cone beam CT of the musculoskeletal system: clinical applications. Insights Imaging 2018; 9: 35 – 45

[7] Rehan OM, Saleh HAK, Raffat HA et al. Osseous changes in the temporomandibular joint in rheumatoid arthritis: A cone-beam computed tomography study. Imaging Sci Dent 2018; 48: 1 – 9

[8] Abuhaimed A, Martin CJ. Evaluation of coefficients to derive organ and effective doses from cone-beam CT (CBCT) scans: A Monte Carlo study. J Radiol Prot 2017. doi:10.1088/1361-6498/aa9b9f

[9] Loubele M, Bogaerts R, Van Dijck E et al. Comparison between effective radiation dose of CBCT and MSCT scanners for dentomaxillofacial applications. Eur J Radiol 2009; 71: 461 – 468

[10] European Comission. Cone Beam CT for Dental and Maxillofacial Radiology: Evidence Based Guidelines. 172 Radiation Protection Publication; 2012

[11] Pauwels R. Cone beam CT for dental and maxillofacial imaging: dose matters. Radiat Prot Dosimetry 2015; 165: 156 – 161

[12] Rehani MM, Gupta R, Bartling S et al. Radiological Protection in Cone Beam Computed Tomography (CBCT). ICRP Publication 129. Ann ICRP 2015; 44: 9 – 127

[13] Ballanti F, Lione R, Fiaschetti V et al. Low-dose CT protocol for orthodontic diagnosis. Eur J Paediatr Dent 2008; 9: 65 – 70

[14] Kyriakou Y, Kolditz D, Langner O et al. Digital volume tomography (DVT) and multislice spiral CT (MSCT): an objective examination of dose and image quality. Rofo 2011; 183: 144 – 153

[15] Loubele M, Jacobs R, Maes F et al. Radiation dose vs image quality for low-dose CT protocols of the head for maxillofacial surgery and oral implant planning. Radiat Prot Dosimetry 2005; 117: 211 – 216

[16] Hofmann E, Medelnik J, Fink M et al. Three-dimensional volume tomographic study of the imaging accuracy of impacted teeth: MSCT and CBCT comparison–an in vitro study. Eur J Orthod 2013; 35: 286 – 294

[17] Hofmann E, Schmid M, Lell M et al. Cone beam computed tomography and low-dose multislice computed tomography in orthodontics and dentistry: a comparative evaluation on image quality and radiation exposure. J Orofac Orthop 2014; 75: 384 – 398

[18] Hofmann E, Schmid M, Sedlmair M et al. Comparative study of image quality and radiation dose of cone beam and low-dose multislice computed tomography–an in-vitro investigation. Clin Oral Investig 2014; 18: 301 – 311

[19] Ludlow JB, Timothy R, Walker C et al. Effective dose of dental CBCT-a meta analysis of published data and additional data for nine CBCT units. Dentomaxillofac Radiol 2015; 44: 20140197

[20] Pauwels R, Beinsberger J, Collaert B et al. Effective dose range for dental cone beam computed tomography scanners. Eur J Radiol 2012; 81: 267 – 271

[21] Detterbeck A, Hofmeister M, Hofmann E et al. MRI vs CT for orthodontic applications: comparison of two MRI protocols and three CT (multislice, cone-beam, industrial) technologies. J Orofac Orthop 2016; 77: 251 – 261

[22] Puertas A, Magan-Fernandez A, Blanc V et al. Association of periodontitis with preterm birth and low birth weight: a comprehensive review. J Matern Fetal Neonatal Med 2018; 5: 597 – 602

[23] Pitts NB, Zero DT, Marsh PD et al. Dental caries. Nat Rev Dis Primers 2017; 3: 17030

[24] Palotie U, Eronen AK, Vehkalahti K et al. Longevity of 2- and 3-surface restorations in posterior teeth of 25- to 30-year-olds attending Public Dental Service-A 13-year observation. J Dent 2017; 62: 13 – 17

[25] Moraschini V, Fai CK, Alto RM et al. Amalgam and resin composite longevity of posterior restorations: A systematic review and meta-analysis. J Dent 2015; 43: 1043 – 1050

[26] Ribeiro DM, Reus JC, Felippe WT et al. Technical quality of root canal treatment performed by undergraduate students using hand instrumentation: a meta-analysis. Int Endod J 2017. doi:10.1111/iej.12853

[27] Armitage GC. Development of a classification system for periodontal diseases and conditions. Ann Periodontol 1999; 4: 1 – 6

[28] Kaur S, Bright R, Proudman SM et al. Does periodontal treatment influence clinical and biochemical measures for rheumatoid arthritis? A systematic review and meta-analysis. Semin Arthritis Rheum 2014; 44: 113 – 122

[29] Engebretson S, Kocher T. Evidence that periodontal treatment improves diabetes outcomes: a systematic review and meta-analysis. J Periodontol 2013; 84: S153 – S169

[30] Graziani F, Gennai S, Solini A et al. A systematic review and meta-analysis of epidemiologic observational evidence on the effect of periodontitis on diabetes An update of the EFP-AAP review. J Clin Periodontol 2018; 45: 167 – 187

[31] Kebede TG, Pink C, Rathmann W et al. Does periodontitis affect diabetes incidence and haemoglobin A1c change? An 11-year follow-up study. Diabetes Metab 2017. doi:10.1016/j.diabet.2017.11.003

[32] Sanz M, Ceriello A, Buysschaert M et al. Scientific evidence on the links between periodontal diseases and diabetes: Consensus report and guidelines of the joint workshop on periodontal diseases and diabetes by the International Diabetes Federation and the European Federation of Periodontology. J Clin Periodontol 2018; 45: 138 – 149

[33] Jepsen S, Stadlinger B, Terheyden H et al. Science transfer: oral health and general health – the links between periodontitis, atherosclerosis and diabetes. J Clin Periodontol 2015; 42: 1071 – 1073

[34] Zarb GA. Clinical application of osseointegration. An introduction. Swed Dent J Suppl 1985; 28: 7 – 9

[35] Hanif A, Qureshi S, Sheikh Z et al. Complications in implant dentistry. Eur J Dent 2017; 11: 135 – 140

[36] Ramanauskaite A, Juodzbalys G. Diagnostic Principles of Peri-Implantitis: a Systematic Review and Guidelines for Peri-Implantitis Diagnosis Proposal. J Oral Maxillofac Res 2016; 7: e8

[37] Bezroukov V. The application of the International Classification of Diseases to dentistry and stomatology. Community Dent Oral Epidemiol 1979; 7: 21 – 24

[38] Cohenca N, Silberman A. Contemporary imaging for the diagnosis and treatment of traumatic dental injuries: A review. Dent Traumatol 2017; 33: 321 – 328

[39] Tamimi D. Oral and Maxillofacial Radiology. Radiol Clin North Am 2018; 56: 105 – 124