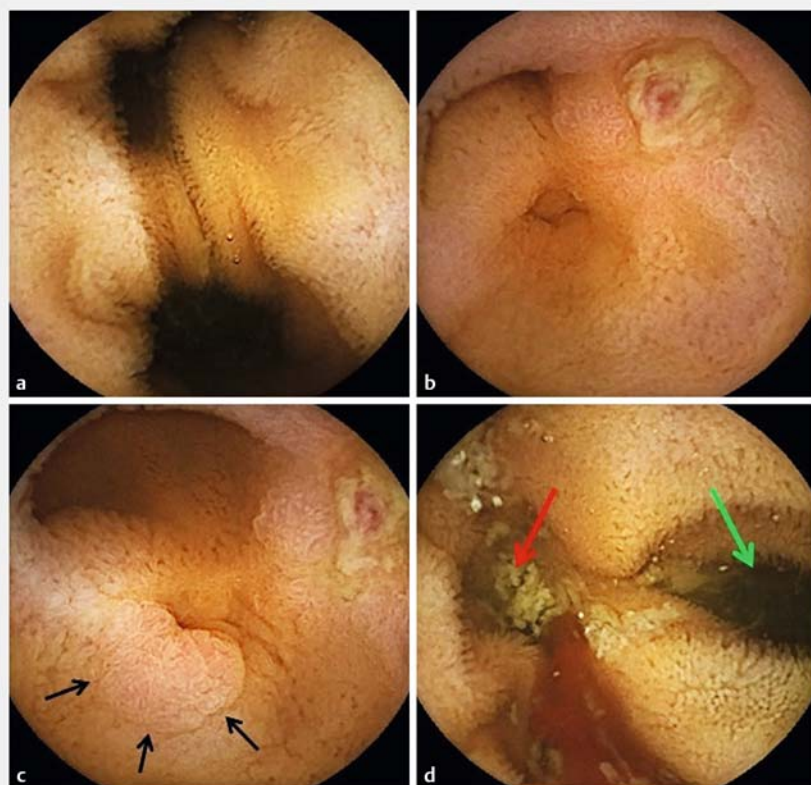


Meckel's diverticulum on third-generation video capsule endoscopy: intradiverticular ulcer, ectopic gastric mucosa, and active bleeding



▶ Fig. 1 Images obtained during small-bowel video capsule endoscopy showing: **a** an ileal diverticular orifice with the double-lumen sign. **b** ulceration with a visible vessel (Forrest IIa); **c** ectopic gastric mucosa (black arrows); **d** the presence of intradiverticular bleeding (red arrow, diverticular orifice; green arrow, ileum).

MECKEL'S DIVERTICULUM IN THIRD-GENERATION CAPSULE ENDOSCOPY:

INTRA-DIVERTICULAR ULCER,
ECTOPIC GASTRIC MUCOSA AND ACTIVE BLEEDING.

LE MOUËL JP, MORVAN J, FUMERY M, HAKIM S, DELCENSERIE R, CHATELAIN D, NGUYEN-KHAC E
AMIENS UNIVERSITY HOSPITAL

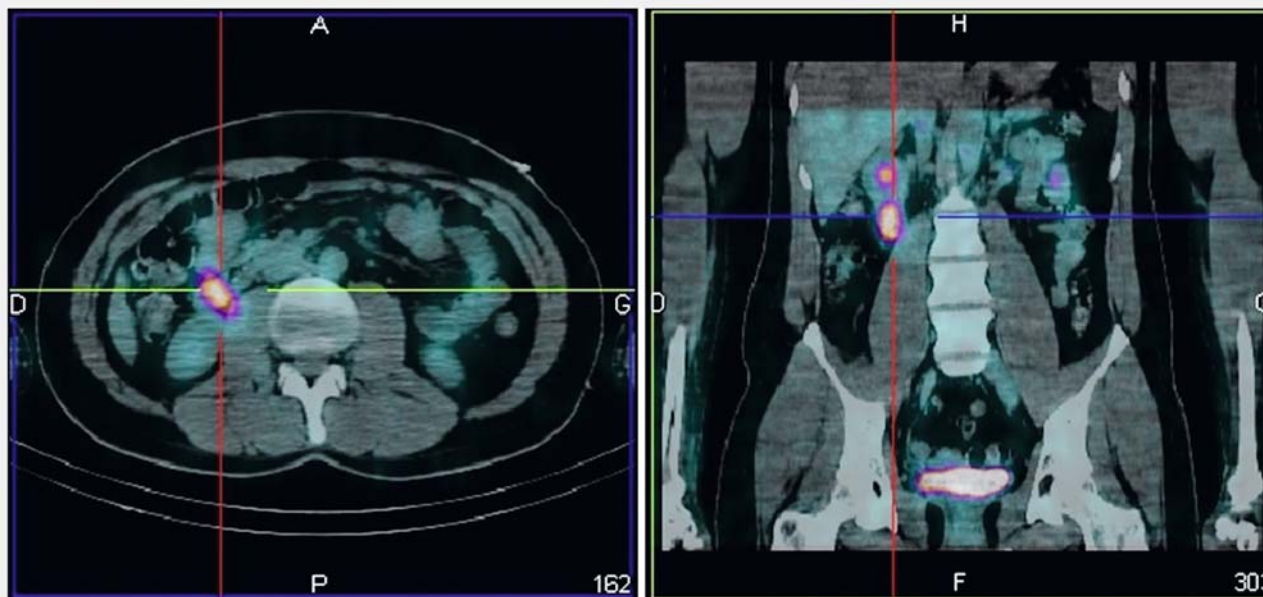


▶ Video 1 Appearances of a Meckel's diverticulum on third-generation video capsule endoscopy.

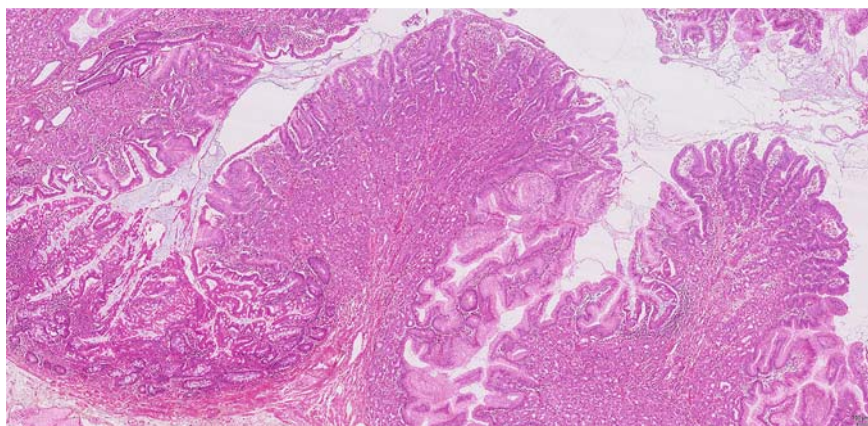
A 29-year-old man presented with acute rectal bleeding causing hemorrhagic shock. The patient had presented with a similar episode of digestive bleeding 4 years previously, with no diagnosis being found. His physical examination did not reveal any clinical abnormalities. Gastroscopy, colonoscopy, and abdominal computed tomography angiography (CTA) were normal. Small-bowel video capsule endoscopy revealed an ileal diverticular orifice, with the double-lumen sign. After passage of the capsule into the diverticulum, an ulcer with a visible vessel (Forrest IIa) was observed at the bottom of the diverticulum, located next to a patch of heterotopic gastric mucosa. During this examination, active bleeding was seen from this area of ulceration (**▶ Fig. 1**; **▶ Video 1**).

A Meckel's diverticulum was suspected. A ^{99m}Tc pertechnetate scintigraphy scan was performed, which confirmed the presence of ectopic gastric mucosa, corresponding to a probable Meckel's diverticulum (**▶ Fig. 2**). Surgery allowed the excision of a diverticulum of $6 \times 2 \times 1$ cm that was found 70 cm above the ileocecal valve. Histological examination confirmed the presence of ectopic fundal mucosa within the diverticulum (**▶ Fig. 3**). The patient left hospital 3 days after the surgery and has not re-presented with any further recurrence of bleeding.

Meckel's diverticulum is a vestigial remnant of the omphalomesenteric duct, located on the antimesenteric border of the ileum, within 100 cm above the Bauhin's valve. About 50% of symptomatic Meckel's diverticula have been found to contain ectopic tissue, especially gastric mucosa (35%–45%), which can cause ulceration and hemorrhage; 75% of hemorrhagic Meckel's diverticula contain gastric ectopic mucosa [1]. Abdominal CT is an insensitive test for detection, especially in adults. In patients with obscure gastrointestinal bleeding, small-bowel video capsule endoscopy is a po-



► **Fig. 2** ^{99m}Tc pertechnetate scintigraphy (Meckel's scan) showing ectopically located gastric mucosa.



► **Fig. 3** Histological appearance on hematoxylin, eosin, and saffron (HES) staining showing ectopic fundal mucosa.

tentially interesting test for the diagnosis of Meckel's diverticulum, with a positive predictive value up to 85% [2]. ^{99m}Tc pertechnetate scintigraphy (Meckel's scan), which specifically detects gastric mucosa, is more sensitive in a pediatric population (85%–90%) than in adult

patients (60%). This test is particularly effective when there are symptoms related to the ectopic gastric mucosa, such as bleeding [3].

Endoscopy_UCTN_Code_CCL_1AC_2AF

Competing interests

None

The authors

Jean-Philippe Le Mouel¹, Julie Morvan², Mathurin Fumery¹, Sami Hakim¹, Richard Delcenserie¹, Denis Chatelain³, Eric Nguyen-Khac¹

1 Department of Hepato-Gastroenterology, Amiens University Hospital, Amiens, France

2 Nuclear Medicine Department, Amiens University Hospital, Amiens, France

3 Department of Pathology, Amiens University Hospital, Amiens, France

Corresponding author

Jean-Philippe Le Mouel, MD

Department of Hepato-Gastroenterology, Amiens University Hospital, Amiens, France
jeanphilippe.lemouel@wanadoo.fr

References

- [1] Park JJ, Wolff BG, Tollefson MK et al. Meckel diverticulum: the Mayo Clinic experience with 1476 patients (1950–2002). *Ann Surg* 2005; 241: 529–533
- [2] Krstic SN, Martinov JB, Sokic-Milutinovic AD et al. Capsule endoscopy is useful diagnostic tool for diagnosing Meckel's diverticulum. *Eur J Gastroenterol Hepatol* 2016; 28: 702–707
- [3] Elsayes KM, Menias CO, Harvin HJ et al. Imaging manifestations of Meckel's diverticulum. *AJR Am J Roentgenol* 2007; 189: 81–88

Bibliography

DOI <https://doi.org/10.1055/a-0624-1392>
Published online: 12.6.2018
Endoscopy 2018; 50: E205–E207
© Georg Thieme Verlag KG
Stuttgart · New York
ISSN 0013-726X

ENDOSCOPY E-VIDEOS

<https://eref.thieme.de/e-videos>



Endoscopy E-Videos is a free access online section, reporting on interesting cases and new techniques in gastroenterological endoscopy. All papers include a high quality video and all contributions are freely accessible online.

This section has its own submission website at <https://mc.manuscriptcentral.com/e-videos>