

Opportunistic Salpingectomy at the Time of Benign Laparoscopic Hysterectomy: Assessment of Possible Complications and Histopathological p53-Signatures

Opportunistische Salpingektomie bei laparoskopischer Hysterektomie wegen gutartiger Erkrankung: potenzielle Komplikationen und histopathologische p53-Signaturen



Authors

Gautier Chene^{1,2}, Sarah Urvoas¹, Stéphanie Moret¹, Béatrice Nadaud³, Annie Buenerd³, Philippe Chabert¹, Georges Mellier¹, Gery Lamblin¹

Affiliations

- 1 Department of Gynecology, Hôpital Femme Mère Enfant, HFME, Lyon CHU, Lyon, France
- 2 University of Claude Bernard Lyon 1, EMR 3738, Lyon, France
- 3 Department of Pathology, Centre Hospitalier Est, Hospices civils de Lyon, Lyon, France

Key words

opportunistic salpingectomy, prophylactic salpingectomy, ovarian cancer, p53 signature, laparoscopy, hysterectomy

Schlüsselwörter

opportunistische Salpingektomie, prophylaktische Salpingektomie, Eierstockkrebs, p53-Signatur, Laparoskopie, Hysterektomie

received 22.10.2017

revised 15.4.2018

accepted 15.4.2018

Bibliography

DOI <https://doi.org/10.1055/a-0611-5167>

Geburtsh Frauenheilk 2018; 78: 605–611 © Georg Thieme Verlag KG Stuttgart · New York | ISSN 0016-5751

Correspondence

Dr Gautier Chene, MD
Department of Gynecology, HFME, CHU Lyon Est
59 boulevard Pinel, 69000 Lyon, France
chenegautier@yahoo.fr

ABSTRACT

Introduction The aim of this study is to assess the prevalence of tubal histopathological abnormalities (serous tubal intraepithelial carcinoma STIC and p53 signatures) and the prevalence of perioperative and postoperative complications related to opportunistic laparoscopic salpingectomy in a low risk population.

Materials and Methods In this observational prospective cohort, prophylactic bilateral salpingectomy during benign laparoscopic hysterectomy was systematically performed in 100 consecutive women. Peri- and postoperative complications were registered. Duration of salpingectomy and post-salpingectomy blood loss were also measured. Histopathological and immunohistochemical analysis with anti-p53 antibody were performed on the whole fallopian tubes according to a specific and validated protocol.

Results Laparoscopic salpingectomy was always possible without any peri- or postoperative complication attributable to the salpingectomy itself. The mean duration was 428 seconds (354–596) and the blood loss was 9 cm³ (2–15). Using histopathological and immunohistochemical assessment with anti-p53 antibody on 199 fallopian tubes (99 bilateral salpingectomies and one unilateral salpingectomy because of previous salpingectomy for ectopic pregnancy), there was a prevalence of 5.52% (11/199) of p53 signatures. No STIC were observed and no associated cancer.

Conclusions Laparoscopic salpingectomy is both feasible and innocuous during benign hysterectomy. Meticulous histopathologic examination of the tubes may reveal specific abnormalities.

ZUSAMMENFASSUNG

Einleitung Ziel dieser Studie war es, die Häufigkeit histopathologisch nachweisbarer Eileiteranomalien (seröse tubare intraepitheliale Karzinome [STIC] und p53-Signaturen) zu ermitteln sowie die Häufigkeit von perioperativen und postoperativen

ven Komplikationen im Zusammenhang mit opportunistischen laparoskopischen Salpingektomien in einer Niedrigrisikogruppe zu evaluieren.

Material und Methoden In einer prospektiven Kohortenstudie wurde bei 100 konsekutiven Frauen eine prophylaktische bilaterale Salpingektomie während einer geplanten laparoskopischen Hysterektomie durchgeführt. Alle peri- und postoperativen Komplikationen wurden erfasst. Die Dauer der Salpingektomie und der postoperative Blutverlust wurden ebenfalls gemessen. Die entnommenen Eileiter wurden einer histopathologischen und immunhistochemischen Analyse mit Anti-p53-Antikörper nach einem spezifischen validierten Protokoll unterzogen.

Ergebnisse Es gab keine peri- oder postoperativen Komplikationen bei der laparoskopischen Salpingektomie, die der Salpingektomie zuzuschreiben waren. Die durchschnittliche Operationsdauer für eine Salpingektomie betrug 428 Sekunden (354–596), und der Blutverlust betrug 9 cm^3 (2–15). Die histopathologische und immunhistochemische Analyse mit Anti-p53-Antikörpern bei 199 Eileitern (99 bilaterale Salpingektomien und eine einseitige Salpingektomie nach früherer Salpingektomie wegen Eileiterschwangerschaft) ergab eine Häufigkeit von 5,52% (11/199) für p53-Signaturen. Es fanden sich keine STIC und keine Karzinome.

Schlussfolgerungen Die während einer gutartigen Hysterektomie durchgeführte laparoskopische Salpingektomie ist sowohl praktikabel als auch ungefährlich. Eine sorgfältige histopathologische Untersuchung der Eileiter kann spezifische Anomalien aufdecken.

Introduction

The recent discovery and its supporting arguments that precancerous lesions of the fallopian tube precede high grade serous cancer of the ovary have given rise to change in paradigm [1]. Indeed, recent histopathological analyses of prophylactic salpingo-oophorectomies for genetic risk have revealed new occult precancerous lesions named Serous Tubal Intraepithelial Carcinoma or STIC. These lesions consist of nonciliated cells and are defined by the following features: epithelial stratification, nuclear atypias with an increase in the nucleocytoplasmic ratio, loss of nuclear polarity, nuclear pleiomorphism, loss of ciliated cells, intense and diffuse immunohistochemical expression of p53. Other earlier tubal lesions have also been described: the p53 signature, defined by a succession of at least 12 secretory cells with intense nuclear p53 staining. Finally, an ultra earlier lesion termed SCOUT (Secretory Cell Outgrowths), characterised by a succession of at least 30 pseudostratified secretory epithelial cells with a low expression of PAX2, PTEN and Ki67, and no p53 mutation has also been revealed. It is now presumed that the SCOUT lesions could develop into p53 signature and then into STIC. The STIC could metastasize in the ovary and peritoneum. Several series of non-genetic sporadic high-grade serous ovarian cancers were re-analysed and revealed the presence of the same tubal carcinogenic sequence. All these arguments would be in favour of the tubal origin of ovarian carcinogenesis and could lead to preventive surgical strategies as exclusive prophylactic salpingectomy without ovariectomy [1,2].

Taking advantage of benign hysterectomy to offer prophylactic salpingectomy with conservation of the ovary would on the one hand avoid provoking menopause and on the other could be an efficient means of preventing ovarian cancer [2].

In a very recent meta-analysis specifically addressing the protective effects of prophylactic salpingectomy in the general population, the risk of ovarian cancer was significantly reduced, with an OR = 0.51 (95% CI 0.35–0.75) [3]; however, these results must be interpreted with some prudence: the meta-analysis included only 3 studies and did not take the various histologic types of ovarian cancer into account [3]. Moreover, while hysterectomy

alone or salpingectomy alone are both related with a reduced incidence of ovarian cancer, the degree of protection obtained by associating hysterectomy and salpingectomy was not assessed. In terms of ovarian cancer prevention, would opportunistic salpingectomy with ovarian conservation during perimenopausal benign hysterectomy result in any advantages [4,5]?

In all Western countries we are witnessing an exponential increase in opportunistic salpingectomy during benign hysterectomy: exclusive salpingectomy without ovariectomy is recommended by several societies in Austria (the Austrian Society of Obstetricians and Gynaecologists OEGGG) [6], USA (the Society of Gynecologic Oncology and the American Congress of Obstetricians and Gynecologists) [7,8], Canada (the Society of Gynecologic Oncology of Canada and the Ovarian Cancer Research Program of British Columbia) [9,10], United Kingdom (the Royal College of Obstetricians and Gynaecologists RCOG) [11], Australia/New Zealand (Royal Australian and New Zealand College of Obstetrics and Gynaecology RANZCOG) [12] and in Germany (the German Kommission Ovar of the Arbeitsgemeinschaft Gynäkologische Onkologie AGO) [13].

We propose here to assess this new practice, focusing on the prevalence of tubal abnormalities (STIC or p53 lesion) and the prevalence of peri- and postoperative complications related with the salpingectomy procedure during laparoscopic hysterectomy.

Materials and Methods

Study design

We carried out a continuous prospective study between January 1, 2014 and December 31, 2015 at the Hôpital Femme Mère Enfant in Lyon, France. Bearing in mind the new tubal hypothesis of ovarian carcinogenesis [2], our surgical protocol for benign laparoscopic hysterectomy was modified to add systematic bilateral salpingectomy (or unilateral in case of history of previous salpingectomy). In the event of subtotal hysterectomy, the tubes were never morcellated and were always removed inside a bag via the suprapubic trocar immediately after salpingectomy. After prior in-

formed consent from the patient with ethics board approval, the decision to carry out complementary ovariectomy was made by the surgeon depending on her age (postmenopausal status) and/or the existence of ovarian abnormalities found preoperatively by ultrasound, or discovered macroscopically during surgery. The study was approved by the local ethics committee.

The exclusion criteria were:

- Hysterectomy in a context of gynecologic cancer
- Hysterectomy not carried out using laparoscopy
- Fimbriated end missing or damaged or impossible for pathologist to analyze
- No consent obtained from the patient, salpingectomy refused, inability to understand the information given

Surgical technique

The salpingectomy took place at the beginning of surgery, by section of the tuboovarian ligament, then section of the mesosalpinx closer to the fallopian tube than the ovary, and finally section of the fallopian tube from the uterus closer to the uterine horn. Hemostasis was performed by electrosurgical bipolar vessel sealing.

Histological analysis

Histopathological analysis of the tubes was carried out by two experienced pathologists, using a specific and validated protocol, the Sectioning and Extensively Examining of the Fimbriated end protocol (SEE-FIM protocol) [1]. Briefly, the tube was embedded completely in buffered formalin, then the fimbriated end and infundibulum were sampled using longitudinal sections 2 to 3 mm thick, with cross sections for the remainder of the tube. Each sample taken was embedded in paraffin; a 3 micron spread was stained by HPS (hematoxylin, phloxine, saffron) for morphologic analysis. There was also a systematic immuno-histochemical examination with amplification (Ultraview, Ventana). The slides were first deparaffinized; after heat-induced antigen retrieval using EDTA pH 9, anti-p53 antibody (Dako France, clone DO-7, dilution 1/400) was applied and the reaction revealed with DAB (diaminobenzidine).

The definition of a STIC (serous tubal intraepithelial carcinoma) lesion was based on the following criteria [1]: epithelial stratification, nuclear atypias with an increase in the nucleocytoplasmic ratio, loss of nuclear polarity, nuclear pleiomorphism, loss of ciliated cells, intense and diffuse immunohistochemical expression of p53. The p53 signature was defined by at least 12 consecutive secretory cells that were p53-positive by immunohistochemistry [1].

A standard protocol was used for histopathologic analysis of the ovariectomy and hysterectomy samples.

Data collections

We collected the following data for each patient: age, BMI, gestational, parity and menopause status, personal and/or family past history of gynecologic cancer, surgical indication, type of surgery, peri- and postoperative complications, uterine (cervix, myometrium, endometrium), ovarian and tube histology. The duration of salpingectomy was timed and postsalpingectomy blood loss was measured.

► **Table 1** Demographic data, per and postoperative (%). N = 100. The mean age of the population was 49.3 years. The type of laparoscopic hysterectomies was total in 72% and subtotal in 28%. Laparoscopic salpingectomy was always possible without any peri- or postoperative complication attributable to the salpingectomy itself. The mean duration of salpingectomy was 428 seconds (354–596) and the blood loss during salpingectomy was 9 cm³ (2–15).

Age (years)	49.3
BMI (kg/m ²)	26.3
Gestational status	2.9
Parity	2.35
Personal or family past history of gynecologic cancer	0
Type of laparoscopic hysterectomy	28 subtotal hysterectomies (28%) 72 total hysterectomies (72%)
Preoperative complications during salpingectomy	0
Postoperative complications attributable to salpingectomy	0
Postoperative complications attributable to the hysterectomy	6 (6%)
▪ bleeding at the right uterine pedicle	1 (1%)
▪ ureteral injury	1 (1%)
▪ vaginal cuff bleeding	2 (2%)
▪ urinary tract infection	2 (2%)
Duration of salpingectomy (seconds)	428 (354–596)
Postsalpingectomy blood loss (cm ³)	9 (2–15)

Statistical analysis

The main criterion assessed was prevalence of histopathologic tube anomalies (STIC or p53 lesion). The secondary criterion assessed was prevalence of peri- and postoperative complications related with achievement of the salpingectomy. In this descriptive study, the results are expressed in terms of percentage of the total number of patients.

Results

One hundred patients were included in this study.

Demographic data

The mean age of the population was 49.3 years old with no personal or family past history of gynecologic cancer. The type of laparoscopic hysterectomies was total in 72% and subtotal in 28%. It should be noted that laparoscopic salpingectomy was always possible without any peri- or postoperative complication attributable to the salpingectomy itself. The mean duration of salpingectomy was 428 seconds (354–596) and the blood loss during salpingectomy was 9 cm³ (2–15). The complications attributable to the hysterectomy were rare: bleeding at the uterine pedicle (1%), ureteral injury (1%), vaginal cuff bleeding (2%) and urinary tract infection (2%) (► **Table 1**).

► **Table 2** Clinical indications for surgery (%). Surgical indications were mainly related to symptomatic leiomyomas in 50% followed by menorrhagia in 27% of the population. None of the patients had a history of gynecologic cancer (n = 100).

Symptomatic leiomyomas	50 (50%)
Menorrhagia	27 (27%)
Uterine prolapse	11 (11%)
Pelvic pain	5 (5%)
Clinically benign ovarian cyst	4 (4%)
Cervical dysplasia	3 (3%)

► **Table 3** Main pathologic diagnosis in uterus (n = 100) and ovary (n = 36). Histopathological analysis was always benign.

In uterus	100
▪ adenomyosis	30 (30%)
▪ benign leiomyomas	50 (50%)
▪ benign mucosal polyps	10 (10%)
▪ benign endometrial hyperplasia	1 (1%)
▪ chronic endometritis	1 (1%)
In ovary	36
▪ no pathologic abnormality	26 (72.2%)
▪ functional cysts	7 (19.4%)
▪ benign dermoid cyst	1 (2.7%)
▪ benign serous cystadenoma	1 (2.7%)
▪ benign ovarian adenofibroma	1 (2.7%)

► **Table 4** Main pathologic diagnosis in fallopian tubes (n = 199). There were 11 tubes with the p53 signature in 9 patients, indicating a prevalence of 5.52% (11/199) with the following distribution: 7 (3.57%) unilateral p53 signatures and 2 (1%) bilateral p53 signatures. No STIC and no associated cancer were observed.

STIC	0
p53 signatures	11 (5.52%)
▪ unilateral p53 signatures	7 (3.57%)
▪ bilateral p53 signatures	2 (1%)
No pathologic abnormality	179 (89.9%)
Benign paratubal cysts	5 (2.5%)
Benign tubal papilloma	1 (0.5%)
Hydrosalpinx	1 (0.5%)
Benign tubal endometriosis	1 (0.5%)
Benign paratubal hemangioma	1 (0.5%)

Clinical indications for surgery

Surgical indications were mainly related to symptomatic leiomyomas in 50% followed by menorrhagia in 27% of the population, uterine prolapse in 11% of the cases, pelvic pain, clinically benign ovarian cyst and cervical dysplasia in respectively 5, 4 and 3% of the cohort. None of the patients had a history of gynecologic cancer (► **Table 2**).

Pathologic diagnoses in uterus, ovary and fallopian tubes

Histopathological analysis was always benign. Benign leiomyomas were found in 50% of the population. In the other cases, histopathological results showed adenomyosis (30%), benign mucosal polyps (10%), benign endometrial hyperplasia (1%) and chronic endometritis (1%). Ovariectomy was performed in 36% of cases: histopathological assessment was always benign with functional cysts (19.4%), benign dermoid cyst (2.7%), serous cystadenoma (2.7%) and ovarian adenofibroma (2.7%) (► **Table 3**).

During hysterectomy for benign indications, 99 bilateral salpingectomies and one unilateral salpingectomy (past history of salpingectomy for ectopic pregnancy) were carried out by laparoscopy. So the histopathologic analysis concerned 199 tubes.

There were 11 tubes with the p53 signature (► **Figs. 1 and 2**) in 9 patients, indicating a prevalence of 5.52% (11/199):

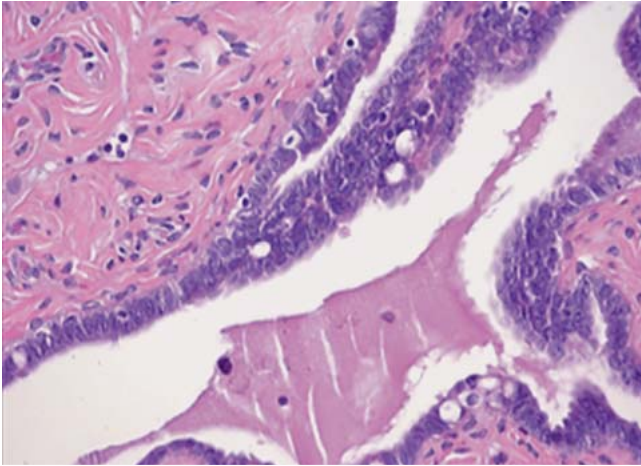
- 7 (3.57%) unilateral p53 signatures,
- 2 (1%) bilateral p53 signatures.
- No STIC and no associated cancer were observed.

The other associated pathological findings were: paratubal cysts (2.5%), tubal papilloma (0.5%), hydrosalpinx (0.5%), tubal endometriosis (0.5%) and paratubal hemangioma (0.5%) (► **Table 4**).

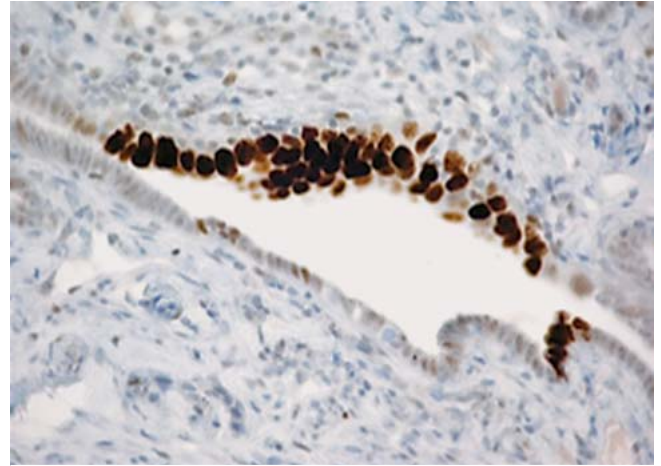
Discussion

With the recent discovery of a tubal origin for high-grade serous cancers of the ovary not only in the population at genetic risk (BRCA mutation) but also the general population [1,2], the concept of so-called opportunistic prophylactic salpingectomy has spread quickly and is carried out increasingly during hysterectomy for a benign indication during the perimenopause [2,4,14]. Up until the menopause it is essential to conserve the ovaries in order to avoid cardiovascular and osteoporosis morbidity and mortality [15]. Certain mathematical models even suggest conserving the ovaries beyond physiological menopause (up until age 65) due to the residual hormonal secretions [16]. Indeed the ovary produces androgens (androstenedione and testosterone) significantly with an aromatization in fat tissue into estrone after the menopause [17]. Inversely conservation of the tubes during hysterectomy does not appear to present any advantage: associated salpingectomy reduces postoperative infectious morbidity in both univariate (OR = 7.2; 95% CI 1.6–32.1) and multivariate analysis (OR = 4.9; 95% CI 1.1–22.9) [18]. Conservation of the tubes during hysterectomy could also result in nearly 35.5% hydrosalpinx and thus possibly repeat surgery [19].

If opportunistic salpingectomy is to be recommended, three questions must first be raised:



► **Fig. 1** p53 signature, hematoxylin phloxine saffron, original magnification $\times 400$.



► **Fig. 2** p53 signature, immunohistochemistry, original magnification $\times 400$.

1. Is salpingectomy always technically feasible? What is the morbidity?
2. Does salpingectomy during hysterectomy result in ovarian insufficiency or even premature menopause? In other words, what impact does salpingectomy have on the ovary?
3. Is opportunistic salpingectomy an efficient means of preventing ovarian cancer in the general population (that is, in the absence of any associated genetic risk)?

Concerning the first question, all depends on the approach used. Laparoscopy does not appear to involve any particular difficulties: in our series, it was possible for all the patients to undergo salpingectomy, which is confirmed by other studies [18, 20, 21]. Perioperative complications can be found in each series, including ours, but there are no complications at all that are attributable exclusively to salpingectomy. All the complications are related with the main indication for surgery, i.e. the hysterectomy [18, 20, 21].

However, a vaginal approach to the tubes may be more difficult and the success rate for salpingectomy varies between 73.9 and 88% for experienced teams [22, 23]. The complication rate attributable to the salpingectomy via the vaginal route could be estimated at up to 3.8% [23].

Concerning the second question, the salpingectomy surgical procedure must not affect ovarian vascularization. First the surgeon must coagulate and section the tuboovarian ligament without coagulating the infundibulopelvic ligament. Then the mesosalpinx must be coagulated and sectioned, closer to the fallopian tube (in order to protect the ovarian artery) [17]. For other authors, the surgeon should perform a wide excision of soft tissues adjacent to the ovary and fallopian tube because the mesosalpinx structure could give rise to carcinoma [24]. Finally, the surgeon has to section and coagulate the tube level with the uterine horn [17]. The intrauterine portion of the fallopian tube should be removed because STIC lesions have been described in this location despite previous salpingectomy [25]. In another study about 522 women at low risk of ovarian cancer and from whom systematic prophylactic salpingectomy was performed during benign sur-

gery, 4 STICs were identified: 3 STICs were located in the fimbriae whereas one STIC was in the nonfimbriated portion of the tube [26]. Several studies thus have analyzed the impact of salpingectomy on the ovarian reserve by comparing hormone levels (in particular the anti-mullerian hormone) and Doppler flow data in the ovary before and after salpingectomy [24, 27, 28]: a recent meta-analysis based on 13 studies concluded that “the salpingectomy does not appear to affect ovarian function. It may, however, impair the ovarian reserve in the long run” [29]. Despite there is no data in the literature concerning when menopause commences after salpingectomy, it seems that the addition of opportunistic salpingectomy during laparoscopic hysterectomy does not cause any long-term effects (3 to 5 years later) on ovarian function [30].

Finally, with respect to the last question, several precancerous lesions have been identified in the tube: in the carcinogenic sequence, the p53 signatures come before those of STIC lesions. The latter then metastasize to the ovary and neighboring peritoneum [1, 2]. However we still do not know which p53 lesions will evolve towards STIC and which p53 lesions will never evolve or may even disappear. Various molecular biology techniques such as next generation sequencing have been able to discriminate between different STIC lesions, some of which gave rise to ovarian cancer while others were micrometastases of uterine endometrioid carcinoma [31]. It is probable that this kind of molecular technology will be able to discriminate between different p53 signatures.

Our results also raise the question of how to share information with the patients (possibly causing anxiety [32]) and of monitoring, if any: the clinical significance of STIC in the general population with low risk is unknown. Only 10% of STIC diagnosed in the high risk population with BRCA mutation could subsequently develop into ovarian carcinoma. We could therefore suppose that this prevalence may be lower in the general population, and this has been demonstrated in a previous study with 522 patients at low risk and only 4 STICs ($4/522 = 0.76\%$) [26]. The risk of p53 lesions evolving could therefore be very low.

On the other hand, it is important to consider the evolutionary timeline of ovarian cancer development: a very recent molecular study about whole-exome sequence and copy number analyses of laser capture microdissected precancerous tubal lesions has demonstrated that p53 signatures and STICs are precursors of ovarian cancers (clonal relationship between them with the same molecular mutations) and that the timing of the progression from these precancerous lesions to invasive ovarian cancers was on average 6.5 years [33]. Until now, the histopathological analysis of fallopian tube in the general population (i.e. no genetic mutation) was only a macroscopic examination with a single representative tissue section per tube. We and others really think that there should be a change in tubal tissue histopathological sampling protocol not only for the genetic population with BRCA mutations but also in the general population when an opportunistic salpingectomy is performed [26].

To conclude, there is practically no doubt that laparoscopic salpingectomy is both feasible and innocuous. Whether it is useful in terms of preventing ovarian cancer when combined with benign hysterectomy in the general population has not yet been established [1, 2]. The only way to find the answer to this tricky question is to set up registers and long-term prospective studies (as is the case in the province of British Columbia in Canada) [10].

Funding source: None.

Conflict of Interest

The authors declare that they have no conflict of interest.

References

- [1] Chene G, Dauplat J, Radosevic-Robin N et al. Tu-be or not tu-be: that is the question... about serous ovarian carcinogenesis. *Crit Rev Oncol Hematol* 2013; 88: 134–143
- [2] Chene G, Rahimi K, Mes-Masson AM et al. Surgical implications of the potential new tubal pathway for ovarian carcinogenesis. *J Minim Invasive Gynecol* 2013; 20: 153–159
- [3] Yoon SH, Kim SN, Shim SH et al. Bilateral salpingectomy can reduce the risk of ovarian cancer in the general population: A meta-analysis. *Eur J Cancer* 2016; 55: 38–46
- [4] Dietl J, Wischhusen J, Häusler SF. The post-reproductive Fallopian tube: better removed? *Hum Reprod* 2011; 26: 2918–2924
- [5] Chêne G, Lamblin G, Marcelli M et al.; French College of Obstetrics and Gynecology (CNGOF). [Urinary, infectious and digestive adverse events related to benign hysterectomy and the associated surgery on the Fallopian tube: Guidelines]. *J Gynecol Obstet Biol Reprod (Paris)* 2015; 44: 1183–1205
- [6] Austrian Society for Obstetrics and Gynecology (OEGGG). Austrian Society for Obstetrics and Gynecology (OEGGG) Position paper: Elective salpingectomy for the prevention of epithelial ovarian cancer. Online: http://www.oeggg.at/downloads/Leitlinien/Stellungnahme_Salpingektomie_011015.pdf; last access: 19.05.2018
- [7] Walker JL, Powell CB, Chen LM et al. Society of Gynecologic Oncology recommendations for the prevention of ovarian cancer. *Cancer* 2015; 121: 2108–2120
- [8] Committee on Gynecologic Practice. Committee opinion no. 620: salpingectomy for ovarian cancer prevention. *Obstet Gynecol* 2015; 125: 279–281
- [9] Salvador S, Scott S, Francis JA et al. No. 344-Opportunistic Salpingectomy and Other Methods of Risk Reduction for Ovarian/Fallopian Tube/Peritoneal Cancer in the General Population. *J Obstet Gynaecol Can* 2017; 39: 480–493
- [10] McAlpine JN, Hanley GE, Woo MM et al.; Ovarian Cancer Research Program of British Columbia. Opportunistic salpingectomy: uptake, risks, and complications of a regional initiative for ovarian cancer prevention. *Am J Obstet Gynecol* 2014; 210: 471.e1–471.e11
- [11] Royal College of Obstetricians & Gynaecologists. The distal fallopian tube as the origin of non-uterine pelvic high-grade serous carcinomas. Scientific Impact Paper No 44 November 2014. Online: <https://www.rcog.org.uk/globalassets/documents/guidelines/scientific-impact-papers/sip44hgscs.pdf>; last access: 19.05.2018
- [12] Kapurubandara S, Qin V, Gurram D et al. Opportunistic bilateral salpingectomy during gynaecological surgery for benign disease: A survey of current Australian practice. *Aust N Z J Obstet Gynaecol* 2015; 55: 606–611
- [13] Pölcher M, Hauptmann S, Fotopoulou C et al. Opportunistic salpingectomies for the prevention of a high-grade serous carcinoma: a statement by the Kommission Ovar of the AGO. *Arch Gynecol Obstet* 2015; 292: 231–234
- [14] Chene G, de Rochambeau B, Le Bail-Carval K et al. Current surgical practice of prophylactic and opportunistic salpingectomy in France. *Gynecol Obstet Fertil* 2016; 44: 377–384
- [15] Parker WH, Feskanich D, Broder MS et al. Long-term mortality associated with oophorectomy compared with ovarian conservation in the nurses' health study. *Obstet Gynecol* 2013; 121: 709–716
- [16] Parker WH, Broder MS, Liu Z et al. Ovarian conservation at the time of hysterectomy for benign disease. *Obstet Gynecol* 2005; 106: 219–226
- [17] Oliver Perez MR, Magriñá J, García AT et al. Prophylactic salpingectomy and prophylactic salpingo-oophorectomy for adnexal high-grade serous epithelial carcinoma: A reappraisal. *Surg Oncol* 2015; 24: 335–344
- [18] Ghezzi F, Cromi A, Siesto G et al. Infectious morbidity after total laparoscopic hysterectomy: does concomitant salpingectomy make a difference? *BJOG* 2009; 116: 589–593
- [19] Repasy I, Lendvai V, Koppan A et al. Effect of the removal of the Fallopian tube during hysterectomy on ovarian survival: the orphan ovary syndrome. *Eur J Obstet Gynecol Reprod Biol* 2009; 144: 64–67
- [20] Vorwergk J, Radosa MP, Nicolaus K et al. Prophylactic bilateral salpingectomy (PBS) to reduce ovarian cancer risk incorporated in standard premenopausal hysterectomy: complications and re-operation rate. *J Cancer Res Clin Oncol* 2014; 140: 859–865
- [21] Minig L, Chuang L, Patrono MG et al. Surgical outcomes and complications of prophylactic salpingectomy at the time of benign hysterectomy in premenopausal women. *J Minim Invasive Gynecol* 2015; 22: 653–657
- [22] Chene G, Meysonnier C, Buenerd A et al. [Feasibility of opportunistic salpingectomy at the time of vaginal hysterectomy for benign pathology and evaluation of occult tubal lesions prevalence: Preliminary study]. *J Gynecol Obstet Biol Reprod (Paris)* 2016; 45: 549–558
- [23] Robert M, Cenaiko D, Sepandj J et al. Success and Complications of Salpingectomy at the Time of Vaginal Hysterectomy. *J Minim Invasive Gynecol* 2015; 22: 864–869
- [24] Venturella R, Morelli M, Lico D et al. Wide excision of soft tissues adjacent to the ovary and fallopian tube does not impair the ovarian reserve in women undergoing prophylactic bilateral salpingectomy: results from a randomized, controlled trial. *Fertil Steril* 2015; 104: 1332–1339
- [25] Yoshida H, Shintani D, Imai Y et al. Serous tubal intraepithelial carcinoma arising from the intrauterine portion of the fallopian tube after bilateral salpingo-oophorectomy. *Eur J Gynaecol Oncol* 2016; 37: 404–406

- [26] Rabban JT, Garg K, Crawford B et al. Early detection of high-grade tubal serous carcinoma in women at low risk for hereditary breast and ovarian cancer syndrome by systematic examination of fallopian tubes incidentally removed during benign surgery. *Am J Surg Pathol* 2014; 38: 729–742
- [27] Sezik M, Ozkaya O, Demir F et al. Total salpingectomy during abdominal hysterectomy: effects on ovarian reserve and ovarian stromal blood flow. *J Obstet Gynaecol Res* 2007; 33: 863–869
- [28] Morelli M, Venturella R, Mociaro R et al. Prophylactic salpingectomy in premenopausal low-risk women for ovarian cancer: primum non nocere. *Gynecol Oncol* 2013; 129: 448–451
- [29] Qin F, Du DF, Li XL. The Effect of Salpingectomy on Ovarian Reserve and Ovarian Function. *Obstet Gynecol Surv* 2016; 71: 369–376
- [30] Venturella R, Lico D, Borelli M et al. 3 to 5 Years Later: Long-term Effects of Prophylactic Bilateral Salpingectomy on Ovarian Function. *J Minim Invasive Gynecol* 2017; 24: 145–150
- [31] McDaniel AS, Stall JN, Hovelson DH et al. Next-Generation Sequencing of Tubal Intraepithelial Carcinomas. *JAMA Oncol* 2015; 1: 1128–1132
- [32] Skorupska KA, Miotta P, Kubik-Komar A et al. Are there any differences in quality of life and sexual functions after various types of hysterectomy - does prophylactic salpingectomy matter? *Ginekol Pol* 2016; 87: 26–31
- [33] Labidi-Galy SI, Papp E, Hallberg D et al. High grade serous ovarian carcinomas originate in the fallopian tube. *Nat Commun* 2017; 8: 1093