

Heads or tails: confusion about “proximal” and “distal” terminology for pancreaticobiliary anatomy



Authors

Harshit S Khara¹, Truptesh H. Kothari², Amitpal S. Johal¹, Shivangi T. Kothari², Nina Ahuja¹, Ashok Bhanushali³, Anil Kotru⁴, Andrea Berger⁵, Vivek Kaul², Seth A. Gross⁶, Christopher J. DiMaio⁷, William B. Hale⁸, Rami Abbass⁹, Marvin Ryou¹⁰, Amrita Sethi¹¹, Brian G. Turner¹², Paul Fockens¹³, David L. Diehl¹

Institutions

- 1 Center for Advanced Therapeutic Endoscopy, Department of Gastroenterology, Geisinger Medical Center, Danville, Pennsylvania, United States
- 2 Division of Gastroenterology and Hepatology, University of Rochester Medical Center, Rochester, New York, United States
- 3 Department of Vascular and Interventional Radiology, Geisinger Medical Center, Danville, Pennsylvania, United States
- 4 Department of Surgery, Geisinger Medical Center, Danville, Pennsylvania, United States
- 5 Department of Biomedical and Translational Informatics, Geisinger Health System, Danville, Pennsylvania, United States
- 6 Department of Gastroenterology, NYU Langone Medical Center, New York, New York, United States
- 7 Division of Gastroenterology, Icahn School of Medicine at Mount Sinai, New York, New York, United States
- 8 Department of Gastroenterology, Norwalk Hospital Gastroenterology Consultants, Norwalk, Connecticut, United States
- 9 Digestive Health Institute, University Hospitals, Cleveland, Ohio, United States
- 10 Division of Gastroenterology, Brigham & Women's Hospital, Boston, Massachusetts United States
- 11 Division of Digestive and Liver Diseases, Department of Medicine, Columbia University Medical Center, New York, New York, United States
- 12 Division of Gastroenterology and Hepatology, Weill Cornell Medical College, Cornell University, New York, New York, United States
- 13 Department of Gastroenterology and Hepatology, Academic Medical Center, University of Amsterdam, Amsterdam, The Netherlands.

submitted 5.1.2018

accepted after revision 5.3.2018

Bibliography

DOI <https://doi.org/10.1055/a-0605-3331> |
Endoscopy International Open 2018; 06: E801–E805
© Georg Thieme Verlag KG Stuttgart · New York
ISSN 2364-3722

Corresponding author

Harshit S. Khara, MD, Clinical Associate Professor of Medicine, Director of Endoscopic and Translational Research, Associate Director, Advanced Therapeutic Endoscopy Fellowship Program, Director, National Pancreas Foundation Center at Geisinger, Center for Advanced Therapeutic Endoscopy, Department of Gastroenterology & Nutrition, Geisinger Medical Center, 100 N. Academy Avenue, 21-11, Danville, PA 17822
Fax: +1-570-271-6852
hskhara@geisinger.edu

ABSTRACT

Background and study aims The anatomical meaning of the terms “proximal” and “distal” in relation to the pancreaticobiliary anatomy can be confusing. We aimed to investigate practice patterns of use of the terms “proximal” and “distal” for pancreaticobiliary anatomy amongst various medical specialties.

Materials and methods An online survey link to a normal pancreaticobiliary diagram was emailed to a multispecialty physician pool. Respondents were asked to label various parts of the common bile duct (CBD) and pancreatic duct (PD) using the terms “proximal,” “distal,” “not sure,” or “other.” Variability in use of these terms between specialties was assessed.

Results We received 370 completed surveys from 182 gastroenterologists (49.2%), 97 surgeons (26.2%), 68 radiologists (18.4%), and 23 other physicians (6.2%). There was overall consensus in describing the upper/sub-hepatic CBD as “proximal CBD” (73.8%, $P=0.1499$) and the lower/pre-ampullary portion as “distal CBD” (84.6%, $P=0.1821$). However, there was marked variability when describing the PD. The PD in the head of the pancreas was labeled as

“proximal PD” by 42.4% and “distal PD” also by 42.4% ($P < 0.0001$); and in the tail as “proximal PD” by 41.4% and “distal PD” by 43.2% ($P < 0.0001$). Only 13.8% of respondents used descriptive terminology (“PD in the head” or “PD in the tail”) for the PD. Radiologists most often used descriptive terminology for both the CBD and PD. Surgeons most consistently called “proximal PD” in the head, and “distal PD” in the tail of the pancreas.

Conclusions Although use of the terms “proximal” and “distal” is still very common to describe pancreaticobiliary anatomy, there is a discordance about its meaning, particularly for the PD. Use of descriptive terminology may be a more accurate alternative to prior ambiguous terminologies such as “proximal” or “distal” and can serve to improve communication and decrease the possibility of medical errors.

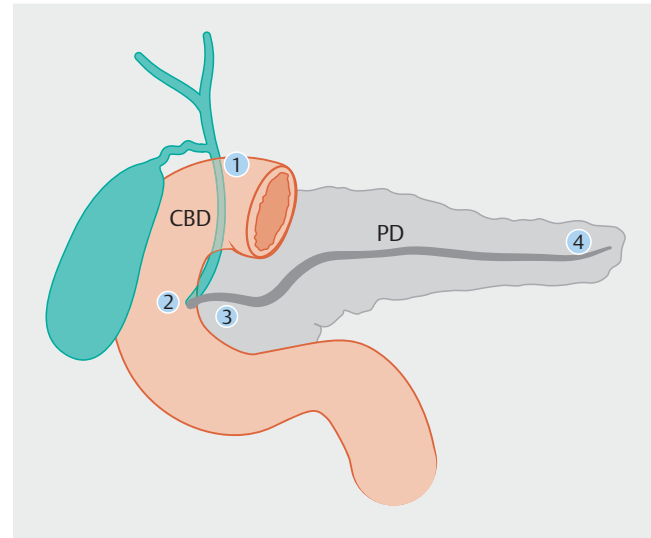
Introduction

“The beginning of wisdom is the definition of terms” – Socrates.

In the practice of Medicine, where crucial treatment decisions are made based on the shared word, a uniform understanding of anatomical terminology is essential. According to the Institute of Medicine (IOM) report from 1999 [1], medical errors cause between 44,000 and 98,000 deaths and over 1 million injuries every year in American hospitals. This study, by highlighting the potential of “To Err is Human,” sparked a movement that has sought to improve and minimize risk of medical errors. After issuance of this report, the rate of patient safety publications increased from 59 to 164 articles per 100,000 MEDLINE publications over a 10-year study period, with articles related specifically to errors in medical communication increasing from 11 to 46 [2].

One important area of confusing terminology is in regard to descriptors of pancreaticobiliary anatomy. “Proximal” and “distal” are commonly used terms for describing the location and position of the common bile duct (CBD) and pancreatic duct (PD). The etymologic derivation of “proximal” and “distal” is from the Latin roots, with “proximus” meaning nearest and “distare” meaning to stand away from. Use of these terms is fairly uniform in almost all parts of the body. However, when used as part of endoscopic, surgical or radiological reporting for describing pancreatic anatomy, variation in use of the terms “proximal” and “distal” can create ambiguity and potentially lead to serious medical errors if misinterpreted.

A literature search found that only one prior publication [3] has addressed this topic. The author surveyed responses to the question of what is proximal and distal in regard to the superior vena cava, internal jugular vein, CBD and PD from 53 health care providers; 24 radiologists and 29 non-radiologists from various surgical and medical specialties. A uniform consensus was found with the terms proximal and distal regarding the superior vena cava, inferior vena cava, and CBD. However, when referring to the proximal versus distal parts of the PD, there was marked discordance in responses. Fifty-seven percent of respondents used the term proximal when referring to the PD in the head while 34% thought this same area was distal, and 9% were unsure. Among radiologists specifically, 54% used the term proximal and 46% distal when referring to the duct within the head of the pancreas. The author concluded that proximal



► Fig. 1 Diagram used to ascertain responses to the online survey.

and distal were appropriate terms when referring to the CBD, but lacked a consensus when referring to the PD.

Materials and methods

We encountered similar clinical confusion in reporting of pancreatic ductal anatomy during endoscopic ultrasound and endoscopic retrograde cholangiopancreatography procedures, which led to a literature review and the genesis of an investigative online survey. A web-based survey (Survey Monkey, San Mateo, California, United States) was created to explore physician usage patterns related to the terms “proximal” and “distal” in labeling the pancreaticobiliary ductal system. The survey included a diagram of the pancreaticobiliary anatomy (► Fig. 1), with the request to label various parts of the CBD and PD using the terms “proximal,” “distal,” “not sure,” or “other” with the option of free text description by the respondents. An online link to the survey was emailed to physicians with a multinational, multicenter, multispecialty participation including gastroenterologists, surgeons, and radiologists amongst others (such as radiation oncology, medical oncology, hepatology, gastrointestinal pathology, etc.), which are the most common specialties using this terminology in their documentation. Respondents were asked to label the areas of the diagram (► Fig. 1) num-

► **Table 1** Overall results study results and breakdown by physician specialty.

	All Respondents (n = 370)		Gastroenterology (n = 182)		Radiology (n = 68)		Surgery (n = 97)		Other (n = 23)	
	n	%	n	%	n	%	n	%	n	%
Q1: What term would you use in your everyday practice to describe the part of the common bile duct (CBD) labeled 1?										
▪ Distal CBD	38	10.3%	16	8.8%	2	2.9%	14	14.4%	6	26.1%
▪ Proximal CBD	273	73.8%	135	74.2%	56	82.4%	67	69.1%	15	65.2%
▪ Not sure	5	1.4%	3	1.6%	0	0.0%	2	2.1%	0	0.0%
▪ Other	54	14.6%	28	15.4%	10	14.7%	14	14.4%	2	8.7%
Q2: What term would you use in your everyday practice to describe the part of the common bile duct (CBD) labeled 2?										
▪ Distal CBD	313	84.6%	159	87.4%	58	85.3%	80	82.5%	16	69.6%
▪ Proximal CBD	28	7.6%	15	8.2%	2	2.9%	7	7.2%	4	17.4%
▪ Not sure	3	0.8%	0	0.0%	0	0.0%	3	3.1%	0	0.0%
▪ Other	26	7.0%	8	4.4%	8	11.8%	7	7.2%	3	13.0%
Q3: What term would you use in your everyday practice to describe the part of the pancreatic duct (PD) labeled 3?										
▪ Distal PD	157	42.4%	85	46.7%	25	36.8%	37	38.1%	10	43.5%
▪ Proximal PD	157	42.4%	72	39.6%	19	27.9%	55	56.7%	11	47.8%
▪ Not sure	3	0.8%	0	0.0%	0	0.0%	3	3.1%	0	0.0%
▪ Other	53	14.3%	25	13.7%	24	35.3%	2	2.1%	2	8.7%
Q4: What term would you use in your everyday practice to describe the part of the pancreatic duct (PD) labeled 4?										
▪ Distal PD	160	43.2%	75	41.2%	18	26.5%	56	57.7%	11	47.8%
▪ Proximal PD	153	41.4%	82	45.1%	25	36.8%	35	36.1%	11	47.8%
▪ Not sure	3	0.8%	0	0.0%	0	0.0%	3	3.1%	0	0.0%
▪ Other	54	14.6%	25	13.7%	25	36.8%	3	3.1%	1	4.3%

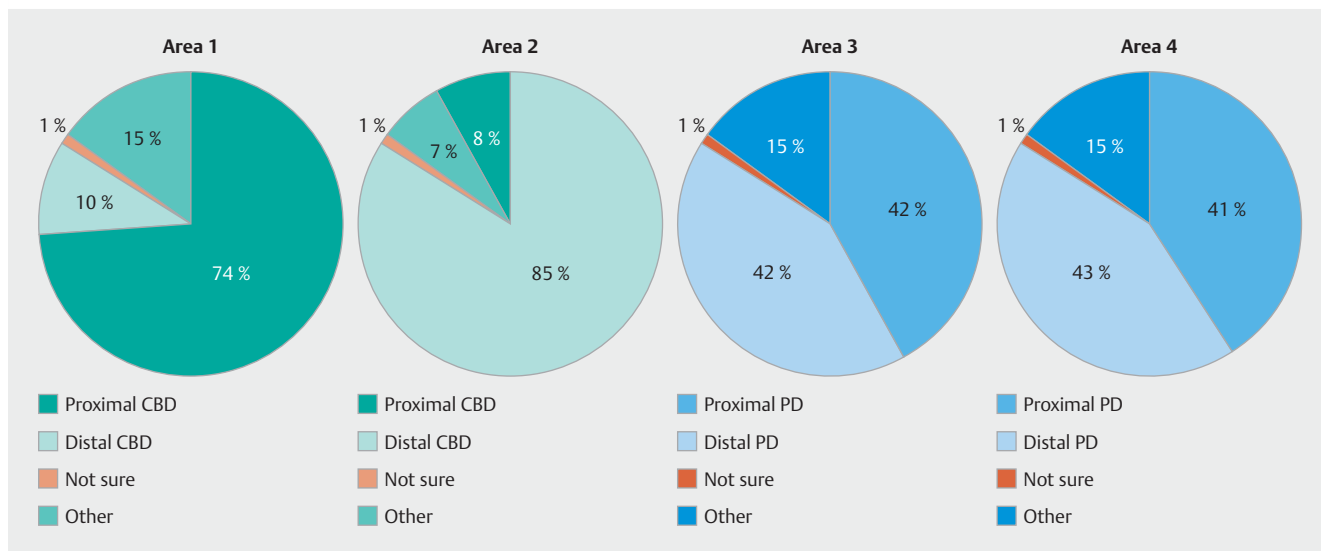
bered as area 1, 2, 3 and 4. Area 1 is the area of the CBD below the liver continuing from the common hepatic duct. Area 2 is the part of the CBD just above the ampulla as it enters the duodenum. Area 3 is the area of the main pancreatic duct traversing the region of the head of the pancreas before entering the ampullary orifice. Area 4 is the area of the main pancreatic duct traversing the region of the tail of the pancreas. The survey queried only normal pancreaticobiliary anatomy and did not include any altered anatomy conditions such as pancreas divisum or anomalous pancreaticobiliary junction. Survey responses were summarized using frequency counts and percentages. Responses from gastroenterologists, surgeons, and radiologists were compared using Pearson's chi-square or Fisher's exact tests. Statistical analysis was performed in SAS 9.4. Fisher's exact test was used to test the association between two categorical variables when there were small frequencies or instances of zero in a 2x2 table. Otherwise, chi-square tests were used.

Results

Three hundred seventy completed surveys were received and analyzed. Respondents included 182 gastroenterologists (49.2% of respondents), 97 surgeons (26.2%), 68 radiologists (18.4%), and 23 other physicians (6.2%) from radiation oncology, medical oncology, and surgical pathology. ► **Table 1** details the overall responses for each area, as well as responses broken down by physician specialty.

The results showed that as whole, respondents did not show marked difference in their labeling for parts of the CBD (► **Fig. 2**), with area 1 predominantly labeled as proximal CBD (73.8%) and area 2 predominantly as distal CBD (84.6%). This held true even when broken down by physician specialty for gastroenterologists v/s surgeons v/s radiologists for area 1 ($P=0.1499$), and area 2 ($P=0.1821$).

However, there was marked discordance in responses with respect to the PD (► **Fig. 2**). The PD in the head of the pancreas (area 3) was labeled as the "proximal PD" by 42.4% of respondents, whereas 42.4% also labeled this same area as the "distal PD." Similarly, in regard to labeling the PD in the tail of the pancreas (area 4), 41.4% of respondents referred to this area as the "proximal PD" in comparison to 43.2% of respondents that la-



► Fig. 2 Response results for areas 1, 2, 3, and 4.

beled this as the “distal PD.” This discordance was evident when broken down by physician specialty for gastroenterologists v/s surgeons v/s radiologists for area 3 ($P < 0.0001$), and area 4 ($P < 0.0001$). The surgeons overall more consistently labeled the PD anatomy as compared to the gastroenterologists and radiologists, for area 3 in the head of the pancreas as “proximal PD” (56.7% v/s 39.6% v/s 27.9%, $P = 0.0020$); and area 4 in the tail of the pancreas as “distal PD” (57.7% v/s 41.2% v/s 26.5%, $P = 0.0009$), as detailed in ► Table 2.

Overall, only 13.8% of all physicians used descriptive terminology such as “PD in the head/PD in the tail,” and “downstream/upstream PD” for labeling both sites of the PD (areas 3 & 4) instead of the terms proximal or distal. Of all the respondents, radiologists most often used descriptive terminology as compared to the gastroenterologists and surgeons when referring to the CBD (13.2% v/s 9.8% v/s 10.8%, $P = 0.0404$), as well as the PD (36% v/s 13.7% v/s 2.6%, $P < 0.0001$).

► Table 2 Subgroup analysis of the PD responses by physician specialty for areas 3 and 4.

	Area 3 – Proximal	Area 3 – Distal	Area 4 – Proximal	Area 4 – Distal
Surgeons (n = 97)	57%	38%	36%	58%
Gastroenterologists (n = 182)	40%	47%	45%	41%
Radiologists (n = 68)	28%	37%	37%	27%

Discussion

Our results underscore the fact that although use of the terms “proximal” and “distal” is still very common amongst various specialties for describing pancreaticobiliary anatomy, there seems to be a discordance about its meaning, with the most ambiguity being in reference to the pancreatic ductal system.

“Proximal” and “distal” are core anatomical terms, usually used in reference to the limbs. Gray’s Anatomy [4] states “Distal and proximal are used particularly to describe structures in the limbs, taking the datum point as the attachment of the limb to the trunk (sometimes referred to as the root), such that a proximal structure is closer to the attachment of the limb than a distal structure. However, proximal and distal are also used in describing branching structures, e.g. bronchi, vessels and nerves.” Thus, their use for structures within the trunk leads to major confusion, as evident in our study.

Respondents provided several justifications for their choice of terms in our study questionnaire. One common reason was that the terms for the CBD and PD were related to the flow within these structures. This justifies the majority of the responses in reference to the CBD, where bile flows from the liver to the ampulla, thus the upper part of the CBD (area 1 in our study) could be labeled “proximal CBD” and the lower part (area 2) could be labeled “distal CBD”. Furthermore, the upper part of the CBD (area 1) is closer to the core of the trunk, thus more “proximal”, and the lower part (area 2) would be farther out, thus more “distal”, as the CBD lies vertically within the trunk.

However, this theory leads to major confusion when addressing the PD. The flow of the pancreatic secretions is from the tail of the pancreas towards the head of the pancreas. Accordingly, some respondents labeled the PD in the tail (area 4) as “proximal PD” and the PD in the head (area 3) as “distal PD”. We can see how this strikingly contradicts use of these terms

while describing the same areas in the surgical field, where the resection of the tail of the pancreas is termed “distal pancreatectomy.” This may have been the reasoning why our surgical respondents provided more consistent proximal-distal labeling of the pancreatic ductal anatomy as compared to the gastroenterologists and radiologists, who had a more discordant view. Another explanation for this was that the term “head” is usually used in the proximal/cranial context and the term “tail” is usually used in a distal/caudal context. The PD also traverses a primarily horizontal course within the trunk, thus its location cannot be used in a proximal-distal orientation in relation to its distance from the core of the body.

Surprisingly, although there was a majority consensus about CBD nomenclature, there was not uniform consensus, as we would have expected (► **Fig. 2**). Seventy-four percent of total respondents labeled area 1 as the “proximal CBD” and 85% of total respondents labeled area 2 as the “distal CBD.” This highlights the fact that even when it comes to presumably more straightforward CBD nomenclature, there remains a small subgroup of physicians with discordant views about use of the terms “proximal” or “distal.” Similar confusion may occur when attempting to describe the ends of biliary or pancreatic stents.

The terms “proximal” and “distal” in relation to the CBD and PD were extensively used in a previous article in *Radiographics* [5], where they referred to the CBD near the ampulla as the distal CBD, but the PD in the tail as distal PD. This provoked comment and interesting discussion [6] that the terms had been used erroneously, and suggested use of more descriptive, explicit terminology such as “the pancreatic duct in the head or body or tail.” Subsequent response from the authors [7] stated that there is widespread use of these terms by most surgeons in daily practice, and in the surgical literature, the term “distal” would unanimously refer to the PD in the tail of the pancreas as evidenced by their PubMed search on the term distal pancreatectomy. This is just one example of how this particular topic can cause confusion and differing opinions in medical practice and medical literature.

Conclusion

In today’s era of multidisciplinary management of patients, it is imperative to use uniform terminology when describing anatomical locations. With the advent of the electronic health record system, communication, in theory at least, has improved. However, it is even more important now to not only have institutional uniformity, but also multi-national and multi-specialty concordance of descriptive terminology to avoid ambiguous communication. Use of descriptive terminology such as “PD in the head” and “PD in the tail” may be a safer, more accurate, and meaningful alternative to prior ambiguous terminologies such as “proximal” or “distal.” With this type of explicit terminology regarding the PD, there is an opportunity to improve communication in medical reporting, with the potential of reducing medical errors.

Competing interests

None

References

- [1] Kohn LT, Corrigan JM, Donaldson MS (Institute of Medicine) *To err is human: building a safer health system*. Washington, DC: National Academy Press; 2000
- [2] Stelfox HT, Palmisani S et al. The “To Err is Human” report and the patient safety literature. *Qual Saf Health Care* 2006; 15: 174–178
- [3] Skillicorn CJ. Do the terms “proximal” and “distal” cause confusion amongst radiologists and other clinicians? *Clin Radiol* 2009; 64: 397–402
- [4] Anatomical nomenclature. In: Standring S (editor). *Gray’s Anatomy: The Anatomical Basis of Clinical Practice*. 41st ed. Philadelphia: Elsevier; 2016: xvi–xvii
- [5] Yamauchi FI, Ortega CD, Blasbalg R et al. Multidetector CT evaluation of the postoperative pancreas. *Radiographics* 2012; 32: 743–764
- [6] Winter TC 3rd. “Proximal” versus “distal” in the pancreas. *Radiographics* 2013; 33: 622–623
- [7] Yamauchi FI, Ortega CD, Blasbalg R et al. Dr Yamauchi and colleagues respond. *Radiographics* 2013; 33: 623