

Endoscopic biodegradable stents as a rescue treatment in the management of post bariatric surgery leaks: a case series

OPEN
ACCESS

Authors

Abed Al Lehibi, Areej Al Balkhi, Abdullah Al Mtawa, Nawaf Al Otaibi

Institution

Gastroenterology and Hepatology Department, King Fahad Medical City, Riyadh, Saudi Arabia

submitted 31.12.2017

accepted after revision 2.2.2018

Bibliography

DOI <https://doi.org/10.1055/a-0600-9562> |

Endoscopy International Open 2018; 06: E722–E726

© Georg Thieme Verlag KG Stuttgart · New York

ISSN 2364-3722

Corresponding author

Abed Al Lehibi, MD, P.O. Box 59046, Riyadh 11525, Kingdom of Saudi Arabia

Fax: +966-11-2889999, ext. 8361

aallehibi@kfmc.med.sa

ABSTRACT

Background and aims Postoperative leak is one of the most feared complications after bariatric surgery. Endoscopic stenting is used to manage leaks by decreasing the gastrointestinal intraluminal pressure. The main advantage of endoscopic management is providing healing while still allowing for oral nutrition. However, limited literature ex-

ists on whether biodegradable stents can be used to control leaks when conventional metallic stents fail.

Methods Our series consists of four patients who were found to have a leak as a complication of bariatric surgery. Two patients were initially managed by abdominal/chest drainage, and one required total parenteral nutrition. Conventional endoscopic exclusion techniques with short and long fully covered metallic stents were tried and failed in three of the four patients included in this series. Thus, biodegradable stents were used as a rescue option.

Results Biodegradable stents provided immediate improvement for all of the patients, and Gastrografin studies were leak-free 2 days after the procedure. All patients were started on oral feeding and discharged home within 5–6 days later. Minimum outpatient follow-up of 8 weeks was achieved with no issues. Follow-up endoscopy was performed 2–3 months later in three patients and showed completely resorbed stents. The only drawback was the mucosal reaction to the stent causing dysphagia in two patients, who eventually needed esophageal dilatation.

Conclusion Biodegradable stents have the potential to provide a reasonable rescue option to manage post bariatric surgery leaks in patients who fail conventional endoscopic exclusion methods. However, data from larger studies are needed to collect information on which theoretical advantages/disadvantages of degradable biomaterials apply to real practice.

Introduction

Over the past few decades, gastric bypass and sleeve gastrectomies have become popular procedures in the management of morbid obesity [1]. However, despite being relatively safe for weight loss, leakage remains one of the most feared complications after both operations and can lead to significant morbidity and mortality [2–4]. The management options vary between immediate surgical intervention, endoscopic intervention (closure of the leakage site or stenting), and conservative management depending mainly on the patient's clinical condition, as well as the time of onset in which the leak is identified. Endoscopic stenting was initially proposed to treat postopera-

tive anastomotic strictures/stenoses [4]. But as it was shown to decrease intraluminal pressure, it was suggested that it may play an effective role in the management of leaks as well.

One of the main advantages of endoscopic management is providing healing while still allowing for oral nutrition [5]. However, the use of fully covered, self-expandable, metallic stents (FCSEMS) in endoscopic management brings a number of concerns, such as stent migration, tissue ingrowth, impaired underlying tissue oxygenation when the stent is kept for long periods of time, and the need for repetitive endoscopic interventions to reposition or remove the stent [4–6]. The use of degradable biomaterials may decrease/eliminate some of these risks. In this paper, we report a series of four patients in whom

biodegradable stents were used for the treatment of leakage post gastric bypass/sleeve gastrectomy.

Endoscopic stents used in this series

In the first three patients who had a staple line leak after laparoscopic sleeve gastrectomy, Niti-S MEGA (TaeWoong Medical, Seoul, South Korea) fully-covered, metallic esophageal stents (diameter 24 mm; length 180 mm) were used. SX-ELLA Esophageal Degradable BD-BD (ELLA-CS, Trebes, Hradec Králové, Czech Republic), non-covered, esophageal, biodegradable stents (diameter: body 23 mm, flares 28 mm; length 100 mm) were used as a rescue treatment when metal stents had been tried and failed.

Case presentation

Case 1

A 56-year-old woman with hypothyroidism and type II diabetes mellitus who had a sleeve gastrectomy with Billroth II gastrojejunostomy in an outside institution, was discovered to have a leak 2 weeks after the procedure. The patient was admitted for further work-up and possible endoscopic/surgical intervention. Her first CT image showed a collection in the subdiaphragmatic region. The patient was started on supportive measures, a drain was inserted, and an esophagogastroduodenoscopy (EGD) was done. EGD showed erythema, edema, and inflammatory changes at the site of the Billroth II anastomosis and the staple line of the sleeve. A fully-covered self-expandable metal stent (FCSEMS) was inserted 35 cm away from the incisors, and the patient was returned to the ward for ongoing care. Nonetheless, she did not improve, and the leak started to cause complications as noted by abnormal kidney function (acute kidney injury). A gastrografen study was performed and showed that there was persistent leakage in the proximal stomach. EGD was repeated and revealed migration of the stent and ulcerative changes along the sleeve line. Therefore, the stent was repositioned, but another gastrografen study demonstrated that the extent of the leak had not changed; the metal stent was removed 3 days later and replaced with a 100-mm-long biodegradable one (▶ **Video 1**). No further leakage was identified on imaging after the procedure. The patient returned to an oral diet a few days later and was discharged shortly afterwards. Upon her 3-month follow-up, she presented to the clinic with dysphagia. Another endoscopy was performed and showed a completely resorbed stent and a healthy anastomosis line, but a diffuse granulation tissue with a benign appearing, severe stenosis in the lower third of the esophagus. This required two dilatation attempts, one done during the same procedure, and the second performed 2 weeks later. The patient then completed 14 months of follow-up with no complaints or need for any further intervention.

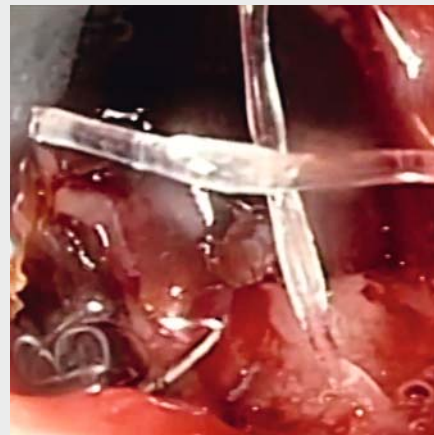
Case 2

This is a 39-year-old woman who was discovered to have a leak after gastrografen studies during the intermediate period (5–6 days) post sleeve gastrectomy. She was initially managed with

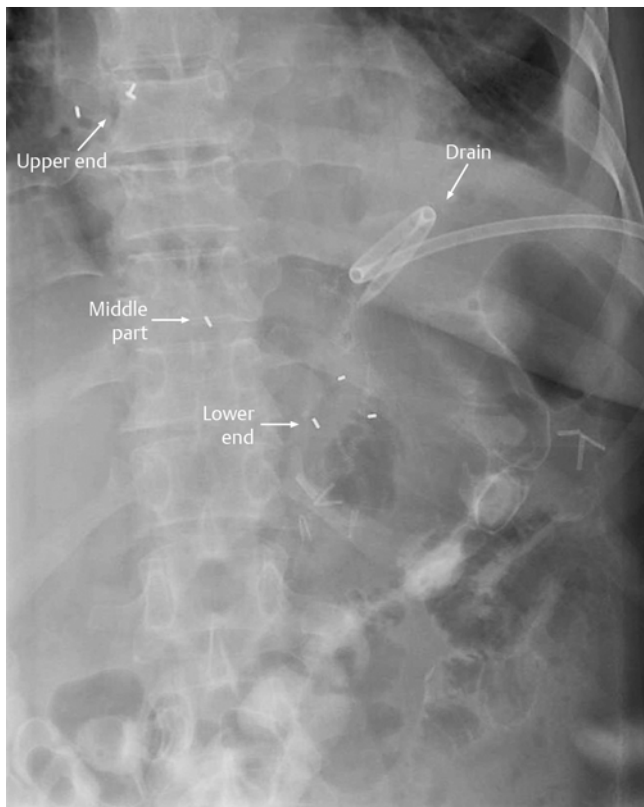
an endoscopic metal stent (FCSEMS) and draining the collection. However, she did not show any response, and gastrografen images still demonstrated an area of contrast leakage in the mid and proximal stomach. Therefore, the stent was removed, and EGD was repeated 2 days later to show congestion, erythema, and inflammation along the staple line, as well as a large, leaking gastric fistula which was clipped during this procedure. A 100-mm-long biodegradable stent was also placed 25 cm away from the incisors (▶ **Fig. 1**), and the patient started to improve and take nutrition orally 3 days later. A follow-up barium meal was administered 6 weeks after insertion and showed no leak. However, due to her complaining of gastroesophageal reflux disease (GERD) symptoms, a gastroscopy was performed. The leak was closed (▶ **Fig. 2**); however, the site of the biodegradable stent was covered with ingrown tissue, which was benign looking and causing a moderate intrinsic stenosis in the lower esophagus. The gastroscopist could not be passed during this procedure, so it was repeated the day after and ended with successful dilatation. The patient completed a follow-up to 8 months afterward with no issues.

Case 3

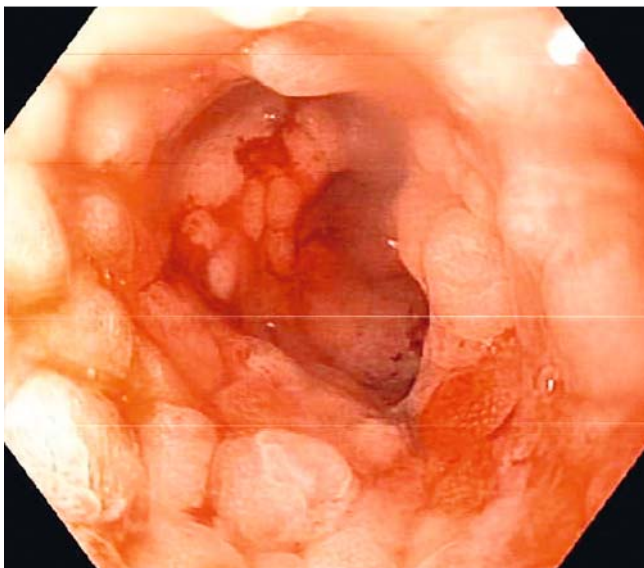
The third case is a 35-year-old woman who presented with a leak a month after sleeve gastrectomy in an outside hospital. The patient was initially managed in her original center with abdominal and chest drainage, total parenteral nutrition, and endoscopic metallic stenting. The leak was controlled in the beginning, but the patient returned to being febrile a week later. In our hospital, we continued the same supportive manage-



▶ **Video 1** Removal of metal stent and replacement with a 100-mm-long biodegradable one. 00:04 Endoscopic view of the jejunum and the mucosal reaction to the previous fully-covered metal stent. 00:11 Clips seen at the gastrojejunal anastomosis (Billroth II gastrojejunostomy). 00:17 Normal gastric antrum. 00:20 Normal duodenal mucosa. 00:27 Pus coming from the leakage site close to the gastroesophageal junction (proximal stomach). 01:03 Large defect at the proximal stomach leaking into the peritoneum. 01:31 The guiding wire being introduced up to the jejunum in preparation for biodegradable stent delivery. 01:34 Biodegradable stent in place covering the leakage site.

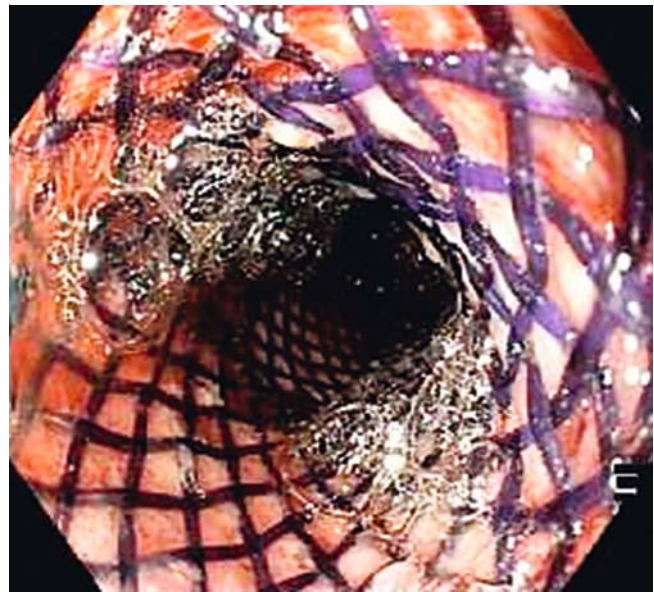


► **Fig. 1** Contrast study showing the position of the biodegradable stent as marked by the arrows.



► **Fig. 2** Final endoscopic image showing complete closure of the leak. It also shows the mucosal reaction to the stent which caused a benign looking, moderate esophageal stenosis.

ment and repeated her gastrografen study, which showed a persistent leak at the gastroesophageal junction. Nevertheless, our attempts to control her condition with FCSEMS failed twice, so a 100-mm-long biodegradable stent was used as a rescue option. Three days after the procedure, no further leakage was



► **Fig. 3** Endoscopic view of the biodegradable stent.

seen on contrast studies and the patient was discharged home on an oral diet 5 days later. Similar to what happened with our patient in Case 2, another endoscopy was performed after 8 weeks due to the patient complaining of GERD symptoms. The stent was seen to be covered with granulation tissue, and argon plasma coagulation (APC) was carried out to debulk these changes. Four-month follow-up was completed successfully with no further complications.

Case 4

The last patient is a 35-year-old man who was planned for a Roux-en-Y gastric bypass in our hospital. Three weeks after surgery, signs of postoperative leakage started to show. His initial CT images and gastrografen studies were highly indicative of contrast leakage at the site of the gastric anastomosis. Therefore, he was managed by draining the collection, and an endoscopic assessment was requested. EGD showed a disrupted staple line with ulcerative changes involving the gastrojejunal anastomosis and extending to the alimentary jejunal limb. Due to the small size of the gastric pouch, neither long nor short metallic stents could be placed, so the procedure was repeated 2 days later and a 100-mm-long biodegradable stent was successfully inserted (► **Fig. 3**). No evidence of contrast leakage was seen on subsequent imaging, and the patient was discharged on an oral diet a few days later. He completed a follow-up of 8 weeks with no issues or complaints.

Discussion

Postoperative leak is one of the most feared complications after bariatric surgery [2–4]. It can occur because of mechanical causes (direct tissue injury) or aggressive tissue dissection (ischemic causes) [4]. Many authors recommend gentle handling of the tissues and staple line reinforcement as methods of prevention, but leakage remains a concern that can affect the

postoperative course in up to 5% of patients [7]. Endoscopic management varies between direct closure techniques (clipping or fibrin glue), or placement of endoprosthesis stents [3, 4]. The latter approach used to be adopted for the treatment of anastomotic strictures. Nevertheless, stents may also play an effective role in decreasing the leakage by relieving the intraluminal pressure, and they have been shown to bring an immediate symptomatic relief and to provide healing while still allowing the patient to return to an oral diet [5].

However, despite the impressive response to metallic stents that has been shown in previous studies, some patients may still need an alternative option. Our series described four patients (three women) who were found to have a leak as a complication of sleeve gastrectomy or Roux-en-Y gastric bypass, and three of them failed the conventional endoscopic exclusion techniques with fully-covered, self-expandable, metallic stents (FCSEMS). Biodegradable stents were successfully used as a rescue option and provided clinical advantages similar to those offered by metallic ones. The only drawback we faced during our experience was the mucosal reaction to the stent in two patients, mandating the need for esophageal dilatation.

Endoscopic stents are usually able to effectively seal any leak to facilitate healing while still allowing food particles and secretions to pass. Their reported success rate in managing acute leaks after bariatric surgery is 50–89% [5, 11]. To our knowledge, not many studies have addressed the issue of when, and why, FCSEMS may fail, but one of the major reasons to be considered is the high migration index that approaches 58% in some series, with comparable risk in metallic and polyester stents [4, 5]. Although migrations observed in this series were a few centimeters, they were sufficient to uncover the site of the leak, which compromised healing and explained why they were unsuccessful when tried in three of our patients. As for our patient in Case 4, we opted for a biodegradable stent as a first option because he was the only one who had an anastomotic leak after gastric bypass surgery. FCSEMS are not designed for placement in a gastric pouch. For the stent to be stable in place, we need to ensure a good amount of friction between the stent and the mucosal surface. This is feasible when the stent is placed in the esophagus after a sleeve gastrectomy. When placed across a gastrojejunal anastomosis, however, a considerable length of the stent is left with no contact with the mucosal surface, particularly at the gastric pouch, which may contribute to a higher risk of migration in bypass cases [5].

The use of degradable biomaterials for medical applications is not new [6]. The biodegradable cardiovascular stent market has dominated this field of medical research for years, and many of its products are being reported in the stages of post-marketing surveys [6, 8, 9]. Clinical experience with these stents in gastrointestinal applications has also been expanding and showing promising results over the past few years (e.g., benign esophageal strictures, achalasia, and postoperative intestinal and colonic strictures) [6, 10]. The main advantage of using uncovered biomaterials in the manufacturing of biodegradable stents is ensuring a more stable positioning, thus reducing the risk of migration. But other clinical advantages include limiting the immune response and the mucosal reaction

to the stent, less carcinogenicity, teratogenicity, and toxicity. And since these materials are naturally degraded by the patient's immune system, they would limit the need for frequent endoscopic interventions to replace, reposition, or remove the stent. However, one needs to keep in mind that many of these advantages are theoretically assumed because of the inherent qualities of biomaterials, and a case series does not provide enough information on the practicality of using them as the standard of care. For example, one of the leading practical concerns about biomaterials is the possibility of losing the stent's integrity/radial force with time. Additionally, the cost of these stents may remain a significant limitation that can restrict their widespread adoption for gastrointestinal applications [6].

In conclusion, although a case series does not establish conclusive evidence of their non-inferiority or superiority, biodegradable stents may still provide a reasonable rescue alternative to manage post bariatric surgery leaks in patients who fail conventional endoscopic exclusion methods. In our experience, stent migration and loss of radial force did not limit the clinical advantages observed in our patients. However, data from more extensive studies are needed to examine which theoretical advantages/disadvantages of degradable biomaterials apply to real practice.

Competing interests

None

References

- [1] Buchwald H, Avidor Y, Braunwald E et al. Bariatric surgery: a systematic review and meta-analysis. *JAMA* 2004; 292: 1724–1737 [Review. Erratum in: *JAMA* 2005; 293: 1728]
- [2] Lalor PF, Tucker ON, Szomstein S et al. Complications after laparoscopic sleeve gastrectomy. *Surg Obes Relat Dis* 2008; 4: 33–38
- [3] Sakran N, Goitein D, Raziell A et al. Gastric leaks after sleeve gastrectomy: a multicenter experience with 2,834 patients. *Surg Endosc* 2013; 27: 240–245
- [4] Abou Rached A, Basile M, El Masri H. Gastric leaks post sleeve gastrectomy: Review of its prevention and management. *World J Gastroenterol* 2014; 20: 13904–13910
- [5] Eubanks S, Edwards CA, Fearing NM et al. Use of endoscopic stents to treat anastomotic complications after bariatric surgery. *J Am Coll Surg* 2008; 206: 935–938; discussion 938–939
- [6] Lorenzo-Zúñiga V, Moreno-de-Vega V, Marín I et al. Biodegradable stents in gastrointestinal endoscopy. *World J Gastroenterol* 2014; 20: 2212–2217
- [7] Csendes A, Braghetto I, León P et al. Management of leaks after laparoscopic sleeve gastrectomy in patients with obesity. *J Gastrointest Surg* 2010; 14: 1343–1348
- [8] Mattesini A, Secco GG, Dall'Ara G et al. ABSORB biodegradable stents versus second-generation metal stents: a comparison study of 100 complex lesions treated under OCT guidance. *JACC Cardiovasc Interv* 2014; 7: 741–750
- [9] Han Y, Jing Q, Li Y et al. Multi-Center Registry of EXCEL Biodegradable Polymer Drug Eluting Stents (CREATE) investigators. Sustained clinical safety and efficacy of a biodegradable-polymer-coated sirolimus-eluting stent in “real-world” practice: three-year outcomes of the

- CREATE (Multi-Center Registry of EXCEL Biodegradable Polymer Drug Eluting Stents) study. *Catheter Cardiovasc Interv* 2012; 79: 211 – 216
- [10] Repici A, Vleggaar FP, Hassan C et al. Efficacy and safety of biodegradable stents for refractory benign esophageal strictures: the BEST (Biodegradable Esophageal Stent) study. *Gastrointest Endosc* 2010; 72: 927 – 934
- [11] Praveenraj P, Gomes RM, Kumar S et al. Management of gastric leaks after laparoscopic sleeve gastrectomy for morbid obesity: a tertiary care experience and design of a management algorithm. *J Minim Access Surg* 2016; 12: 342 – 349