Thieme

Peroral endoscopic myotomy as a versatile approach to treating complex esophageal disorders

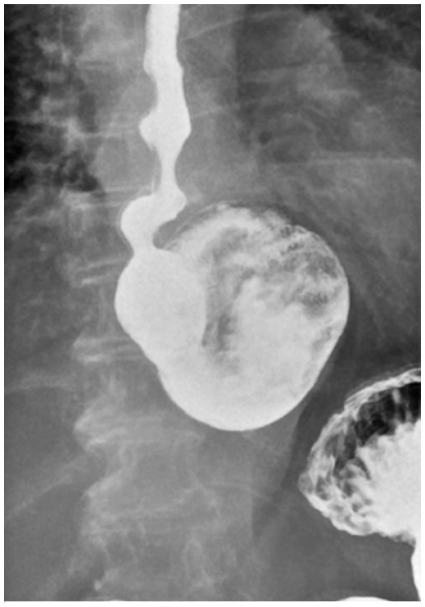

▶ **Fig. 1** Barium study showing a large distal esophageal diverticulum and multiple tertiary contractions, suggesting the diagnosis of Jackhammer esophagus.

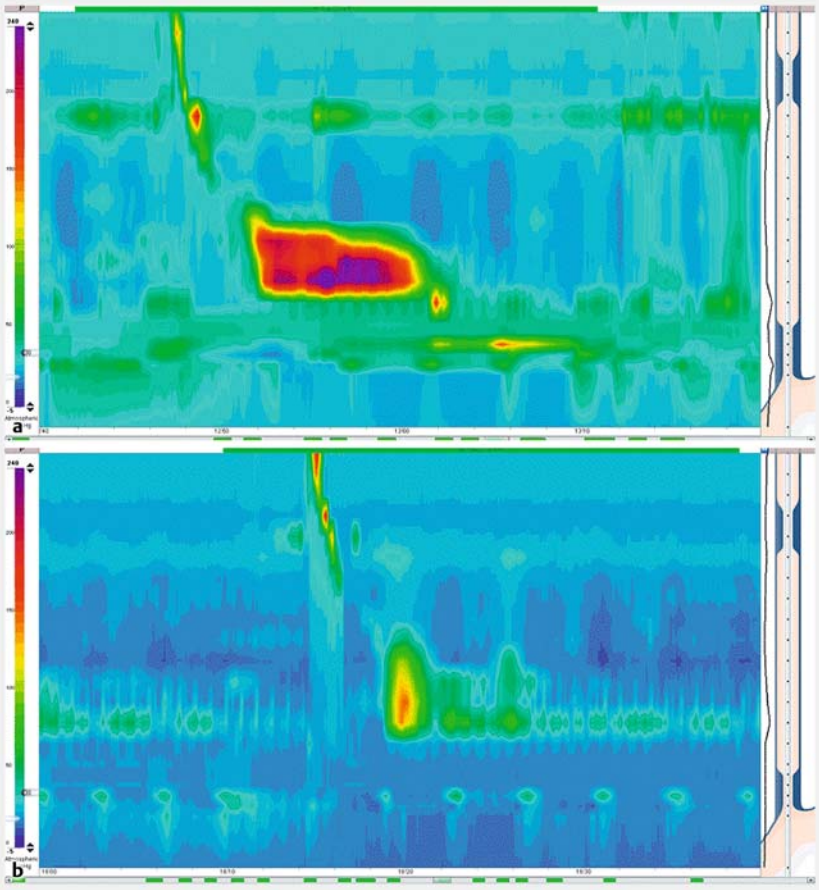

▶ **Fig. 2** High resolution manometry. **a** Before treatment. Confirmed diagnosis of Jackhammer esophagus and distal esophageal spasm (50 % premature contractions; 60 % high amplitude contractions; distal contractile integral 8051 mmHg.s.cm; lower esophageal sphincter (LES) pressure 11 mmHg; integrated relaxation pressure 4 s: 5 mmHg.s.cm; 4 cm hiatal hernia). **b** 1 month follow-up after treatment, showing a significant improvement in the esophageal wall muscle and LES contractility (0 % premature contractions; 20 % high amplitude contractions; distal contractile integral 4616 mmHg.s.cm; LES pressure 4 mmHg; integrated relaxation pressure 4 s: 1 mmHg).

Since 2008, peroral endoscopic myotomy (POEM) has evolved as a technique for managing esophageal achalasia [1]. POEM has also recently emerged as a potential therapeutic tool in treating other esophageal motility disorders [2, 3], including Jackhammer esophagus and Zenker's diverticulum [4]. However, for mid or lower esophageal diverticulum, the surgical treatment is still recommended, despite being associated with high morbidity. In this video case we report the application of the POEM technique as a therapeutic approach in a patient affected by Jackhammer esophagus, distal esophageal spasm, and a large distal esophageal diverticulum (▶ **Fig. 1**, ▶ **Fig. 2 a**).

The aim of this POEM variation was to create a submucosal tunnel as a single access both to the diverticular septum, to perform septotomy, and to the esophageal wall muscle and lower esophageal sphincter (LES), in order to perform myotomy (▶ **Fig. 3**, ▶ **Video 1**).

Compared with the classical POEM procedure, five phases were defined. After mucosa incision and submucosal tunneling, the myotomy was performed as a hybrid technique. Initially, an anterograde section of the esophageal wall muscle was dissected, starting from the fibers below the diverticular septum, progressing downstream, and ending in the stomach, beyond the LES section. Next, a retrograde septotomy was performed, beginning from the most distal septal fibers and working toward the proximal ones. At the end, the tunnel entry was sealed using hemostatic clips.

This case report shows that POEM is versatile, safe, effective (▶ **Fig. 2 b**), and minimally invasive. Its evaluation as a therapeutic tool in patients having mid or distal esophageal symptomatic diverticulum, whether associated with motility disorders or not, should be encour-

This document was downloaded for personal use only. Unauthorized distribution is strictly prohibited.

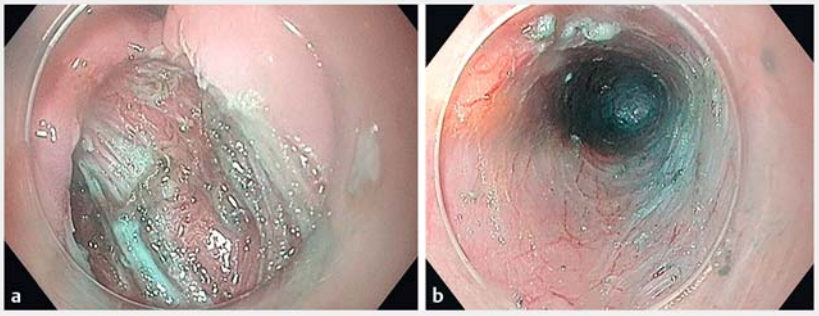

▶ **Fig. 3** Endoscopic images. **a** Anatomical relation between the septal fibers and the mucosa flaps at the tunnel entrance. **b** Submucosal tunnel.

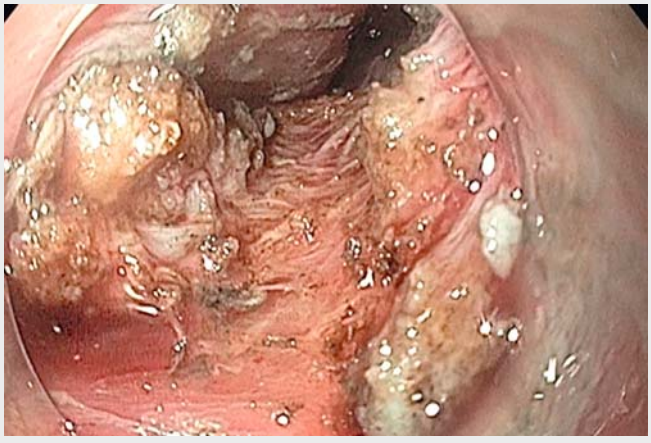

Video 1 A modified peroral endoscopic myotomy technique as a therapeutic approach for treating, with a single submucosal tunnel, a complex case combining Jackhammer esophagus, distal esophageal spasm, and a large distal esophageal diverticulum.

aged. However, despite the low rate of overall morbidity and mortality reported for conventional POEM [5], it should be carefully customized to each specific case, in order to reduce the risks of potential complications.

Endoscopy_UCTN_Code_TTT_1AO_2AN

Competing interests

Marc Barthet receives research grant from Boston Scientific. Guido Costamagna receives research grants from Boston Scientific, CooK Endoscopy and Olympus. No further conflicts of interest to disclose.

The authors

Antonella Putignano[1], Marc Barthet[2], Ricardo Rio-Tinto[3], Guido Costamagna[4], Hubert Louis[1], Vincent Huberty[1], Arnaud Lemmers[1], Jacques Devière[1]

1 Department of Gastroenterology and Hepatopancreatology, Erasme University Hospital, Université Libre de Bruxelles, Brussels, Belgium
2 Department of Gastroenterology, Hôpital Nord, Aix Marseille Université, Marseille, France
3 Digestive Diseases Unit, Champalimaud Clinical Centre, Lisbon, Portugal
4 Digestive Endoscopy Unit, Fondazione Policlinico Universitario A. Gemelli, IRCCS, Rome, Italy

Corresponding author

Antonella Putignano, MD
Department of Gastroenterology, Hepatopancreatology, and Digestive Oncology, Erasme Hospital, 808, route de Lennik, Bruxelles 1070, Belgium
Fax: +32-2-5554697
antonella.putignano@erasme.ulb.ac.be

This document was downloaded for personal use only. Unauthorized distribution is strictly prohibited.

Acknowledgment

We would like to thank all the professionals who helped to realise this video during the 35th edition of the Gastroenterology and Endotherapy European Workshop (GEEW, Brussels 2017).

References

[1] Inoue H, Minami H, Kobayashi Y et al. Peroral endoscopic myotomy (POEM) for esophageal achalasia. Endoscopy 2010; 42: 265 – 271

[2] Mu D, Li YY, Zhang MM et al. POEM for special patient cohorts: a review. J Dig Dis 2017; 18: 265 – 272

[3] Louis H, Covas A, Coppens E et al. Distal esophageal spasm treated by peroral endoscopic myotomy. Am J Gastroenterol 2012; 107: 1926 – 1927

[4] Li QL, Chen WF, Zhang XC et al. Submucosal tunneling endoscopic septum division: a novel technique for treating Zenker's diverticulum. Gastroenterology 2016; 151: 1071 – 1074

[5] Bechara R, Ikeda H, Inoue H. Peroral endoscopic myotomy: an evolving treatment for achalasia. Nat Rev Gastroenterol Hepatol 2015; 12: 410 – 426

Bibliography
DOI https://doi.org/10.1055/a-0600-9529
Published online: 9.5.2018
Endoscopy 2018; 50: E172–E174
© Georg Thieme Verlag KG
Stuttgart · New York
ISSN 0013-726X

ENDOSCOPY E-VIDEOS
https://eref.thieme.de/e-videos

Endoscopy E-Videos is a free access online section, reporting on interesting cases and new techniques in gastroenterological endoscopy. All papers include a high quality video and all contributions are freely accessible online.

This section has its own submission website at https://mc.manuscriptcentral.com/e-videos

This document was downloaded for personal use only. Unauthorized distribution is strictly prohibited.