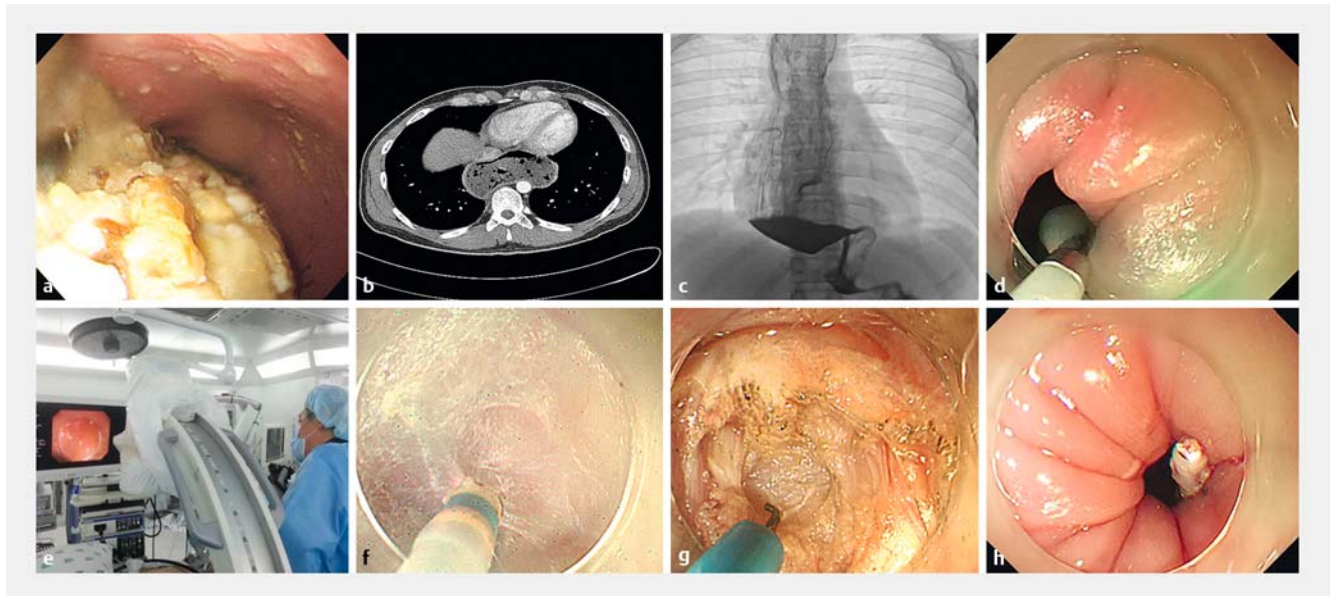


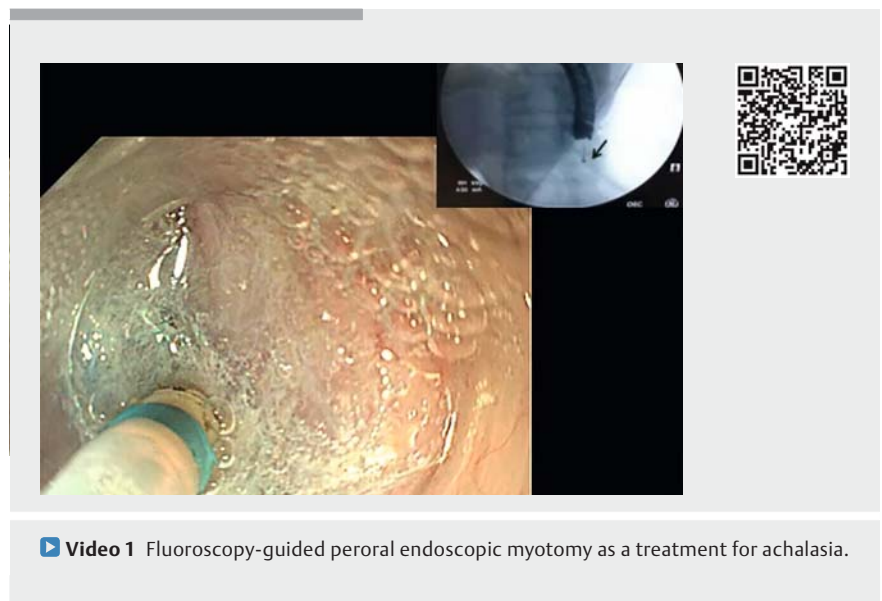
Fluoroscopy-guided peroral endoscopic myotomy for sigmoid-type achalasia



► Fig. 1 Fluoroscopy-guided peroral endoscopic myotomy (POEM). **a** Gastroscopy revealed accumulation of a large amount of food in the lower esophagus. **b** Preoperative chest computed tomography showed dilation of the entire esophagus containing large quantities of food. **c** Barium radiograph showed the tortuous esophageal lumen with a beak-shaped appearance of the distal esophagus (sigmoid-shaped esophagus). **d** Indocyanine green injection with endoclip deployment was performed. **e** Fluoroscopy-guided POEM. **f** Submucosal tunneling. **g** Full-thickness myotomy. **h** Smooth endoscope passage through the esophagogastric junction.

A 28-year-old man was referred to hospital with dysphagia, a symptom that had persisted for 10 years. He had recently been admitted to another clinic for aspiration pneumonia before being referred to our hospital. Gastroscopy showed a tightened esophagogastric junction (EGJ).

We developed a fluoroscopy-guided peroral endoscopic myotomy (POEM) technique (► **Fig. 1**, ► **Video 1**) using C-arm. This procedure was performed by an experienced gastroenterologist (J. Y. C.), as follows. 1) A mucosal incision was made to create a submucosal tunnel entrance. 2) An indocyanine green (ICG) dye tracer was injected and an endoclip was placed below the EGJ. 3) Submucosal tunneling started 12 cm proximal to the EGJ, and intraprocedural fluoroscopy was used to document the submucosal tunnel direction toward the EGJ. 5) The greenish submucosa previously labeled with ICG was visualized. 6) Myotomy was performed.



► Video 1 Fluoroscopy-guided peroral endoscopic myotomy as a treatment for achalasia.

7) Mucosal entry was closed with endoclips. After the procedure, smooth passage of the endoscope was possible.

There were no immediate complications, and the patient was discharged after 10 days. The procedure duration was 60 minutes, and the myotomy length was

10 cm. After 1 month, the Eckardt symptom score had improved from 9 to 0.

POEM is a standard, widely accepted achalasia treatment [1]. However, because of its complexity, successful POEM requires advanced endoscopic skills and specialized training. Sigmoid-type achalasia poses a therapeutic challenge because of its many acute angulations before reaching the EGJ [2]. Liu et al. [3] performed open POEM as an easier and less time-consuming technique for sigmoid-shaped esophagus. Fluoroscopy-guided POEM is an efficient technique for objectively investigating anatomically challenging locations. Adequate direction of submucosal tunneling to the EGJ was confirmed by visualizing the ICG-marked greenish submucosa. Technique limitations include the requirement of an operative suite and patient exposure to small amounts of radiation. Fluoroscopic images could be used to determine submucosal tunneling direction and navigation to the EGJ, preventing accidental probe misdirection.

Endoscopy_UCTN_Code_TTT_1AO_2AD

Competing interests

None

The authors

In Kyung Yoo, Joo Young Cho, Sang Ah Choi, Won Hee Kim, Ki Baik Hahm, Sung Pyo Hong

Division of Gastroenterology, Department of Internal Medicine, Cha Bundang Medical Center, Seongnam-si, Korea

Corresponding author

Joo Young Cho, MD, PhD

Division of Gastroenterology, Department of Internal Medicine, Cha Bundang Medical Center, 59 Yatapro, Bundang-gu, Seongnam-si, Korea
 Fax: +82-32-7805005
 cjy6695@dreamwiz.com

References

- [1] Inoue H, Minami H, Kobayashi Y et al. Peroral endoscopic myotomy (POEM) for esophageal achalasia. *Endoscopy* 2010; 42: 265–271
- [2] Hu JW, Li QL, Zhou PH et al. Peroral endoscopic myotomy for advanced achalasia with sigmoid-shaped esophagus: long-term outcomes from a prospective, single-center study. *Surg Endosc* 2015; 29: 2841–2850
- [3] Liu W, Liu L, Chen HL et al. Open peroral endoscopic myotomy for achalasia with sigmoid-shaped esophagus. *Endoscopy* 2017; 49: E311–E312

Bibliography

DOI <https://doi.org/10.1055/a-0596-7068>

Published online: 13.4.2018

Endoscopy 2018; 50: E151–E152

© Georg Thieme Verlag KG

Stuttgart · New York

ISSN 0013-726X

ENDOSCOPY E-VIDEOS

<https://eref.thieme.de/e-videos>



Endoscopy E-Videos is a free access online section, reporting on interesting cases and new

techniques in gastroenterological endoscopy. All papers include a high quality video and all contributions are freely accessible online.

This section has its own submission website at

<https://mc.manuscriptcentral.com/e-videos>