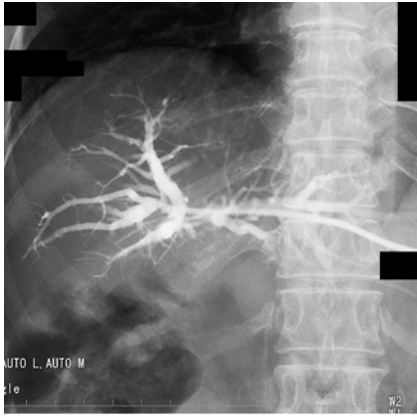
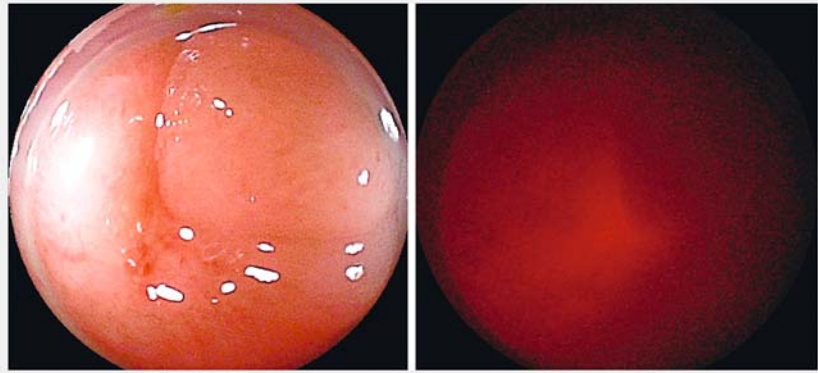


## Rendezvous biliary recanalization with combined percutaneous transhepatic cholangioscopy and double-balloon endoscopy



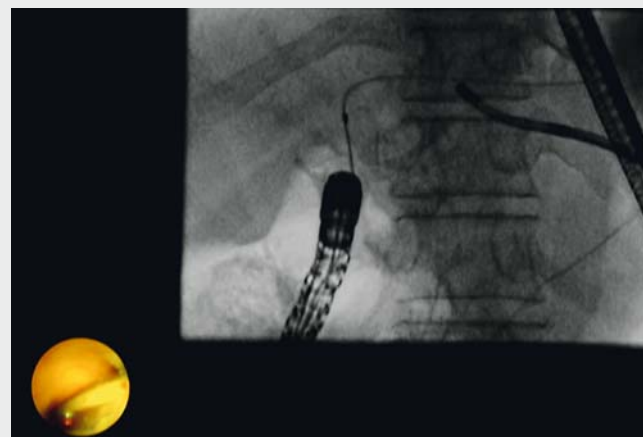
► **Fig. 1** Percutaneous transhepatic cholangiogram showing complete obstruction of the choledochojejunal anastomosis in a patient who had undergone pancreaticoduodenectomy 7 years previously.



► **Fig. 2** Left panel: The choledochojejunal anastomosis has an appearance similar to an ulcer scar. Right panel: Transillumination from the percutaneous transhepatic cholangioscope guides direct precutting using the double-balloon endoscope.

Despite advances in biliary stenting in patients with altered gastrointestinal anatomy, it is still a challenging procedure [1]. We present a case where percutaneous transhepatic cholangioscopy (PTCS) was combined with double-balloon endoscopy (DBE) for biliary stenting in a patient with complete obstruction of a choledochojejunostomy.

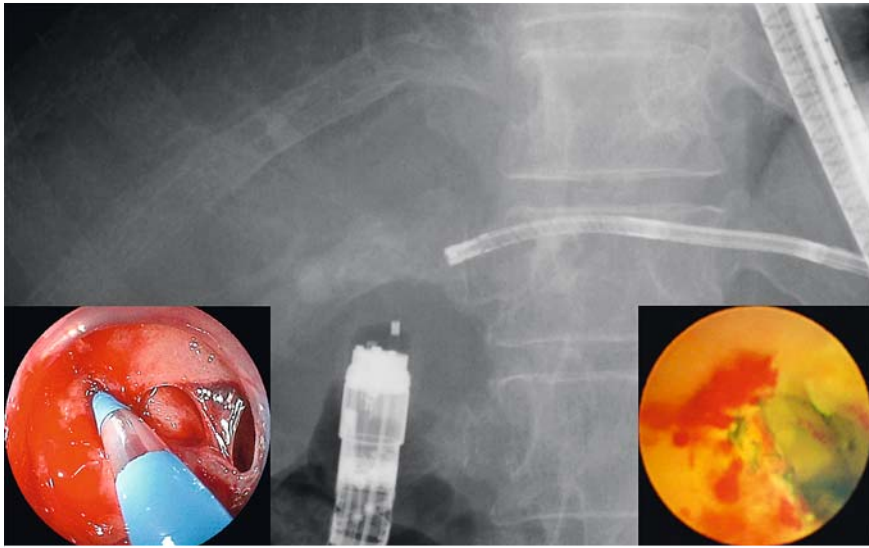
A 71-year-old woman, who had a history of distal cholangiocarcinoma and had undergone pancreaticoduodenectomy 7 years previously, experienced recurrent cholangitis. DBE-assisted balloon dilation had been performed 7 months previously for stricture of the choledochojejunal anastomosis. However, she developed complete obstruction of the anastomosis (► **Fig. 1**). A 7.2-Fr percutaneous transhepatic biliary drainage (PTBD) catheter was initially placed, and the fistula tract was dilated up to 12Fr within 4 weeks. DBE-assisted endoscopic retrograde cholangiopancreatography was then attempted. First, the double-balloon endoscope (EI-580BT; Fujifilm, Tokyo, Japan) was advanced to the afferent limb, and a percutaneous transhepatic cholangiogram revealed complete obstruction of



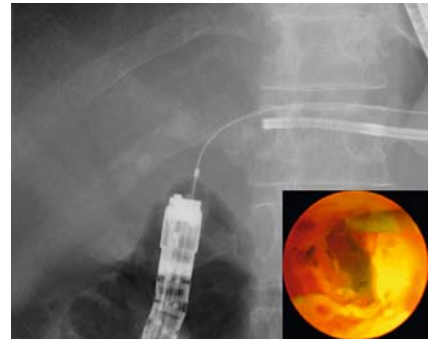
► **Video 1** Biliary recanalization, using a rendezvous technique with combined percutaneous transhepatic cholangioscopy and double-balloon endoscopy, for a completely obstructed choledochojejunostomy.

the anastomosis. Next, a PTCS scope (BF type P260F; Olympus, Tokyo, Japan) was inserted via the PTBD route. However, a guidewire (0.018-inch, Pathfinder Exchange; Boston Scientific Japan, Tokyo, Japan) through the PTCS scope could not pass the anastomosis (► **Video 1**). Therefore, we attempted direct precutting (KD-V451M; Olympus) at the anas-

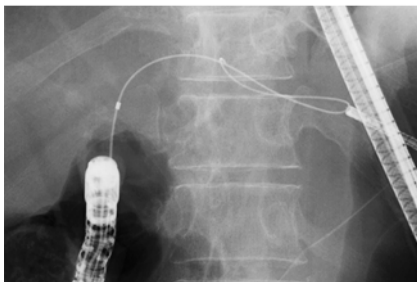
tomosis, using the double-balloon endoscope and guided by transillumination from the percutaneous transhepatic cholangioscope' (► **Fig. 2**, ► **Video 1**). A small incision was carefully made in order to create a fistula (► **Fig. 3**). This was followed by successful passage of the guidewire (0.032-inch, Radifocus Guidewire M; Terumo, Tokyo, Japan)



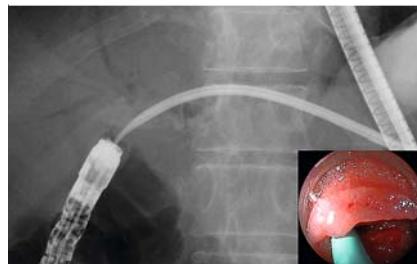
► **Fig. 3** Radiograph showing direct precutting at the choledochojejunal anastomosis, under fluoroscopic guidance and transillumination from the percutaneous transhepatic cholangioscope. Left inset: enteroscopy view. Right inset: percutaneous transhepatic cholangioscopy view.



► **Fig. 4** Radiograph showing the guidewire passing through the obstruction. Inset: percutaneous transhepatic cholangioscopy view.



► **Fig. 5** The guidewire is grasped by means of a snare under fluoroscopic and percutaneous transhepatic cholangioscopic guidance.



► **Fig. 6** Insertion of the percutaneous transhepatic biliary drainage catheter, using a rendezvous technique, across the previously obstructed choledochojejunal anastomosis. Inset: percutaneous transhepatic cholangioscopy view.

completely through the anastomotic obstruction (► **Fig. 4**, ► **Video 1**). We then grasped the guidewire with an ultraslim basket catheter (Zero Tip Retrieval Basket; Boston Scientific) using the cholangioscope (► **Fig. 5**, ► **Video 1**). Finally, a 12-Fr PTBD catheter was placed across the obstruction without any complications (► **Fig. 6**, ► **Video 1**).

The rendezvous technique in combination with PTCS and DBE facilitates biliary recanalization of complete biliary obstruction [1,2]. However, blind incision has the risk of gastrointestinal tract per-

foration or bile leakage. Although caution should be exercised, incision guided by transillumination from the peroral transhepatic cholangioscope is a safe and less invasive technique compared with surgery.

Endoscopy\_UCTN\_Code\_TTT\_1AR\_2AJ

#### Competing interests

None

#### The authors

**Hiroshi Kawakami**<sup>1,2</sup>, **Tesshin Ban**<sup>1,2</sup>, **Yoshimasa Kubota**<sup>1,2</sup>, **Shinya Ashizuka**<sup>2</sup>, **Ichiro Sannomiya**<sup>2</sup>, **Naoya Imamura**<sup>2,3</sup>, **Takeomi Hamada**<sup>2,3</sup>

- 1 Department of Gastroenterology and Hepatology, Faculty of Medicine, University of Miyazaki, Miyazaki, Japan
- 2 Department of Gastroenterology and Hepatology, Center for Digestive Disease and Division of Endoscopy, University of Miyazaki Hospital, Miyazaki, Japan
- 3 Division of Hepato-Biliary-Pancreas Surgery, Department of Surgery, Faculty of Medicine, University of Miyazaki, Miyazaki, Japan

## Corresponding author

**Hiroshi Kawakami, MD, PhD**

Department of Gastroenterology and Hepatology, Center for Digestive Disease and Division of Endoscopy, University of Miyazaki Hospital, 5200, Kiyotake, Kihara, Miyazaki 889-1692, Japan  
Fax: +81-985-859802  
hiropon@med.miyazaki-u.ac.jp

## References

- [1] Shimatani M, Takaoka M, Ikeura T et al. Rendezvous technique: double-balloon endoscopy and SpyGlass direct visualization system in a patient with severe stenosis of a choledochojejunal anastomosis. *Endoscopy* 2014; 46 (Suppl. 01): E275 – E276
- [2] Bukhari MA, Haito-Chavez Y, Ngamruengphong S et al. Rendezvous biliary recanalization of complete biliary obstruction with direct peroral and percutaneous transhepatic cholangioscopy. *Gastroenterology* 2018; 154: 23 – 25

## Bibliography

DOI <https://doi.org/10.1055/a-0591-2109>

Published online: 13.4.2018

*Endoscopy* 2018; 50: E146–E148

© Georg Thieme Verlag KG

Stuttgart · New York

ISSN 0013-726X

## ENDOSCOPY E-VIDEOS

<https://eref.thieme.de/e-videos>



*Endoscopy E-Videos* is a free access online section, reporting on interesting cases and new

techniques in gastroenterological endoscopy. All papers include a high quality video and all contributions are freely accessible online.

This section has its own submission website at

<https://mc.manuscriptcentral.com/e-videos>