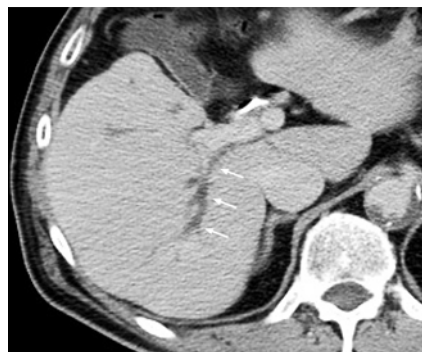

Magnetic compression anastomosis for biliary obstruction after partial hepatectomy

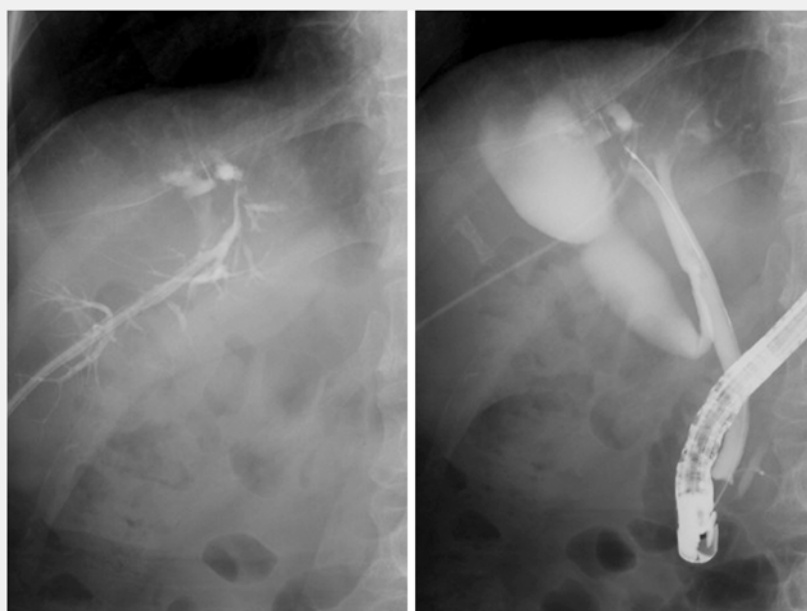


► **Fig. 1** Dilatation of the right-posterior intrahepatic bile (arrows) seen at computed tomography (CT).

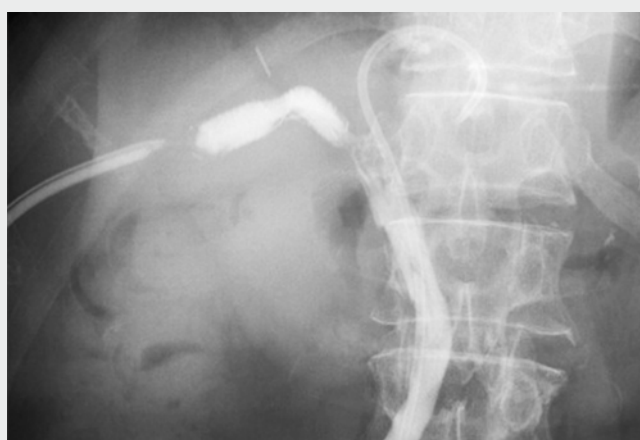Magnetic compression anastomosis (MCA) is a revolutionary method of performing choledochcholedochostomy without surgery in patients with biliary obstruction [1–5]. Herein, we report the successful treatment, using MCA, of a case of complete biliary obstruction after partial hepatectomy.

A 64-year-old man who had undergone right partial hepatectomy for a metastatic liver tumor from rectal cancer was admitted to another hospital with bile leakage. Although the bile leakage was treated by endoscopic nasobiliary drainage, there was prolonged liver dysfunction, and computed tomography showed dilatation of the right-posterior intrahepatic bile duct (► **Fig. 1**). Endoscopic retrograde cholangiopancreatography and percutaneous transhepatic biliary drainage (PTBD) were attempted but recanalization was not possible (► **Fig. 2**). Therefore, the patient was referred to our hospital.

Initially, an 18-Fr PTBD catheter was placed. A cylindrical neodymium magnet, 5 mm in diameter, was pushed to the tip of the PTBD catheter and inserted in the intrahepatic bile duct using biopsy forceps (► **Video 1**). Next, another magnet, 3 mm in diameter, was inserted up to the tip of the inner part of the outer sheath of the guidewire (VisiGlide 2; Olympus, Tokyo, Japan) for delivery



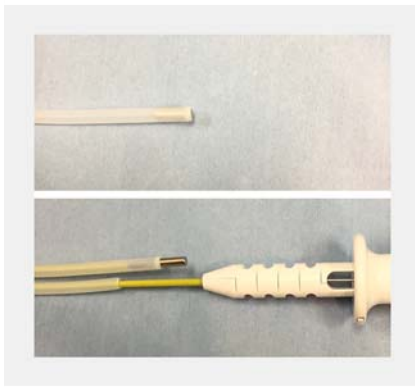
► **Fig. 2** Endoscopic retrograde cholangiopancreatography and percutaneous transhepatic biliary drainage were attempted but recanalization was not possible.



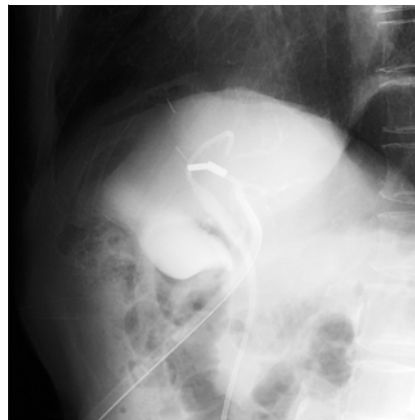► **Video 1** Magnetic compression anastomosis for biliary obstruction following partial hepatectomy, after failure of recanalization by means of endoscopic retrograde cholangiopancreatography and percutaneous transhepatic biliary drainage.

(► **Fig. 3**). Then, the outer sheath with the magnet was inserted via the papilla and the magnet was pushed out using biopsy forceps. The magnets were ad-

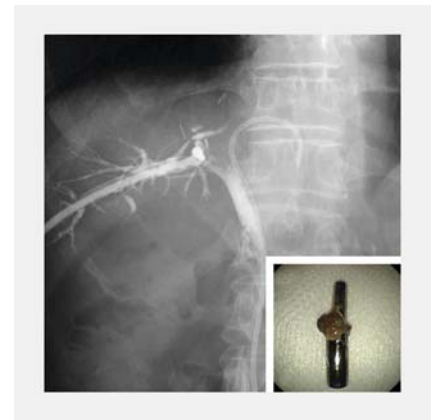vanced to sites immediately before and after the obstruction. Then, the two magnets were positioned so that they attracted each other (► **Fig. 4**, ► **Video 1**). A plas-



► **Fig. 3** A magnet was inserted up to the tip of the lumen of the outer sheath of the guidewire for delivery.



► **Fig. 4** The two magnets attracted each other.



► **Fig. 5** Recanalization was achieved (main figure) and the magnets were endoscopically removed (inset).

tic stent was placed via the transpapillary route in the left bile duct to prevent magnet migration. Recanalization was achieved 7 days after the procedure and the magnets were endoscopically removed using basket forceps, without adverse events (► **Fig. 5**, ► **Video 1**). The created fistula was dilated using a 10-Fr biliary dilation catheter over the guidewire. Finally, a fully covered self-expandable metal stent (BonaStent M-intra-ductal; Standard Sci Tech, Seoul, South Korea) was placed in the right bile duct across the fistula (► **Video 1**).

Endoscopy_UCTN_Code_TTT_1AR_2AJ

Competing interests

None

The authors

Xue-Mei Jiang¹, Kenjiro Yamamoto², Takayoshi Tsuchiya², Atsushi Sofuni², Shuntaro Mukai², Yuichi Nagakawa³, Takao Itoi²

- 1 Department of Gastroenterology, Central South University Xiangya School of Medicine Affiliated Haikou Hospital, Haikou, China
- 2 Department of Gastroenterology and Hepatology, Tokyo Medical University, Tokyo, Japan
- 3 Third Department of Surgery, Tokyo Medical University, Tokyo, Japan

Corresponding author

Kenjiro Yamamoto, MD

Department of Gastroenterology and Hepatology, Tokyo Medical University, 6-7-1 Nishishinjuku, Shinjuku-ku, Tokyo 160-0023, Japan

Fax: +81-3-53816654

ken.yamamoto5544@gmail.com

References

- [1] Mimuro A, Tsuchida A, Yamanouchi E et al. A novel technique of magnetic compression anastomosis for severe biliary stenosis. *Gastrointest Endosc* 2003; 58: 283–287
- [2] Itoi T, Yamanouchi E, Ikeda T et al. Magnetic compression anastomosis: a novel technique for canalization of severe hilar bile duct strictures. *Endoscopy* 2005; 37: 1248–1251
- [3] Itoi T, Yamanouchi E, Ikeuchi N et al. Magnetic compression duct-to-duct anastomosis for biliary obstruction in a patient with living donor liver transplantation. *Gut Liver* 2010; 4: 96–98
- [4] Itoi T, Kasuya K, Sofuni A et al. Magnetic compression anastomosis for biliary obstruction: review and experience at Tokyo Medical University Hospital. *J Hepatobiliary Pancreat Sci* 2011; 18: 357–365
- [5] Jang SI, Kim JH, Won JY et al. Magnetic compression anastomosis is useful in biliary anastomotic strictures after living donor liver transplantation. *Gastrointest Endosc* 2011; 74: 1040–1048

Bibliography

DOI <https://doi.org/10.1055/a-0588-4653>

Published online: 9.4.2018

Endoscopy 2018; 50: E144–E145

© Georg Thieme Verlag KG

Stuttgart · New York

ISSN 0013-726X

ENDOSCOPY E-VIDEOS

<https://eref.thieme.de/e-videos>



Endoscopy E-Videos is a free access online section, reporting on interesting cases and new techniques in gastroenterological endoscopy. All papers include a high quality video and all contributions are freely accessible online.

This section has its own submission website at <https://mc.manuscriptcentral.com/e-videos>