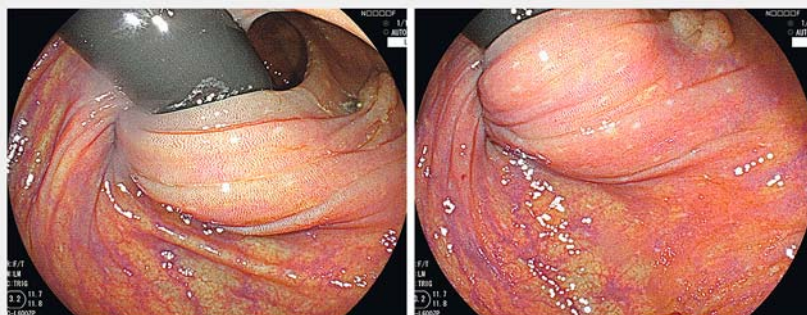
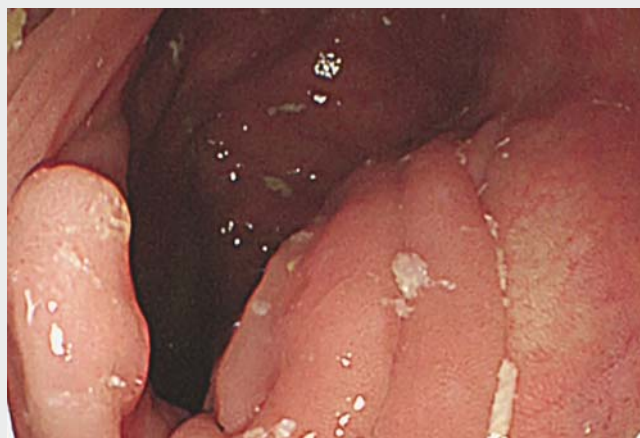

## Endocuff-assisted underwater snare polypectomy in complex ascending colon neoplasia

Endoscopic mucosal resection (EMR) is a simple, universal treatment for intramucosal colorectal neoplasms. The technical difficulties associated with the process increase depending on the location of lesion, particularly for lesions at the hepatic or splenic flexures. Such lesions are easily missed and are considered to be a cause of interval cancer. The Endocuff was developed to improve detection of lesions located in these difficult locations [1,2]. Here, we report a case showing the efficacy of Endocuff assistance when performing endoscopic resection. The patient was a 78-year-old woman with a previous gastrectomy for gastric cancer, who underwent surveillance colonoscopy after polypectomy. Colonoscopy showed a flat elevated-type lesion (0-IIa) in the hepatic flexure that was considered to be a missed adenoma from a previous colonoscopy using the retroflexion technique [3] (► Fig.1). It was impossible to approach the lesion for polypectomy with the retroflexion technique, but the lesion was observable on conventional forward observation. To overcome this anatomical issue, we attached the Endocuff to the top of the endoscope. This made it possible to visualize the lesion using forward observation. However, the lesion seemed to be close to the top of a fold, and it was relatively difficult to confirm the extent of the distal side of the lesion. We therefore used the underwater polypectomy technique instead of conventional EMR [4]; visualization of lesion seemed to be better because of natural lifting with the floatation after water immersion (► Video 1). First, we estimated the histology as being high grade dysplasia (intramucosal cancer) using narrow-band imaging (NBI). The lesion appeared to be type 2 in the NBI International Colorectal Endoscopic (NICE) classification. Next, we resected the lesion using a two-piece resection (piecemeal polypectomy) without any adverse events.



► **Fig. 1** Endoscopic images of a flat elevated-type lesion in the hepatic flexure, which was only detected using retroflexion; however, it was technically impossible to approach the lesion for the purpose of magnifying observation and endoscopic resection.



► **Video 1** An Endocuff was placed on the top of the endoscope to allow the lesion to be viewed using forward observation. The water-filling process was effective in helping to acquire better visualization and allowing the lesion to be grasped with a snare.

We conclude that underwater polypectomy using Endocuff assistance to treat neoplasms located only in the hepatic or splenic flexure may be considered an effective method for endoluminal treatment of complex lesions.

Endoscopy\_UCTN\_Code\_TTT\_1AQ\_2AD

### Competing interests

None

### The authors

**Taku Sakamoto, Seiichiro Abe, Marina Kaori Yoshida, Yusaku Tanaka, Yutaka Saito**  
Endoscopy Division, National Cancer Center Hospital, Tokyo, Japan

## Corresponding author

### Taku Sakamoto, MD

National Cancer Center Hospital, 5-1-1  
Tsukiji, Chuo-ku, Tokyo, 104-0045, Japan  
Fax: +81-3-35423815  
tasakamo@ncc.go.jp

## References

- [1] Pioche M, Matsumoto M, Takamaru H et al. Endocuff-assisted colonoscopy increases polyp detection rate: a simulated randomized study involving an anatomic colorectal model and 32 international endoscopists. *Surg Endosc* 2016; 30: 288–295
- [2] Lenze F, Beyna T, Lenz P et al. Endocuff-assisted colonoscopy: a new accessory to improve adenoma detection rate? Techni-

cal aspects and first clinical experiences. *Endoscopy* 2014; 46: 610–614

- [3] Cohen J, Grunwald D, Grossberg LB et al. The effect of right colon retroflexion on adenoma detection: a systematic review and meta-analysis. *J Clin Gastroenterol* 2017; 51: 818–824
- [4] Binmoeller KF, Weibert F, Shah J et al. “Underwater” EMR without submucosal injection for large sessile colorectal polyps (with video). *Gastrointest Endosc* 2012; 75: 1086–1091

### Bibliography

DOI <https://doi.org/10.1055/a-0584-5538>  
Published online: 22.3.2018  
*Endoscopy* 2018; 50: E136–E137  
© Georg Thieme Verlag KG  
Stuttgart · New York  
ISSN 0013-726X

### ENDOSCOPY E-VIDEOS

<https://eref.thieme.de/e-videos>



*Endoscopy E-Videos* is a free access online section, reporting on interesting cases and new

techniques in gastroenterological endoscopy. All papers include a high quality video and all contributions are freely accessible online.

This section has its own submission website at

<https://mc.manuscriptcentral.com/e-videos>