

Difference in real-time magnetic image analysis of colonic looping patterns between males and females undergoing diagnostic colonoscopy



Authors

Jacob Lam¹, James Wilkinson¹, Cecilia Brassett², Jonathan Brown^{2,3}

Institutions

- 1 The University of Cambridge School of Clinical Medicine
- 2 Human Anatomy Teaching Group, Department of Physiology, Development and Neuroscience, University of Cambridge
- 3 Gloucestershire Hospitals NHS Foundation Trust, Gloucester

submitted 20.9.2017

accepted after revision 8.11.2017

Bibliography

DOI <https://doi.org/10.1055/a-0574-2478> |
Endoscopy International Open 2018; 06: E575–E581
© Georg Thieme Verlag KG Stuttgart · New York
ISSN 2364-3722

Corresponding author

Jacob Lam, Jesus College, Cambridge, CB5 8BL
Phone: 07758 228567
jacobsimonlam@gmail.com

ABSTRACT

Background and study aim Magnetic imaging technology is of proven benefit to trainees in colonoscopy, but few studies have examined its benefits in experienced hands. There is evidence that colonoscopy is more difficult in women. We set out to investigate (i) associations between

the looping configurations in the proximal and distal colon and (ii) differences in the looping prevalence between the sexes. We have examined their significance in terms of segmental intubation times and position changes required for the completion of colonoscopy.

Patients and methods We analyzed 103 consecutive synchronized luminal and magnetic image videos of diagnostic colonoscopies with normal anatomy undertaken by a single experienced operator.

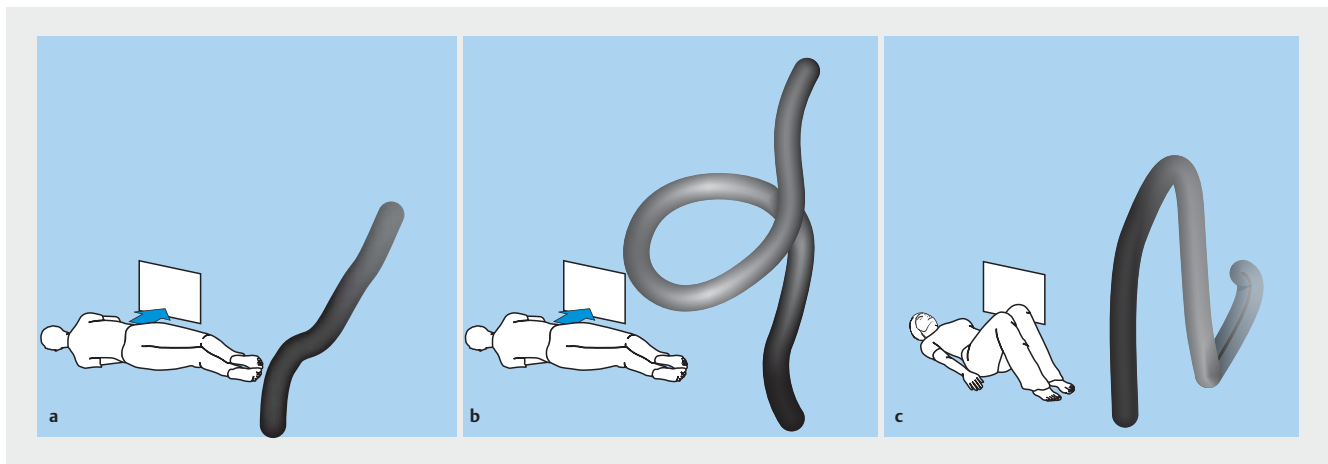
Results Deep transverse loops and sigmoid N-loops were more common in females. A deep transverse loop was more likely to be present if a sigmoid alpha-loop or N-loop had formed previously. Patients with sigmoid N-loops were turned more frequently from left lateral to supine before the sigmoid-descending junction was reached, but there was no statistical correlation between completion time and looping pattern.

Conclusions This study has reexamined the prevalence of the common looping patterns encountered during colonoscopy and has identified differences between the sexes. This finding may offer an explanation as to why colonoscopy has been shown to be more difficult in females. Although a deep transverse loop following a resolved sigmoid alpha-loop was the most commonly encountered pattern, no statistical correlation between completion time and looping pattern could be shown. It is the first study to examine segmental completion times using a magnetic imager in expert hands.

Introduction

The quality assurance parameters of diagnostic colonoscopy continue to evolve with international recognition that comfort, completion, and visualization are fundamental to a safe and effective test. The combination of structured education for trainees, formative assessments for credentialing, and technological advances in ergonomics and image processing underlie this progression. In the United Kingdom (UK), unadjusted cecal intubation rates (CIRs) have increased and perforation rates have decreased markedly from 76.9% and 0.13% in 2004 [1] to

92.3% and 0.04% in 2011 [2], respectively. Similarly, patient discomfort and colonic looping accounted for 64% of completion failures in 2004 and 49% in 2011. Combining the published data suggests, as a rule of thumb, that an incomplete procedure is due to pain and looping in 50%, stricture or obstruction in 25%, and poor bowel preparation in 20%, with cardiovascular instability and severe inflammatory bowel disease making up the remainder. An understanding of looping patterns and the techniques for their resolution is therefore an imperative for successful colonoscopy. CIRs are known to be lower in female



► **Fig. 1** Sigmoid colon configurations and patient position icons as seen on the ScopeGuide image. **a** Straight. **b** Alpha-loop. **c** N-loop.

patients compared to male [3–5]. Our study aims to use the Olympus magnetic imager (ScopeGuide) to analyze associations between different loop configurations, sexual dimorphism, and completion times, which serve as an index of difficulty in colonoscopy [6].

The common looping patterns of the colon derived from magnetic imaging scope technology have been well described [7]. The “alpha” configuration was so-named because it contains a clockwise spiral that resembles the Greek letter. The “N-loop” configuration occurs when the scope forms an acute hairpin bend at the sigmoid-descending junction. This latter loop might contain a spiral “knuckle,” which resembles a small alpha element. However, by means of a magnetic imaging device, Shah et al. [8] have shown that most loops (69%) are incorrectly diagnosed by endoscopists and that position change (66% of cases) is more effective than external hand pressure (37% of cases) at promoting tip advancement in difficult cases.

One marker of competence, an unadjusted CIR of >90%, is usually obtained after 175–400 training cases [9–11]. Current UK standards require at least 200 training procedures to achieve competency, but only 41% of trainees can achieve this [12]. Magnetic imaging technologies, such as ScopeGuide, have improved CIRs by providing the colonoscopist with a real-time three-dimensional reconstruction of the position of the endoscope within the colon, enabling rapid visual guidance on identifying and resolving difficult loops [13]. Using this technology, Shah et al. [8] showed that a sigmoid “N” spiral formed in 80% of cases, an alpha-loop formed in 10% of cases, and in 10% the sigmoid remained straight. Furthermore, 30% of cases were associated with the formation of a deep transverse loop and in 1% a “gamma-loop.”

We set out to reexamine the prevalence of the different loop configurations and to examine their associations between the different sexes and their impact on completion times.

Patients and methods

A total of 103 ScopeGuide videos of normal diagnostic colonoscopies performed by 1 experienced colonoscopist were analyzed. They comprised consecutive diagnostic cases where no significant pathology was identified and were performed in Gloucestershire Royal Hospital, UK, between February 2014 and January 2015.

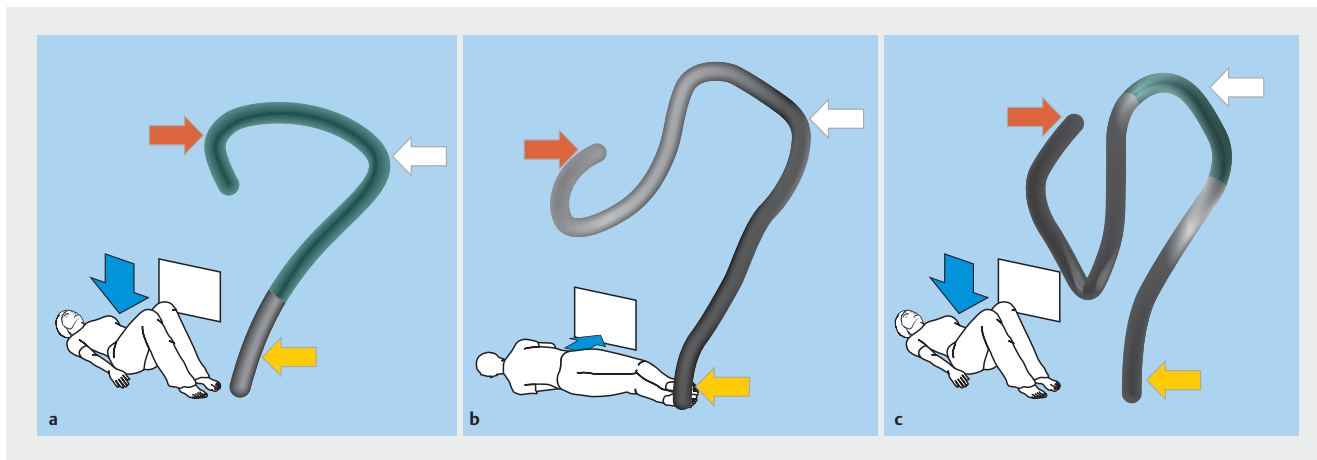
Colonoscopist

The clinician in this study was a national bowel cancer screening (BCS) colonoscopist with 25 years’ experience of colonoscopy assisted by a magnetic imager. Audit figures determined by independent observation have shown procedure comfort scores for this operator on the BCS 50th centile with 93% of examinations completed with no, minimal, or mild discomfort.

Loop configurations

We defined new sigmoid and transverse configurations to supplement those previously described. A “straight” sigmoid description was introduced for cases with a seemingly direct passage of the scope from the sigmoid colon into the descending colon without any apparent angulation. The sigmoid configurations identified in this study are shown in ► **Fig. 1**.

For the transverse colon, novel definitions were created to describe more precisely the extent of the looping patterns observed. These related to 3 qualitatively estimated anatomical locations: the hepatic flexure, the splenic flexure, and the anus (demonstrated in ► **Fig. 2** by red arrows, white arrows, and yellow arrows, respectively). These locations are readily identified on ScopeGuide images with the position of the anus estimated from the position of the tip of the colonoscope at the beginning of the recording (i. e., when the scope was inserted into the rectum). A “straight” transverse colon crosses the abdomen in a straight line between the splenic flexure and hepatic flexure, with no loop formation (► **Fig. 2a**). An “intermediate” loop is formed if the deepest point of the transverse colon descends inferior to a straight line between the 2 flexures, but not infer-



► **Fig. 2** Transverse colon configurations and patient position icons as seen on the ScopeGuide image. The hepatic flexure is demonstrated by red arrows, the splenic flexure by white arrows, and an approximate position of the anus by yellow arrows. **a** Straight. **b** Intermediate loop. **c** Deep loop.

► **Table 1** Definition of sigmoid and transverse colon configurations.

Sigmoid	Definition
Alpha-loop	Spiral resembles Greek letter alpha. Resolution requires withdrawal and clockwise twist.
N-loop	Acute hairpin bend at sigmoid-descending junction. Once scope tip is “hooked” at junction, loop can be resolved by withdrawal.
Straight	Straight, “direct” passage through sigmoid into descending colon. Progress by rotatory and withdrawal maneuvers when necessary.
Transverse	Definition
Straight	Transverse colon crosses in a straight line between the splenic flexure and hepatic flexure.
Intermediate loop	Deepest point of transverse colon descends inferior to a straight line between the 2 flexures, but not beyond a horizontal line equidistant between the splenic flexure and anus.
Deep loop	Deepest point of transverse colon descends inferior to a horizontal line equidistant between the splenic flexure and anus.

ior to a horizontal line equidistant between the anus and splenic flexure (► **Fig. 2b**). A “deep” loop occurs if the deepest part of the transverse colon descends inferior to a horizontal line equidistant between the anus and splenic flexure (► **Fig. 2c**).

Repeated inspection of the ScopeGuide videos enabled these standard definitions to be applied to the configurations of the sigmoid and transverse colons in real time in order to analyze the frequency and associations of the looping patterns. Definitions of the sigmoid and transverse configurations are shown in ► **Table 1**.

Position change

The position changes used in the procedures were also analyzed. This was achieved by documenting the position of the patient as determined by the small icon in ScopeGuide. This was reset by the colonoscopist each time a position change was performed to facilitate successful navigation of a colonic segment, as demonstrated in ► **Fig. 1** and ► **Fig. 2**.

Timing

The time taken for each colonoscopy as well as the proximal and distal colon completion times were recorded. Both the endoscope and ScopeGuide views were considered to achieve this. The distal colon completion time was defined as the time between entry of the tip of the colonoscope at the anus and entry into the transverse colon. The proximal colon completion time was defined as the time between entry into the transverse colon and visualization beneath the ileocecal valve. The overall completion time was defined as the time between entry of the tip of the colonoscope at the anus and visualization beneath the ileocecal valve. The system clock on the video image was used to determine these times.

Statistical methods

Sex differences in colonic configuration, associations between the looping configurations in the proximal and distal colon, and requirement for a position change were analyzed with Fisher’s exact test. The association between completion time and

► **Table 2** Colonoscopy patient data.

	Male (n = 50)	Female (n = 53)
Median age (SD) (years)	65 (13.1)	66 (16.3)
Mean cecal intubation time (SD) (min)	7.5 (3.8)	7.6 (3.5)

► **Table 3** Frequency of deep transverse loops in relation to sigmoid configurations.

Sigmoid configuration	Proportion with deep transverse loop
Straight	24%
Alpha-loop	53%
N-loop	47%

configuration was analyzed with a 1-way analysis of variance (ANOVA). A *P*-value <0.05 was considered significant.

Results

The age, sex, and cecal intubation times of the 103 patients are summarized in ► **Table 2**.

Loop configurations

Significant differences between the sexes were found in both sigmoid and transverse colonic configurations. In the sigmoid colon, straight (M: 19, F: 13) and alpha-loops (M: 28, F: 24) were more common in males, and N-loops were more common in females (M: 3, F: 16, *P*=0.0066) (► **Fig. 3**).

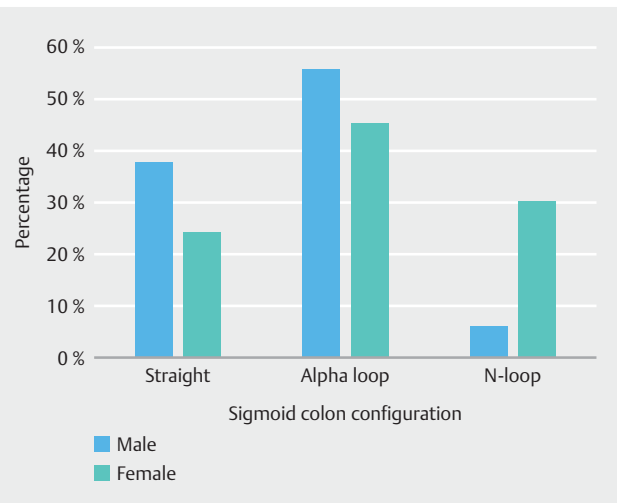
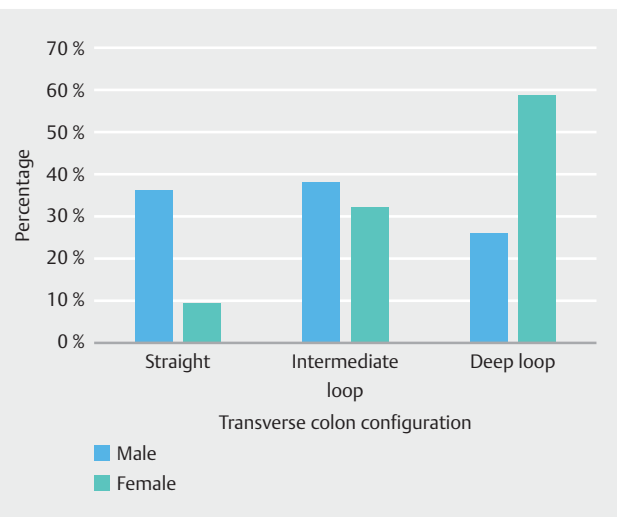
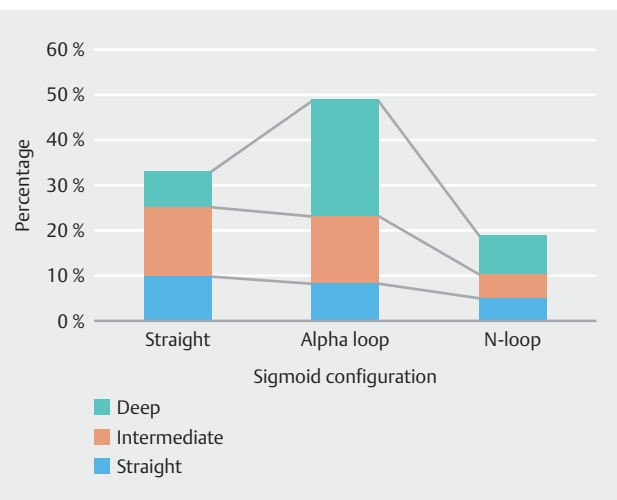
In the transverse colon, straight (M: 18, F: 5) and intermediate loops (M: 19, F: 17) were more common in males, and deep loops (M: 13, F: 31, *P*=0.0006) were more common in females (► **Fig. 4**).

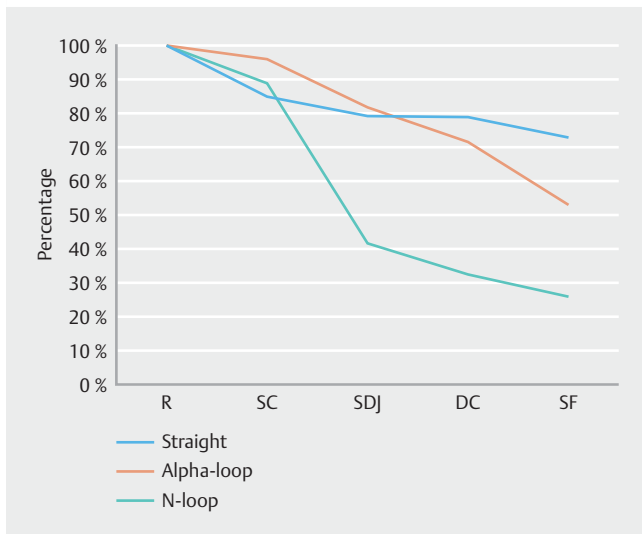
As there were 3 configurations of sigmoid colon, and 3 configurations of proximal colon, there were 9 possible combinations. ► **Fig. 5** depicts their frequencies and shows that a sigmoid alpha-loop followed by a deep transverse loop was the most common overall. However, this does not imply that an alpha-loop was necessarily present when the deep transverse loop was encountered.

Furthermore, patients with sigmoid alpha-loops and N-loops were more likely to have a deep transverse loop compared to those with a straight sigmoid colon (*P*=0.0476) (► **Table 3**). This may be due to increased mobility of the whole colon in these patients.

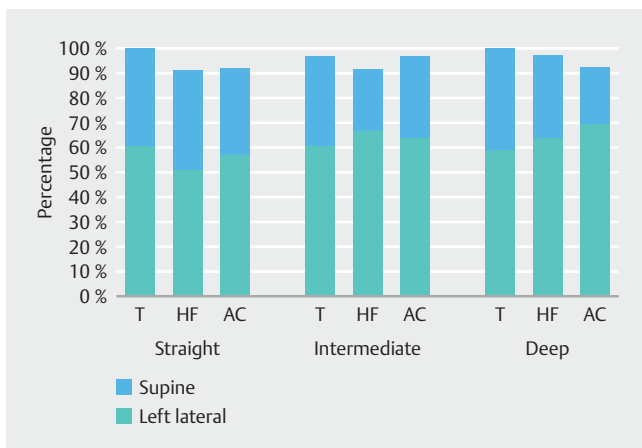
Position change

In the distal colon, the requirement for a position change from left lateral to supine occurred more frequently and earlier in the procedure (before the sigmoid-descending junction was reached) for N-loops compared to the straight or alpha-loop configurations (► **Fig. 6**). At the sigmoid-descending junction,

► **Fig. 3** Frequency distribution of sigmoid colon configurations.► **Fig. 4** Frequency distribution of transverse colon configurations.► **Fig. 5** The frequency distribution of the proximal and distal colon configurations.



► **Fig. 6** Percentage of patients remaining in left lateral during passage of colonoscope through the left colon. R = rectum, SC = sigmoid colon, SDJ = sigmoid-descending junction, DC = descending colon, SF = splenic flexure.

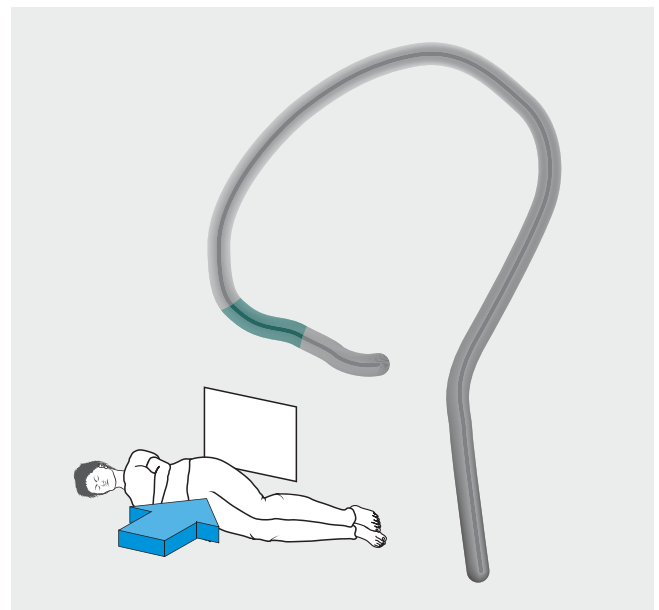


► **Fig. 7** Frequency of left lateral and supine positions during colonoscopy of proximal bowel in relation to transverse loop configuration. Right lateral and prone positions (not shown) made up the remainder in each configuration. T = transverse colon, HF = hepatic flexure, AC = ascending colon.

more patients with N-loops had been turned to the supine position compared to those with straight sigmoid colons ($P=0.0054$) and alpha-loops ($P=0.0026$). Likewise, at the splenic flexure, more patients with N-loops had been turned to the supine position compared to those with straight sigmoid colons ($P=0.0004$) and alpha-loops ($P=0.0414$).

In the proximal colon, there was no association between transverse colon configuration and position change (► **Fig. 7**).

In a few cases, a right lateral or prone position was required for progression in the proximal colon, and ScopeGuide demonstrated that these positions were often required for a mobile intraperitoneal cecum that was medially dependent when patients were lying in the left lateral position (► **Fig. 8**).



► **Fig. 8** ScopeGuide image showing a midline cecum that required a right lateral position change in the ascending colon.

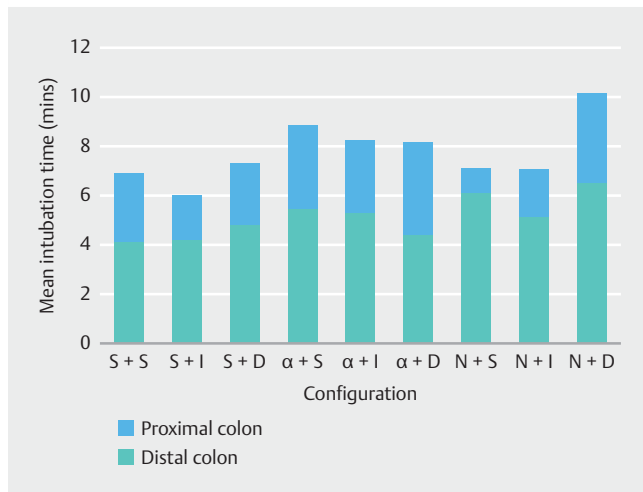
Intubation times

The mean intubation times, as well as separate proximal and distal colon times, were recorded for each configuration (► **Fig. 9**).

An N-loop in the sigmoid colon and a deep loop in the transverse colon resulted in the longest mean intubation time. However, there were no statistically significant differences in the proximal, distal, or overall completion times with regards to colonic configuration.

Discussion

Previous studies have investigated the variation in configuration of the colon based on real-time magnetic image-assisted colonoscopy (e.g., ScopeGuide). Although the incidence of transverse loop formation has been described [8, 14, 15], no difference in incidence between the sexes could be shown. We have added novel and more precise definitions for the extent of transverse looping and have included straight configurations in the proximal and distal colon in our analysis. With these definitions, we found that deep transverse loops were more common in women, straight transverse colons were more common in men, and the frequency of intermediate transverse loops was similar in both sexes. These data are supported by Sadahiro et al. [16] and Saunders et al. [17], who both found that females had longer transverse colons, as well as longer overall colons, using barium enema studies. Furthermore, Saunders et al. [18] and Hanson et al. [19] have both shown that the redundancy (or length) of the transverse colon is strongly associated with more difficult colonoscopy, using barium enema studies and CT colonography, respectively. It is interesting to speculate why there may be a difference between the sexes and confounding fac-



► **Fig. 9** Relationship between colonic configurations and time for completion of colonoscopy. Distal colon: S = straight, α = alpha-loop, N = N-loop. Proximal colon: S = straight, I = intermediate loop, D = deep loop.

tors such as body mass index, previous pelvic surgery, or pregnancy have not been investigated.

Our study has also highlighted an increased prevalence of sigmoid N-loops in females compared to males. This particular type of looping pattern has been associated with the highest number of demands for self-administered analgesia by patients during standard air and water-exchange colonoscopies [20], and 90% of painful episodes in this study occurred during shaft straightening maneuvers. The relatively higher occurrence of sigmoid N-loops and deep transverse loops in females in our study might offer an anatomical explanation for why colonoscopy is considered to be more difficult in this patient group [21]. Recent data suggesting that starting colonoscopy in the right lateral position results in a more comfortable examination for females and shorter cecal intubation times may also be explained on this basis [22].

Although we have demonstrated an increased prevalence of painful sigmoid colonic configuration among females and an inverse relationship for males, colonic configuration was not found to impact on the overall colonoscopy completion times, nor the separate proximal and distal colon completion times. Additional studies may show that this is a common finding in experienced hands. Furthermore, the incidence of sigmoid alpha-loops in our study was greater than previously reported, and this could be a reflection of technique, since the alpha maneuver [7] can be used to deliberately insert an alpha-loop to avoid tight angulation at the sigmoid-descending junction. An alternative technique for resolving N-loops, as demonstrated in this study, is to move patients into a supine position before the sigmoid-descending junction.

Transverse gamma-loops are typically found in about 1% of cases, and none were encountered in this study. However, a right-lateral or prone position was required for completion in a few cases, and ScopeGuide demonstrated that these positions

were often required when there was a mobile intraperitoneal cecum.

Much has been written about magnetic imaging as an aid to teaching colonoscopy by facilitating loop recognition and learning the methods for their resolution. However, experience from the routine use of ScopeGuide in many centers in the UK now extends to greater than 20 years, and all bowel cancer colonoscopy screening centers use this technology. Nerup and Preisler [23, 24] have shown in patients and models, by means of a calculated colonoscopy progression score (CoPS) derived from image analysis of the ScopeGuide recording, that experts make faster progression through the colon. A high CoPS score is likely to reflect superior tip and torque control, loop recognition, and resolution. This study highlights differences in looping patterns between the sexes and shows, in expert hands, little variation in completion times between the different configurations despite the need for position change and other loop-resolving maneuvers. In our cohort, 32% of the patients were able to have an un-sedated procedure.

Competing interests

None

References

- [1] Bowles CJA, Leicester R, Romaya C et al. A prospective study of colonoscopy practice in the UK today: are we adequately prepared for national colorectal cancer screening tomorrow? *Gut* 2004; 53: 277–283
- [2] Gavin DR, Valori RM, Anderson JT et al. The national colonoscopy audit: a nationwide assessment of the quality and safety of colonoscopy in the UK. *Gut* 2013; 62: 242–249
- [3] Cirocco WC, Rusin LC. Factors that predict incomplete colonoscopy. *Dis Colon Rectum* 1995; 38: 964–968
- [4] Mitchell RMS, McCallion K, Gardiner KR et al. Successful colonoscopy; completion rates and reasons for incompleteness. *Ulster Med J* 2002; 71: 34–37
- [5] Koido S, Ohkusa T, Nakae K et al. Factors associated with incomplete colonoscopy at a Japanese academic hospital. *World J Gastroenterol* 2014; 20: 6961–6967
- [6] Anderson JC, Messina CR, Cohn W et al. Factors predictive of difficult colonoscopy. *Gastrointest Endosc* 2001; 54: 558–562
- [7] Haycock A, Cohen J, Saunders BP et al. *Cotton and Williams' Practical Gastrointestinal Endoscopy*. Hoboken, NJ: John Wiley & Sons; 2013
- [8] Shah SG, Saunders BP, Brooker JC et al. Magnetic imaging of colonoscopy: an audit of looping, accuracy and ancillary maneuvers. *Gastrointest Endosc* 2000; 52: 1–8
- [9] Park HJ, Hong JH, Kim HS et al. Predictive factors affecting cecal intubation failure in colonoscopy trainees. *BMC Med Educ* 2013; 13: 5
- [10] Sedlack RE. Training to competency in colonoscopy: assessing and defining competency standards. *Gastrointest Endosc* 2011; 74: 355–366
- [11] Spier BJ, Benson M, Pfau PR et al. Colonoscopy training in gastroenterology fellowships: determining competence. *Gastrointest Endosc* 2010; 71: 319–324

- [12] Ward ST, Mohammed MA, Walt R et al. An analysis of the learning curve to achieve competency at colonoscopy using the JETS database. *Gut* 2014; 63: 1746–1754
- [13] Chen Y, Duan YT, Xie Q et al. Magnetic endoscopic imaging vs standard colonoscopy: Meta-analysis of randomized controlled trials. *World J Gastroenterol* 2013; 19: 7197–7204
- [14] Eickhoff A, Pickhardt PJ, Hartmann D et al. Colon anatomy based on CT colonography and fluoroscopy: Impact on looping, straightening and ancillary manoeuvres in colonoscopy. *Dig Liver Dis* 2010; 42: 291–296
- [15] Shah SG, Brooker JC, Williams CB et al. Effect of magnetic endoscope imaging on colonoscopy performance: a randomised controlled trial. *Lancet* 2000; 356: 1718–1722
- [16] Sadahiro S, Ohmura T, Yamada Y et al. Analysis of length and surface area of each segment of the large intestine according to age, sex and physique. *Surg Radiol Anat* 1992; 14: 251–257
- [17] Saunders BBP, Fukumoto M, Halligan S et al. Why is colonoscopy more difficult in women? *Gastrointest Endosc* 1996; 43: 124–126
- [18] Saunders B, Halligan S, Jobling C et al. Can barium enema indicate when colonoscopy will be difficult? *Clin Radiol* 1995; 50: 318–321
- [19] Hanson ME, Pickhardt PJ, Kim DH et al. Anatomic factors predictive of incomplete colonoscopy based on findings at CT colonography. *Am J Roentgenol* 2007; 189: 774–779
- [20] Leung JW, Thai A, Yen A et al. Magnetic endoscope imaging (Scope-Guide) elucidates the mechanism of action of the pain-alleviating impact of water exchange colonoscopy - attenuation of loop formation. *J Interv Gastroenterol* 2012; 2: 142–146
- [21] Anderson ML, Pasha TM, Leighton JA. Endoscopic perforation of the colon: lessons from a 10-year study. *Am J Gastroenterol* 2000; 95: 3418–3422
- [22] Vergis N, McGrath AK, Stoddart CH et al. Right Or Left in COLonoscopy (ROLCOL)? A randomized controlled trial of right- versus left-sided starting position in colonoscopy *Am J Gastroenterol* 2015; 110: 1576–1581
- [23] Nerup N, Preisler L, Svendsen MBS et al. Assessment of colonoscopy by use of magnetic endoscopic imaging: design and validation of an automated tool. *Gastrointest Endosc* 2015; 81: 548–554
- [24] Preisler L, Søndergaard Svendsen MB, Søndergaard B et al. Automatic and unbiased assessment of competence in colonoscopy: exploring validity of the Colonoscopy Progression Score (CoPS). *Endosc Int open* 2016; 4: E1238–E1243