

Isolated Anterior Dislocation of the Radial Head with Atypical Presentation in an Adult: A Case Report*

Luxação anterior isolada da cabeça radial com apresentação atípica em um adulto: Relato de caso

Rajeev Kansay¹  Sandeep Gupta¹ Ashwani Soni¹ Anubhav Malhotra¹ Sudhir Kumar Garg¹

¹Department of Orthopedics, Government Medical College Hospital, Chandigarh, India

Address for correspondence: Rajeev Kansay, MD, Department of Orthopedics, Government Medical College Hospital, Chandigarh, India (e-mail: drkansay@yahoo.co.in).

Rev Bras Ortop 2019;54:746–750.

Abstract

Isolated anterior dislocation of the radial head is rarely reported. To date, only five cases have been reported in the world literature. In all of these cases, the patients presented with restricted supination–pronation movements of the forearm with maintained elbow flexion–extension. We report an unusual case of isolated anterior radial head dislocation in an 18-year-old male, who presented with maintained supination–pronation movements of the forearm but restricted elbow flexion–extension. Closed reduction was attempted, but it failed. Hence, an open reduction was performed. However, the reduction was unstable due to rupture of the annular ligament. Hence, the repair of the annular ligament was performed, and a radio-ulnar Kirschner wire was passed to maintain the reduction of the proximal radio-ulnar joint, thus keeping the annular ligament stress-free, facilitating its healing. At 12 months of follow-up, the patient had normal elbow function and complete range of motion.

Keywords

- ▶ elbow joint
- ▶ joint dislocations
- ▶ radius
- ▶ articular ligaments

Resumo

A literatura sobre a luxação anterior isolada da cabeça radial é escassa, com apenas cinco casos relatados no mundo inteiro até hoje. Em todos esses casos, os pacientes apresentaram movimentos de supinação–pronação restritos do antebraço, e manutenção da flexão–extensão do cotovelo. Os autores apresentam um caso incomum de luxação de cabeça radial anterior isolada em um paciente do sexo masculino de 18 anos, que apresentou movimentos de supinação–pronação no antebraço e restrição na flexão–extensão do cotovelo. A redução fechada foi tentada, mas sem sucesso. Assim, foi feita a redução aberta. No entanto, a redução foi instável devido à ruptura do ligamento anular. Por isso, o reparo do ligamento anular foi realizado, e um fio de Kirschner rádio-ulnar foi inserido para manter a redução da articulação rádio-ulnar proximal, evitando estresse sobre o ligamento anular, facilitando assim sua cicatrização. Aos 12 meses de seguimento, o paciente apresentava função normal do cotovelo e amplitude de movimento completa.

Palavras-chave

- ▶ articulação do cotovelo
- ▶ luxações articulares
- ▶ rádio
- ▶ ligamentos articulares

* Originally Published by Elsevier Editora Ltda.

received
September 3, 2017
accepted
March 13, 2018

DOI <https://doi.org/10.1016/j.jrboe.2018.03.003>.
ISSN 0102-3616.

Copyright © 2019 by Sociedade Brasileira de Ortopedia e Traumatologia. Published by Thieme Revinter Publicações Ltda, Rio de Janeiro, Brazil

License terms



Introduction

Isolated dislocation of the radial head in an adult is an uncommon injury; hence, it can easily be missed. There are just over 20 cases reported in the world literature of posttraumatic isolated radial head dislocation.¹ Most cases reported earlier suffered from posterior dislocation of the radial head.² Only five cases of anterior radial head dislocation have been reported,²⁻⁶ with the patients presenting to the hospital with restricted supination-pronation movements of the forearm and maintained flexion-extension at the elbow joint.¹ Closed reduction has been shown to be successful in most cases.⁷ We report an unusual case of isolated anterior dislocation of the radial head with atypical presentation in an adult, with maintained supination-pronation movements but restricted flexion-extension at the elbow joint, in which open reduction had to be performed, since closed reduction failed due to the presence of intra-capsular button-holing of the radial head.

Case Report

An 18-year-old male college student, who sustained an injury to his left elbow during a wrestling match at a sports academy. He fell down backwards on an outstretched hand with the wrist in dorsiflexion. He complained of pain and swelling on the anterior aspect of the left elbow, and was immediately sent to the Emergency Room (ER) of our hospital. The elbow was held in flexion and partial pronation. Tenderness was present on the anterolateral aspect of the left elbow and the radial head was palpable anteriorly. There was no swelling or tenderness over the ulna or the forearm or the distal radio-ulnar joint. The patient had restricted flexion-extension movements with active range of motion from 30 to 100 degrees, but there was no restriction in the supination and pronation movements of the forearm. The distal neurovascular status of left upper limb was normal. An X-ray was performed, and it showed isolated anterior dislocation of the radial head (► Fig. 1). Closed reduction was attempted in the ER using supination and pronation maneuvers, but it failed. A computed tomography (CT) scan of the elbow was performed to rule out any small bone fragments causing difficulty in reduction (► Fig. 2). He was given an arm

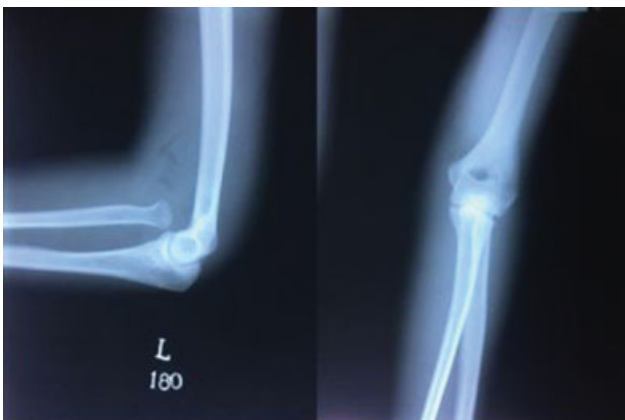

Fig. 1 Anteroposterior and lateral radiographs of the left elbow showing isolated anterior radial head dislocation.

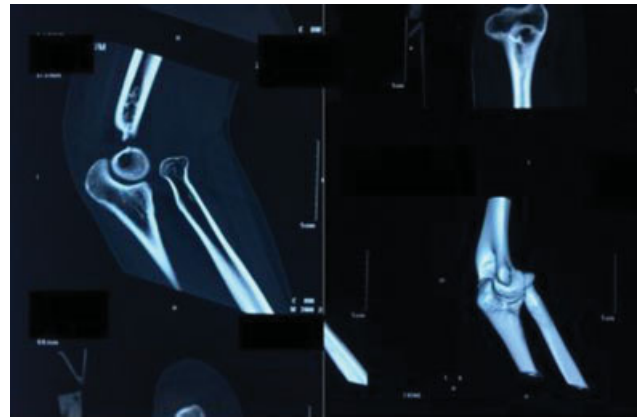


Fig. 2 Computed tomography scan of the left elbow showing anterior dislocation of the radial head with no intra-articular bony fragment.

pouch sling, an ice pack and analgesics, and was advised about the need for open reduction. The Boyd approach was used for exposure of the radial head. A plane was made between the extensor carpi ulnaris (ECU) and anconeus muscles. Intra-capsular button-holing of the radial head was found intra-operatively, and was released. The radial head was reduced with 90 degrees of flexion at the elbow joint and forearm in complete supination. However, the reduction was unstable due to rupture of the annular ligament. Hence, a repair of the annular ligament was performed. A radio-ulnar Kirschner wire was passed to maintain the reduction of the proximal radio-ulnar joint (► Fig. 3), thus keeping the annular ligament stress-free, facilitating its healing. A Plaster-of-Paris (POP) back-slab was placed. The postoperative distal neurovascular status was normal. The wire was removed after 6 weeks (► Fig. 4), and elbow mobilization started. The patient underwent a supervised physiotherapy program. At 12 months of follow-up, the range of motion of the patient was: 0-140 degrees of flexion-extension arc, 70 degrees of pronation, and 85 degrees of supination (► Fig. 5), which is consistent with the reference values of the American Society for Surgery of the Hand. The patient had no limitations regarding the performance of daily activities, and returned to the pre-injury Tegner level of sports activity.

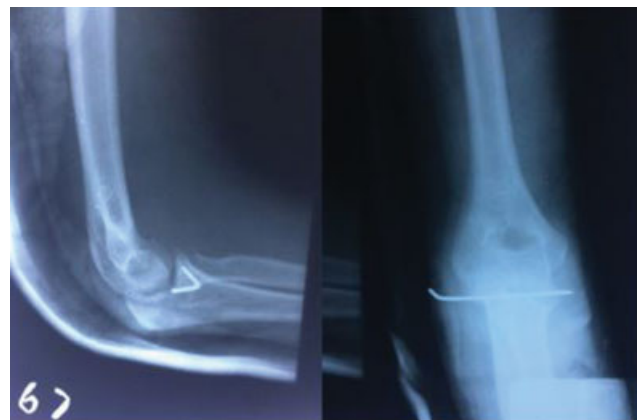


Fig. 3 Postoperative radiograph showing Kirschner wire passed through the superior radio-ulnar joint to maintain the reduction.

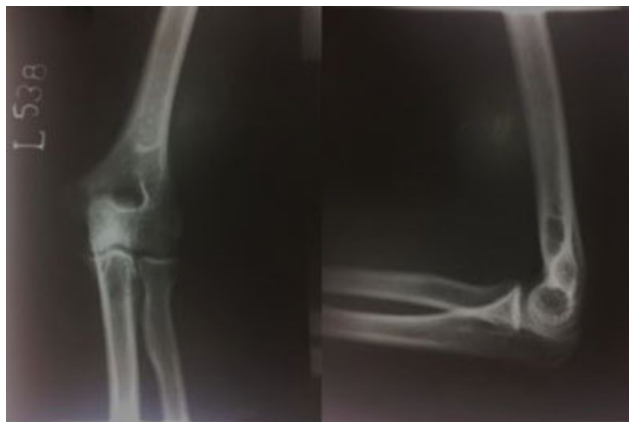

Fig. 4 Anteroposterior and lateral radiographs after the removal of the Kirschner wire at 6 weeks.

Discussion

Isolated anterior dislocation of the radial head is rarely reported in the world literature. The patients usually present with maintained flexion–extension at the elbow joint but restricted supination–pronation movements of the forearm.¹ In the present case, there was an atypical presentation with restricted elbow flexion–extension but maintained supination–pronation movements of the forearm.

Various mechanisms have been postulated for isolated dislocation of the radial head, like hyperpronating forces acting on an already pronated forearm while falling backwards with an extended elbow or falling forward on an extended elbow with the forearm in pronation and rolling of the body, causing further hyperpronation.³ In the present case, the likely mechanism of injury would be the former one.

Takami et al⁴ described a direct mechanism of injury, with direct trauma occurring to a semi-flexed elbow causing anterior dislocation of the radial head.

Bonatus et al³ speculated that the injury occurs in a position of hyperextension and supination, and also proposed that the reduction maneuver to reduce the dislocation depended upon the initial position of the forearm at presentation. Those presenting with forearms in pronation required a supination force for the reduction and vice versa. This held true for the present case, since the patient presented with pronation, and the reduction was achieved regarding supination.

Closed reduction of the radial head has been successful in most cases.⁷ In very few cases, open reduction has been required. In the present case, closed reduction failed; hence, an open reduction was performed. Intra-capsular buttonholing of the radial head was found intra-operatively, thus leading to a failed attempt at closed reduction. Upon releasing the hole, the radial head reduced easily.

The annular ligament is the most important structure stabilizing the proximal radio-ulnar joint. Dislocation of the radial head is not possible without damage to the annular ligament.⁸ In the present case, the annular ligament was found to be disrupted; hence, the repair was performed along with passing a superior radio-ulnar Kirschner wire. A stable elbow with normal function at 12 months of follow-up is suggestive of healing of the annular ligament.

Diagnosing and reducing the dislocation promptly is of utmost importance. There are some complications associated with this injury, like stiff elbow, recurrent radial head instability, and problems associated with Kirschner wire fixation. Recurrent radial head instability is addressed based on the congruence of the radial head reduction. If the radial head can be congruously reduced, annular ligament reconstruction is

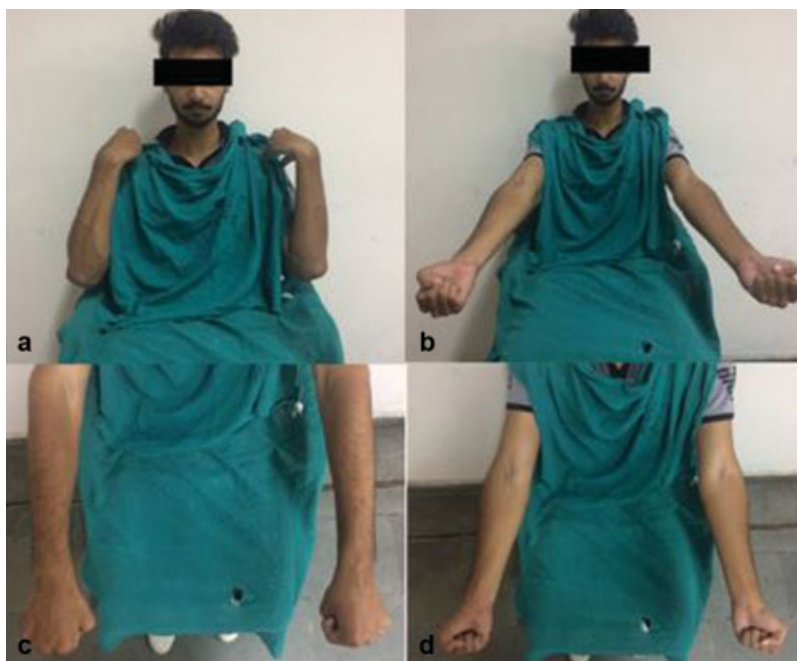

Fig. 5 At 12 months, range of motion; (a) flexion, (b) extension, (c) supination, (d) pronation.

the procedure of choice. If there is any incongruence, then the radial head should be excised.²

In summary, isolated anterior dislocation of the radial head is a rare injury. The reduction maneuver depends on the position of forearm at the initial presentation. Closed reduction may not be successful in every case. After the reduction, the stability should always be checked. Addressing these injuries should be a priority in order to prevent stiffness of the elbow and recurrent radial head instability. If managed promptly and under a regular and supervised physiotherapy regime, the patient can restore the normal range of motion and elbow function.

Informed consent

Written informed consent was obtained from the patient for the publication of the data concerning the case.

Conflicts of interest

The authors have none to declare.

References

- 1 Rethnam U, Yesupalan RS, Bastawrous SS. Isolated radial head dislocation, a rare and easily missed injury in the presence of major distracting injuries: a case report. *J Med Case Reports* 2007;1:38
- 2 Watanabe K, Iwabu S, Hosoya T. Traumatic isolated anterior dislocation of the radial head in an adult: a case report. *J Shoulder Elbow Surg* 2005;14(05):554–556
- 3 Bonatus T, Chapman MW, Felix N. Traumatic anterior dislocation of the radial head in an adult. *J Orthop Trauma* 1995;9(05):441–444
- 4 Takami H, Takahashi S, Ando M. Irreducible isolated dislocation of the radial head. *Clin Orthop Relat Res* 1997;(345):168–170
- 5 Kong KC. Irreducible isolated dislocation of the radial head in a skeletally mature teenager. A case report. *Arch Orthop Trauma Surg* 1993;112(06):304–305
- 6 Salama R, Wientroub S, Weissman SL. Recurrent dislocation of the head of the radius. *Clin Orthop Relat Res* 1977;(125):156–158
- 7 El Ibrahim A, Shimi M, Daoudi A, Elmrini A. Isolated, traumatic posterior dislocation of the radial head in an adult: A new case treated conservatively. *J Emerg Trauma Shock* 2010;3(04):422–424
- 8 Wiley JJ, Pegington J, Horwich JP. Traumatic dislocation of the radius at the elbow. *J Bone Joint Surg Br* 1974;56B(03):501–507

