


# Tarsal Navicular Fracture in a Parkour Practitioner, a Rare Injury – Case Report and Literature Review\*

## *Fratura do escafoide társico em um praticante de parkour, uma lesão rara – Relato de Caso e Revisão da Literatura*

Samir Karmali<sup>1</sup>  Jorge Teixeira Ramos<sup>1</sup> João Almeida<sup>1</sup> André Barros<sup>1</sup> Pedro Campos<sup>1</sup>  
Daniel Sá da Costa<sup>1</sup>

<sup>1</sup> Department of Orthopedic Surgery, Hospital Vila Franca de Xira, Vila Franca de Xira, Portugal

Address for correspondence Samir Karmali, Departamento de Cirurgia Ortopédica, Hospital Vila Franca de Xira, Rua Calouste Gulbenkian 1, 2600-009, Vila Franca de Xira, Portugal (e-mail: samirkarmali@hotmail.com).

Rev Bras Ortop 2019;54:739–745.

### Abstract

Tarsal navicular fractures, as well as other midfoot injuries, are rare, and can result in severe impairment if not properly treated. Parkour, a modern sport, is gaining popularity among young individuals in urban areas, and is prone to result in high-energy trauma, which is scarcely described in the literature. The following is a report of a rare case of tarsal navicular fracture in a 17-year-old male, sustained during parkour practice, which was treated successfully with open reduction and internal fixation. The description of the case emphasizes the challenges of its approach; the discussion highlights the treatment options and goals. The case should also raise awareness about the increasing occurrence of these uncommon lesions.

### Keywords

- ▶ bone fractures
- ▶ tarsal bones
- ▶ tarsal joints
- ▶ sports
- ▶ orthopedic procedures/methods

### Resumo

As fraturas do escafoide társico, bem como outras lesões do mediopé, são raras, e podem resultar em incapacidade grave se não forem tratadas adequadamente. *Parkour*, um esporte moderno, está ganhando popularidade entre os jovens em áreas urbanas, e é propenso a traumatismos de alta energia, sendo estes escassamente descritos na literatura. O presente relato trata de um caso de fratura rara do escafoide társico em um paciente do sexo masculino de 17 anos, ocorrida durante a prática de *parkour*, que foi tratada com sucesso, com redução aberta e fixação interna. A descrição do caso enfatiza os desafios na sua abordagem; a discussão destaca as opções de tratamento e seus objetivos. O caso também deve alertar sobre a ocorrência crescente dessas lesões incomuns.

### Palavras-chave

- ▶ fraturas ósseas
- ▶ ossos do tarso
- ▶ articulações társicas
- ▶ esportes
- ▶ procedimentos/métodos ortopédicos

## Introduction

The tarsal navicular, a crescent shaped-bone in the midfoot, is named after its resemblance to a boat (from the Latin word “navis”).<sup>1</sup> It plays a keystone role in the medial column of the

foot, supporting the majority of the axial load to the midfoot during weight bearing and push-off;<sup>2,3</sup> it also forms part of the Lisfranc (naviculocuneiform) and the Chopart (talonavicular) joints, the latter being responsible for almost 80% of hindfoot motion.<sup>1–8</sup> Due to its particular anatomical and functional features, as well as its tenuous radial blood supply,<sup>3,5,9,10</sup> injuries to the navicular bone (or the midfoot) can have severe consequences, causing disability. Fortunately, midfoot injuries are rare (they comprise about 5% of all foot injuries),<sup>6</sup> with

\* Work performed at the Department of Orthopedic Surgery, Hospital Vila Franca de Xira, Vila Franca de Xira, Portugal. Originally Published by Elsevier.

received  
November 8, 2017  
accepted  
December 23, 2017

DOI <https://doi.org/10.1016/j.rboe.2017.12.009>  
ISSN 0102-3616.

Copyright © 2019 by Sociedade Brasileira de Ortopedia e Traumatologia. Published by Thieme Revinter Publicações Ltda, Rio de Janeiro, Brazil

License terms



fractures in this area having an overall incidence of 0.45%.<sup>11</sup> The subgroup of navicular fractures is uncommon, and this injury is even more rare.<sup>2,3</sup> Although most of these are avulsion-type fractures (accounting for almost 50% of navicular fractures),<sup>3,5,12</sup> the literature describes a higher frequency of more complex and high-energy fractures (as a result of motor vehicle accidents, sport injuries and falls).<sup>1,2,4,6</sup>

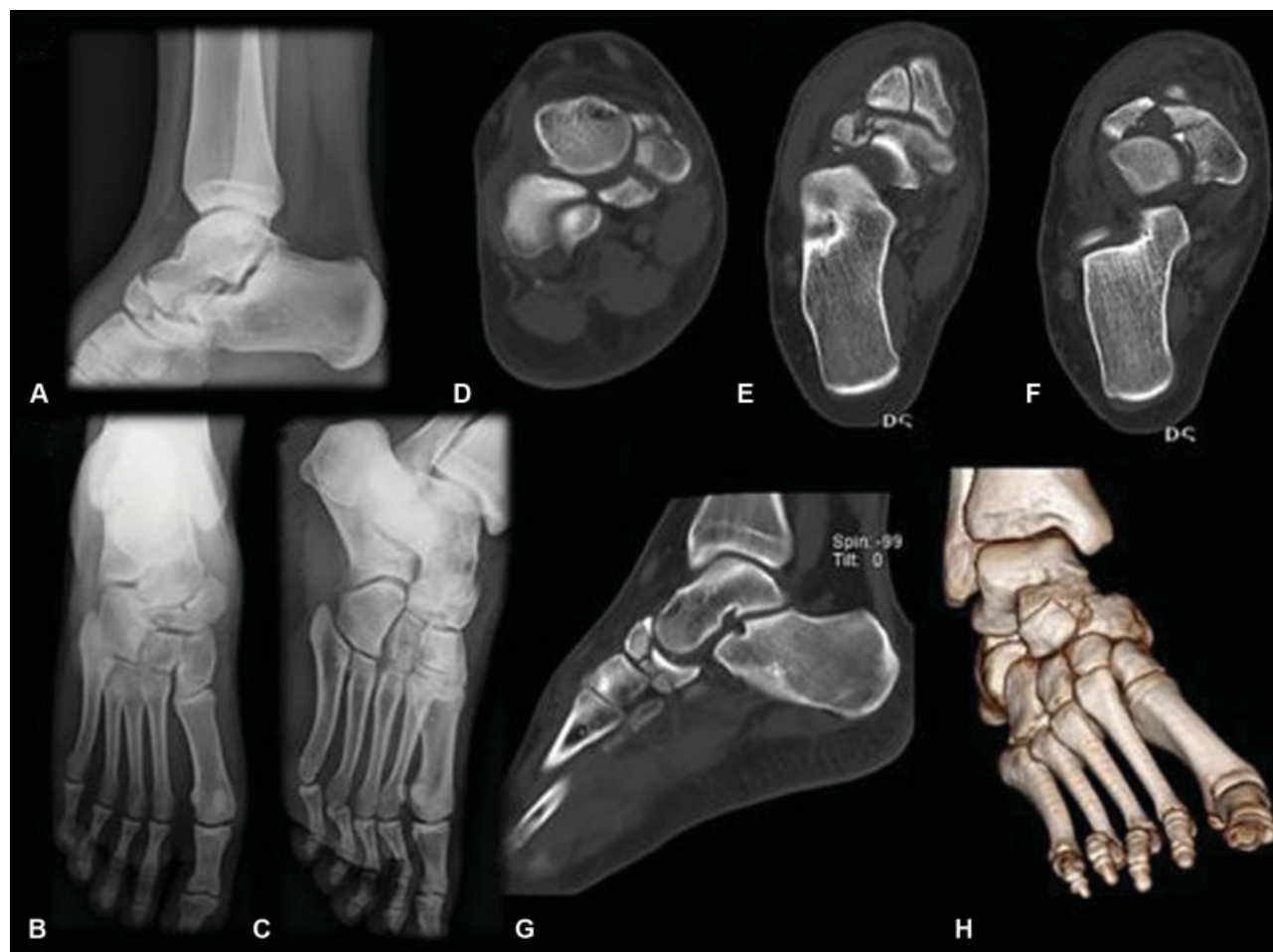
Recently, parkour has been emerging as an extreme sport, in which the practitioners (known as traceurs) aim to get from one point to another in a complex setting (usually urban areas) in the fastest and most efficient way possible, without auxiliary equipment.<sup>13-15</sup> This modality is prone to high-energy and complex lesions, but few cases have been described in the literature.

The authors report a rare case of a tarsal navicular fracture during parkour practice.

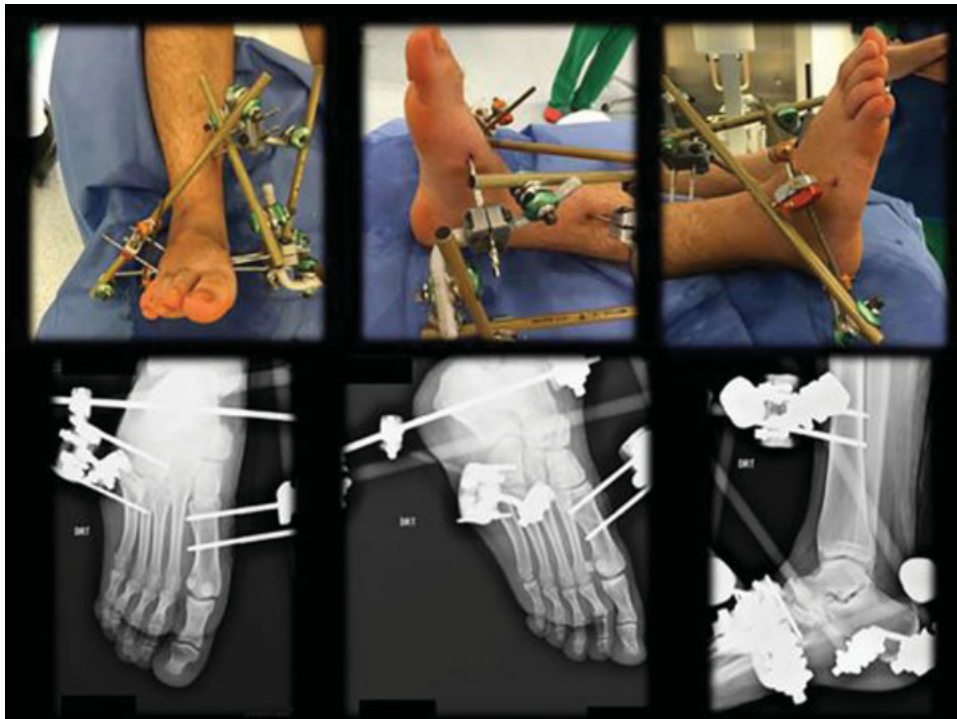
### Case Report

A 17-year-old male, high-school student and traceur, with no prior relevant medical history, presented to our pediatric emergency department (in March 2016) after sustaining a 3.5-m fall while jumping from a building (first floor) during a

parkour exercise. He only complained about pain in his right foot, which was the landing contact surface at the fall, and was in a plantar flexion and forefoot abduction position at that time. Clinically, the foot had a prominent soft-tissue edema, and the neurovascular assessment showed no impairment; compartment syndrome was excluded. A full setup of foot and ankle X-rays (anteroposterior, lateral and Myerson 30° medial oblique views) was obtained, and showed a displaced tarsal navicular fracture with articular comminution, loss of height of the medial arch, and shortening of the medial column of the foot (classified as a Sangeorzan type III/OTA 74 type C), with no other apparent lesions, which were confirmed by multi-axial and three-dimensional (3D) reconstruction computed tomography (CT) imaging (►Fig. 1). Due to the poor conditions of the soft tissue, external fixation with tibio-calcaneo-cuboidometatarsic ligamentotaxis was performed (►Fig. 2). Two weeks later (under general anesthesia, with tourniquet usage and supine positioning), through a dorsal approach (just lateral to the dorsalis pedis artery) with a minimally-invasive medial incision (between the tibialis anterior and posterior tendons), open reduction and internal fixation (ORIF) with an anatomic plate and adjunct external spanning fixation



**Fig. 1** Imaging studies of the right foot and ankle showing a displaced tarsal navicular fracture with articular comminution, loss of height of the medial arch, and shortening of the medial column of the foot (classified as a Sangeorzan type III/OTA 74 type C). (A) Lateral view X-ray of the right ankle; (B) anteroposterior view of the right foot; (C) 30° medial oblique view of the right foot; (D) computed tomography (CT) axial view; (E) and (F) CT coronal views; (G) CT sagittal view; (H) CT three-dimensional reconstruction.

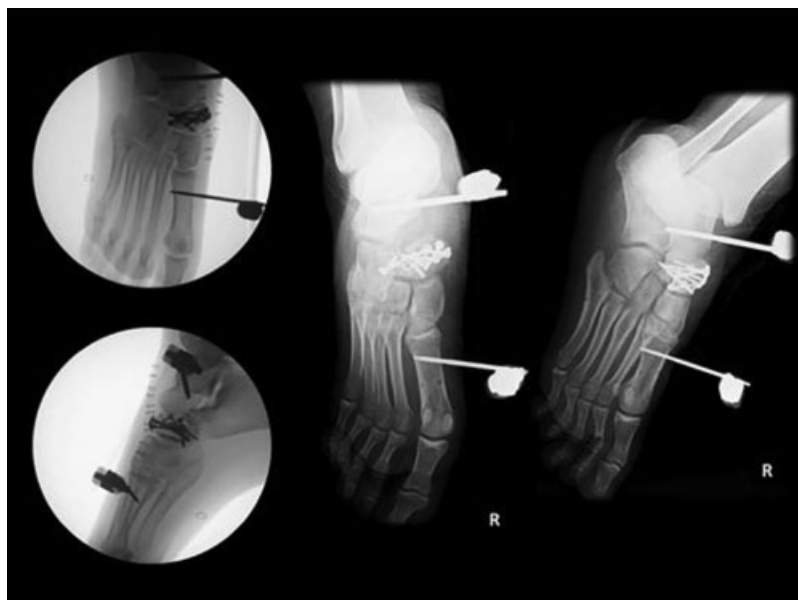

**Fig. 2** Tibio-calcaneo-cuboido-metatarsic ligamentotaxis (top: external appearance; bottom: X-ray evaluation).

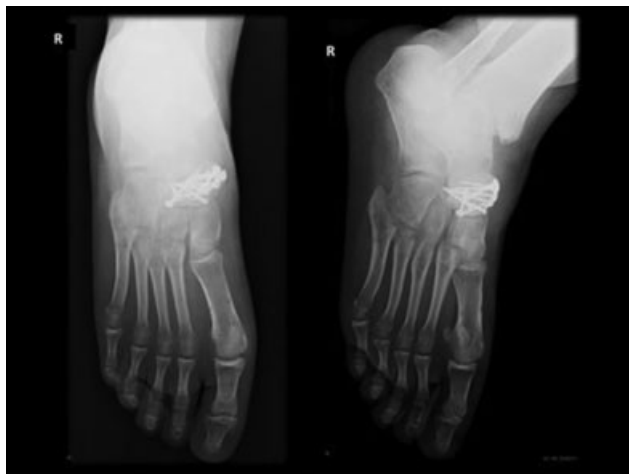(with talus neck and first metatarsal pin placement) was performed (►**Fig. 3**). The patient was referred to outpatient care with non-weight bearing indication for six weeks. After this time, the external fixation was removed, and partial weight bearing was allowed with progressive increments, according to the clinical and radiological assessments. Fifteen weeks after the ORIF, the radiological assessment

showed signs of fracture healing (►**Fig. 4**), and physical activity with no restrictions was allowed.

At 34 weeks of follow-up, the American Orthopedic Foot and Ankle Score (AOFAS) was 87 (out of 100) points. Clinically, the patient had minimal and occasional pain. No union alterations or posttraumatic arthritis were observed. During the course of the treatment, soft-tissue integrity was an



**Fig. 3** Open reduction and internal fixation with an anatomic precontoured plate and adjunct external spanning fixation (with talus neck and first metatarsal pin placement).



**Fig. 4** Fracture healing (15 weeks postoperatively).

important issue, especially in the early period after the ORIF. However, at the end, no complications were observed, and the final esthetic result was good. Biomechanically, there was no impairment in high-demand activities such as running, although there was a slight limitation in inversion compared to the contralateral foot. Upon clinical examination, he had normal gait and no varus/valgus alignment or pes cavus/planus deformity compared to the contralateral foot (→ Fig. 5).

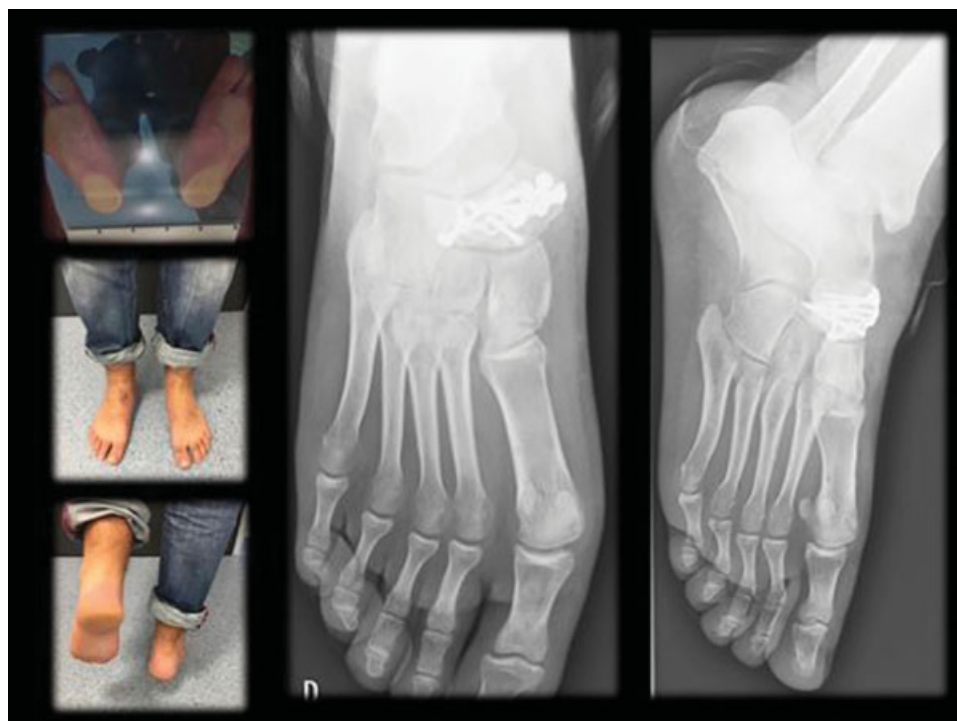
The patient was very satisfied with the outcome, and at one year after the ORIF, he was performing activities like rock-climbing without any complaints or limitations (AOFAS of 90 points).

## Discussion

There are few studies about parkour injuries in the literature,<sup>13-15</sup> but one retrospective cross-sectional study<sup>13</sup> showed that most of the injuries affect the upper extremity (58%), with lesions being more frequent distally in the limb; in the lower extremity (27%), the distribution of the injuries follows an opposite fashion. Landing is the movement that causes the majority of the injuries (61%).<sup>13</sup>

As previously stated, tarsal navicular fractures are rare. In 1989, Sangeorzan et al<sup>4</sup> classified the tarsal navicular fractures according to the direction of the fracture line, the pattern of disruption of the surrounding joints, and the direction of displacement of the foot; four principal types – tuberosity, capsular avulsion, stress and navicular body fractures (the last two are divided into three subtypes) – were established, as well as a relationship between injury severity and functional outcome. Compared to avulsion and stress fractures (which are less rare), displaced comminuted articular fractures of the navicular body (type III) often result from high-energy trauma and disrupt the stability of the medial column of the foot.<sup>16-19</sup> The latter (as well as type II) are often associated with other midfoot injuries (calcaneocuboid joint and naviculocuneiform ligaments, which have to be excluded, for example), with the navicular sustaining the axial load usually with the forefoot in plantar flexion and adduction (in type II) or abduction (in type III),<sup>1-4,12</sup> as occurred in the present case.

Tarsal navicular fractures can range clinically from an almost normal foot to a severely injured lower extremity. The high rate of suspicion and awareness of the potential serious injuries (like compartment syndrome) must be addressed



**Fig. 5** At 34 weeks of follow-up: clinical examination (with no valgus/planus or varus/valgus deformity) and radiological assessment.

promptly. Radiological assessment is crucial in establishing the diagnosis. While standard X-rays (including a medial oblique view – a 30° oblique Myerson view, for example) usually suffice to make the diagnosis,<sup>20</sup> the use of CT is invaluable to better characterize the fracture and peri-navicular dislocations (for the planning of the operative treatment), as well as to exclude associated lesions and anatomical variants of the navicular;<sup>21</sup> in fact, one study<sup>22</sup> demonstrated that the sensitivity of the primary radiography (in diagnosing a tarsal navicular fracture) was 33% higher than that of the CT scanning.

The treatment of these fractures aims to ensure the integrity of the talonavicular and naviculocuneiform articular surfaces, as well as the length and stability of the medial column of the foot and the proper insertion of the tibialis posterior tendon.<sup>2,3,6,23</sup> While some navicular fractures can be treated conservatively (those that are not displaced, have an adequate length and stability of the medial column on dynamic examination, and have no associated injuries), the indications for the operative treatment include: joint incongruity  $\geq 2$  mm; medial column shortening  $> 3$  mm; inability to attain or maintain joint reduction; open fractures; associated multiple midfoot injuries; concomitant compartment syndrome; and skin that is tenting or at risk because of fracture displacement.<sup>1-4</sup> In addition, restoration of  $> 60\%$  of the articular surface (visible on the anteroposterior and lateral X-ray views) is critical for the stability the talonavicular joint.<sup>1,3</sup> The ORIF is increasingly becoming the gold standard for displaced comminuted articular reconstructable fractures, as in the present case.<sup>3,4,24</sup> Depending on the comminution of the fracture, a standard middorsal incision or a dual incision, combining a middorsal (between the extensor digitorum brevis and longus, or lateral to the extensor hallucis longus tendon) and an anteromedial incision (especially in type-III fractures, as in the present case) is advised and supported in the recent literature.<sup>1-3,24</sup> In fact, the dual approach provides a better visualization and reduction of the fracture, and spares the soft tissue from excessive retraction, thus avoiding complications in skin and bone healing.<sup>3</sup>

The operative treatment and implant choice can vary according to the displacement, associated injuries, stability of the medial column, comminution of the articular surface, and reconstructability of the fracture, as well as the patient's comorbid factors (diabetes, heavy smoking and vascular impairment, for example), and the overall functional capacity.<sup>1-6,12,18</sup> There is no formal recommendation for the ideal timing of the surgery; when there are no urgent operative indications, surgery should be performed with appropriate diagnostic imaging and soft-tissue envelope conditions.<sup>3</sup>

For displaced comminuted articular fractures with a stable medial column, ORIF with minifragment locking plates provides a good fixation technique and has shown good results, with 90.6 points on the AOFAS 20 weeks post-surgery.<sup>24,25</sup> Autologous bone graft can be used, as it facilitates anatomical restoration and fracture healing due to its osteoconductive and osteoinductive effects.<sup>2,4,26,27</sup> However, bone grafting did not improve the convalescence,

the clinical or function outcomes, and one study<sup>27</sup> also reported calcaneal fracture care. For fractures that have an unstable medial column, as in the present case, adjunct external fixation to the ORIF (positioned on the talus and with transfixation of the cuneiforms as well as the first metatarsal) can be considered. Although its use is not sufficiently supported by the present literature (due to the low incidence of these fractures), it is recognized to be useful in some cases to increase the stability and maintain distraction, enabling the fracture to heal.<sup>2-4,6</sup> An alternative in these types of fracture is the use of internal spanning fixation, especially when interfragmentary compression is not possible; internal spanning fixation serves the same principles of fixation, and can act as a buttress or neutralize forces, thus helping maintain length and stability; they are becoming increasingly used due to the development of new fixation materials.<sup>2,3,6,28</sup> In both techniques, immobilization (with frequent observation of skin conditions, usually using a walker or moonboot device) and weight-bearing restriction should follow a period of at least six weeks.<sup>1-6,28</sup> During this period, a standardized radiograph imaging follow-up should be performed, accessing column alignment, progress of healing, implant failure, loss of reduction and development of posttraumatic osteoarthritis or osteonecrosis.<sup>2-4</sup> After this period, if no complications are observed and the patient is pain-free, partial weight bearing should be allowed for four to six weeks. It is expected that the fracture should consolidate 10 to 12 weeks after surgery.<sup>2</sup> If this is not clearly viewed on standard X-rays, a CT scan should be performed – it can easily reveal the diagnosis of a fracture union complication.<sup>3,25</sup> Compared to magnetic resonance imaging (MRI, which only patients treated with titanium implants can undergo), CT offers the advantage that it can be used regardless of the implant choice. In addition, steel implants, not only are safe for CT imaging, but also present less complications if hardware removal is needed.<sup>3</sup> In the scenario of union complications, a secondary bone grafting and prolonging the time of immobilization can be considered.<sup>2,3</sup> If there are obvious signs of consolidation, the internal spanning fixation or external fixation should be removed (usually 10 to 12 weeks postsurgery or earlier, if good clinical and radiological evolution is observed) enabling the restoration of motion at the Chopart joint complex and avoiding stiffness; weight-bearing should be allowed with increasing loads after this period.<sup>2,3,23-26</sup>

When the fracture involves the naviculocuneiform joints, primary fusion of these joints should strongly be considered, as these are assumed as non-essential for midfoot motion, can stabilize the medial column, and do not result in long-term disability.<sup>1-4</sup> In patients with a complex fracture dislocation, usually a non-reconstructable unstable and displaced fracture, primary arthrodesis should be considered.<sup>1-4</sup> However, every effort should be made first to reconstruct the articular surface of the talonavicular joint, even if it is not perfect; patient function should be assessed, and, if not acceptable, talonavicular fusion can be performed.<sup>1</sup>

Despite satisfactory results and high rates of union, navicular fractures are prone to have complications and long-term impact on functional outcome.

The soft tissue is an important factor that can influence the course of the treatment and the outcome, as shown in the present case. Besides non-union, which was addressed previously, other complications like posttraumatic osteoarthritis, pain, stiffness, deformity, chronic infection, as well as osteonecrosis can lead to long-term disability.<sup>1-4</sup> Pain is not uncommon, and is a major cause of impairment, being present in almost one third of the patients;<sup>4</sup> most often, it results from undiagnosed ligamentous disruption, unrecognized impaction cartilage injuries, posttraumatic osteoarthritis, dorsal impingement of excessive callus, and implant intolerance.<sup>2,3</sup> Posttraumatic osteoarthritis is the most common sequel complicating a navicular fracture. It is usually present in complex body fractures, particularly those that affect the talonavicular joint, and its severity is correlated to articular joint congruity (if less than 60% of the talonavicular joint is reconstructed).<sup>2,3</sup> As it forms part of the Chopart joint complex and is highly important to hindfoot and midfoot kinetics, movement in a damaged talonavicular articular surface can cause pain; this may require a late fusion to eradicate the pain, but can also result in long-term stiffness and loss of motion of the foot, and needs to be discussed with the patient.<sup>2,3,5,17,18,28</sup>

Both non-union and osteonecrosis can occur,<sup>3-6,19,24</sup> the latter specially due to the poorly-vascularized central portion of the navicular body.<sup>10</sup> Unlike non-union, osteonecrosis can lead to substantial deformity, usually in the alignment of the hindfoot varus, as a result of the collapse of the lateral side of the navicular in displaced fractures; this is troublesome, and the complaints can be even more severe than the posttraumatic osteoarthritis that precedes it. In this scenario, correction of the length and the alignment should be considered, often through talonavicular and/or naviculocuneiform fusion, or by a triple arthrodesis in severe cases, with bone-graft interposition.<sup>1-4</sup> In a recent work,<sup>29</sup> the development of pes planus (21%) and pes cavus (26%) has also been reported following navicular fractures; attention should be given to the occurrence of this deformity, and, if symptomatic, it should be treated accordingly.

The good result achieved in the present case can be attributed to the attention given to the particular aspects in the management of these injuries.

The present case should also raise awareness to the increasing frequency of these injuries, as extreme sports like parkour are gaining popularity.

#### Conflicts of interest

The authors have none to declare.

#### References

- Ramadorai MU, Beuchel MW, Sangeorzan BJ. Fractures and dislocations of the tarsal navicular. *J Am Acad Orthop Surg* 2016;24(06):379-389
- Schildhauer TA, Coulibaly MO, Hoffmann MF. Fractures and dislocations of the midfoot and forefoot. In: Court-Brown C, Heckman JD, McKee M, McQueen MM, Ricci W, Tornetta P 3rd, editors. *Rockwood and Green's fractures in adults*. 8th ed. Philadelphia: Wolters Kluwer; 2015:2689
- DiGiovanni CW. Fractures of the navicular. *Foot Ankle Clin* 2004;9(01):25-63
- Sangeorzan BJ, Benirschke SK, Mosca V, Mayo KA, Hansen ST Jr. Displaced intra-articular fractures of the tarsal navicular. *J Bone Joint Surg Am* 1989;71(10):1504-1510
- Eichenholtz SN, Levine DB. Fractures of the tarsal navicular bone. *Clin Orthop Relat Res* 1964;34(34):142-157
- Richter M, Wippermann B, Krettek C, Schratz HE, Hufner T, Therman H. Fractures and fracture dislocations of the midfoot: occurrence, causes and long-term results. *Foot Ankle Int* 2001;22(05):392-398
- Golano P, Fariñas O, Sáenz I. The anatomy of the navicular and periarticular structures. *Foot Ankle Clin* 2004;9(01):1-23
- Astion DJ, Deland JT, Otis JC, Kenneally S. Motion of the hindfoot after simulated arthrodesis. *J Bone Joint Surg Am* 1997;79(02):241-246
- McKeon KE, McCormick JJ, Johnson JE, Klein SE. Intraosseous and extraosseous arterial anatomy of the adult navicular. *Foot Ankle Int* 2012;33(10):857-861
- Waugh W. The ossification and vascularisation of the tarsal navicular and their relation to Köhler's disease. *J Bone Joint Surg Br* 1958;40-B(04):765-777
- Court-Brown CM, Caesar B. Epidemiology of adult fractures: A review. *Injury* 2006;37(08):691-697
- Pinney SJ, Sangeorzan BJ. Fractures of the tarsal bones. *Orthop Clin North Am* 2001;32(01):21-33
- Wanke EM, Thiel N, Groneberg DA, Fischer A. [Parkour—"art of movement" and its injury risk]. *Sportverletz Sportschaden* 2013;27(03):169-176
- McLean CR, Houshian S, Pike J. Paediatric fractures sustained in Parkour (free running). *Injury* 2006;37(08):795-797
- Miller JR, Demoiny SG. Parkour: a new extreme sport and a case study. *J Foot Ankle Surg* 2008;47(01):63-65
- Coulibaly MO, Jones CB, Sietsema DL. Results of 90 consecutive navicular fractures. In: Paper presented at: AAOS 2010 Annual Meeting. 2010
- Howie CR, Hooper G, Hughes SP. Occult midtarsal subluxation. *Clin Orthop Relat Res* 1986;(209):206-209
- Meister K, Demos HA. Fracture dislocation of the tarsal navicular with medial column disruption of the foot. *J Foot Ankle Surg* 1994;33(02):135-137
- Rammelt S, Grass R, Zwipp H. [Nutcracker fractures of the navicular and cuboid]. *Ther Umsch* 2004;61(07):451-457
- Myerson M. *Foot and ankle disorders*. Philadelphia, PA: Saunders; 2000
- Rockett MS, Brage ME. Navicular body fractures: computerized tomography findings and mechanism of injury. *J Foot Ankle Surg* 1997;36(03):185-191
- Haapamaki VV, Kiuru MJ, Koskinen SK. Ankle and foot injuries: analysis of MDCT findings. *AJR Am J Roentgenol* 2004;183(03):615-622
- Sangeorzan BJ, Hansen ST Jr. Early and late posttraumatic foot reconstruction. *Clin Orthop Relat Res* 1989;(243):86-91
- Evans J, Beingessner DM, Agel J, Benirschke SK. Minifragment plate fixation of high-energy navicular body fractures. *Foot Ankle Int* 2011;32(05):S485-S492
- Cronier P, Frin JM, Steiger V, Bigorre N, Talha A. Internal fixation of complex fractures of the tarsal navicular with locking plates. A report of 10 cases. *Orthop Traumatol Surg Res* 2013;99(04):S241-S249
- Schildhauer TA, Nork SE, Sangeorzan BJ. Temporary bridge plating of the medial column in severe midfoot injuries. *J Orthop Trauma* 2003;17(07):513-520

- 27 Longino D, Buckley RE. Bone graft in the operative treatment of displaced intraarticular calcaneal fractures: is it helpful? *J Orthop Trauma* 2001;15(04):280–286
- 28 Apostle KL, Younger AS. Technique tip: open reduction internal fixation of comminuted fractures of the navicular with bridge plating to the medial and middle cuneiforms. *Foot Ankle Int* 2008; 29(07):739–741
- 29 Coulibaly MO, Jones CB, Sietsema DL. Radiographic analysis of navicular fractures, [abstract number: 24250]. Gothenburg, Sweden: 7th SICOT/SIROT Annual International Conference; 2010