Published online: 2019-12-19

Meniscal Ossicle Diagnosed by Magnetic Resonance Imaging: A Case Report*

Osso meniscal diagnosticado através de ressonância magnética: Relato de caso

Henrique Augusto Lino[1] Bianca Lisa de Faria[1] Ana Maria Magalhães Valle Cundari[1]

[1] Faculty of Medicine, University of Itaúna, Itaúna, Brazil

Rev Bras Ortop 2020;55(3):380–382.

Address for correspondence Henrique Augusto Lino, MD, Faculdade de Medicina, Universidade de Itaúna, Itaúna, MG, Brasil (e-mail: henriquelino@live.com).

Abstract

Meniscal ossicle is a rare condition, which is occasionally symptomatic. Even though it has a low incidence, its diagnosis is important, because it may mimic other lesions. Magnetic resonance imaging (MRI) is a sensitive and specific method for its diagnosis. Its clinical behavior is benign and its conservative management is almost always successful, without any need for diagnostic and therapeutic procedures, such as arthroscopy. This report was able to demonstrate the correct diagnosis by MRI.

Keywords
- knee injuries
- knee joint
- tibial menisci
- magnetic resonance imaging

Resumo

O osso meniscal é uma condição rara, ocasionalmente sintomática. Apesar de sua baixa incidência, é importante seu reconhecimento, uma vez que pode mimetizar outras lesões. A ressonância magnética (RM) é um método sensível e específico para seu diagnóstico. A evolução é de curso benigno e favorável ao tratamento conservador, não necessita de procedimentos diagnósticos e terapêuticos, como artroscopia, na grande maioria dos casos. No presente trabalho, foi demonstrado como o diagnóstico correto pode ser feito por RM.

Palavras-chave
- traumatismos do joelho
- articulação do joelho
- meniscos tibiais
- imagem por ressonância magnética

Introduction

The meniscal ossicle is a rare lesion, it is estimated a prevalence of 0.15% in patients undergoing magnetic resonance imaging (MRI), through a cross-sectional study.[1] The finding may occur on imaging examinations of asymptomatic patients, or those undergoing studies due to complaints of intermittent joint pain, edema and limitation of joint movement.[2]

Although its etiology is debated,[3] the finding has a benign evolution and, therefore, its incorrect diagnosis can lead the patient to unnecessary propaedeutic and therapeutic procedures.

This report aims to deal with a case, to demonstrate the importance of recognizing its characteristic findings on MRI.[2,4]

Case Report

A 35-year-old white male patient complained of chronic knee joint pain, with progressive worsening over 1 year. The pain was

* *Originally Published by Elsevier Editora Ltda.*

received December 30, 2017
accepted April 10, 2018

DOI https://doi.org/10.1016/j.rbo.2018.04.004.
ISSN 0102-3616.

Copyright © 2020 by Sociedade Brasileira de Ortopedia e Traumatologia. Published by Thieme Revinter Publicações Ltda, Rio de Janeiro, Brazil

License terms

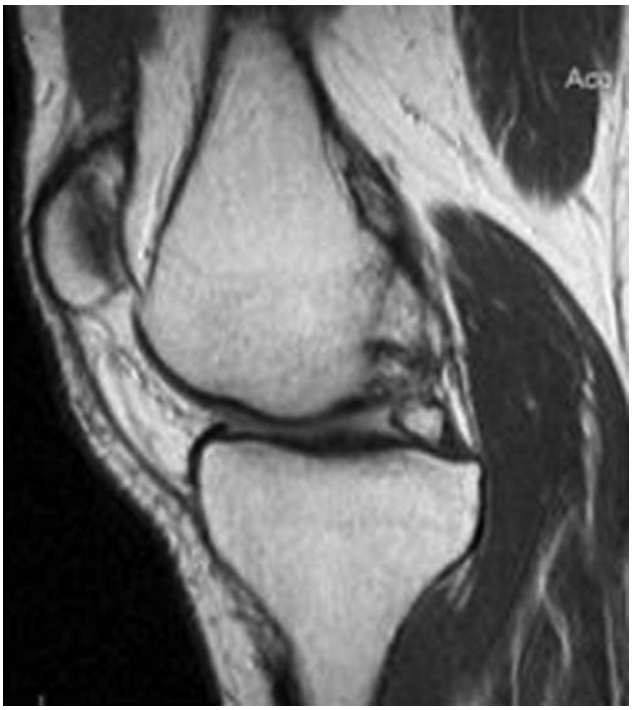

Fig. 1 T1WI weighted image in sagittal plane, demonstrates triangular structure, with intensity equivalent to bone tissue, located in posterior horn topography of the medial meniscus.

exacerbated by exercise and throughout the day, and relieved with painkillers and rest.

He was a healthy patient with no comorbidities and denied a history of trauma. He also had no relevant family history of musculoskeletal disorders, allergic reactions or surgical history.

Physical examination showed pain in the medial compartment of the knee joint during active and passive joint flexion.

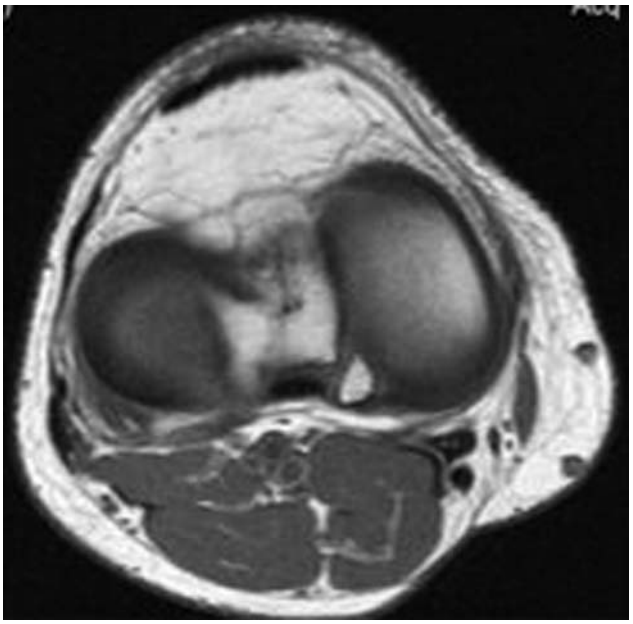

Fig. 2 T1WI weighted image in axial plane, evidences the meniscal ossicle adjacent to the posterior horn of the medial meniscus.

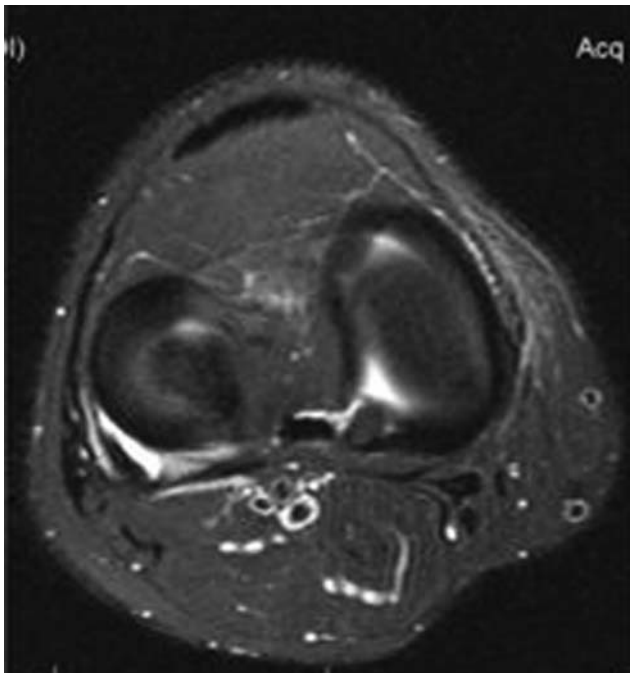

Fig. 3 T2WI fatsat weighted image in axial plane.

There were no limitations of joint movement, stiffness, edema, deformities, phlogistic signs or other musculoskeletal or soft tissue changes. Upon presentation, the attending physician chose to indicate MRI to investigate a suspected meniscal rupture.

The imaging examination was performed the following week, with image acquisition in T1, T2 fatsat and Gradient Recoil Echo T2. The images showed a round or triangular structure, with well-defined contours and intensity similar to bone tissue, in all sequences, in the posterior horn topography of the medial meniscus, as shown in ►**Figures 1–4**. Because of the diagnosis, treatment options with arthroscopic

Fig. 4 Coronal image obtained in GRE T2.

meniscal bone resection or clinical treatment were offered to the patient. The patient opted for a conservative approach, using analgesics and anti-inflammatory drugs for symptom control and clinical follow-up. The evolution was favorable, without the need for additional therapy.

Discussion

The first description with repercussion on this condition was of Burrows,[5] in 1934, with a clinical, radiological and anatomopathological study of the case. Since then, < 50 cases have been reported worldwide.[6] It is estimated that its highest incidence occurs between 12 and 76 years old, with an average diagnosis at 26 years old, and males are 84% of the reported cases.[4]

The lesion may be asymptomatic, be found accidentally, or present with arthralgia, as reported here, and edema. It is rarely associated with nonspecific symptoms or limitation of joint movement.[6] Some authors point out the association of the finding with joint trauma, but its traumatic nature is not consensual.[7] Thus, its clinical presentation is nonspecific and does not allow a definitive diagnosis.

The most sensitive and specific method for diagnosing the lesion is MRI, since it allows characterizing it as isointense to bone tissue. Its most common location is in the posterior horn topography of the medial meniscus. Cases of lateral meniscus, anterior horns or bilateral bones are considerably rarer presentations.

Regarding the clinical and imaging aspects, osteochondral loose bodies, chondrocalcinosis, meniscal rupture, osteochondritis dissecans and synovial osteochondromatosis are its main differential diagnoses.[8] The major importance in its accurate diagnosis is to avoid unnecessary propaedeutics and treatments, since, contrary to the aforementioned conditions, its conservative treatment with anti-inflammatory drugs tends to be sufficient for clinical control.[6,9] Occasionally, treatment with arthroscopic resection is also an option.[6,7,10]

Meniscal bone has a characteristic MRI presentation, which is an accurate method for its diagnosis. When correctly differentiated from other potential differential diagnoses, invasive propaedeutic and therapy are avoided, as its conservative treatment tends to be effective, avoids increased morbidity and expense for the patient or for the public health system.

Conflict of Interests
The authors declare that have no conflict of interests.

References

1 Schnarkowski P, Tirman PF, Fuchigami KD, Crues JV, Butler MG, Genant HK. Meniscal ossicle: radiographic and MR imaging findings. Radiology 1995;196(01):47–50
2 Devgan A, Mukhopadhyay R, Singh A, Gogna P, Singla R, Magu NK. Ossicle in anterior cruciate ligament: a rare occurrence. Case Rep Orthop 2014;2014:616715
3 Lee JH, Wang S II, Jung YR. Meniscal ossicle. J Korean Orthop Assoc 2016;51(02):173–7. Disponível em: https://synapse.koreamed.org/DOIx.php?id=10.4055/jkoa.2016.51.2.173
4 Raustol OA, Poelstra KA, Chhabra A, Diduch DR. The meniscal ossicle revisited: etiology and an arthroscopic technique for treatment. Arthroscopy 2006;22(06):687.e1–687.e3
5 Burrows HJ. Two cases of ossification in the internal semilunar cartilage. Br J Surg 1934;21:404–410
6 Van Breuseghem I, Geusens E, Pans S, Brys P. The meniscal ossicle revisited. JBR-BTR 2003;86(05):276–277
7 Ogassawara R, Zayni R, Orhant E, Noel E, Fournier Y, Hager J-P, Chambat P, Sonnery-Cottet B. Meniscal ossicle in a professional soccer player. Orthop Traumatol Surg Res 2011;97(04):443–446
8 Yen P, Hunter J, Escobedo E. Meniscal Ossicle in the Lateral Meniscus: An Unusual Variant of a Rare Entity. Radiol Case Rep 2016;4(02):289
9 Rohilla S, Yadav RK, Singh R, Devgan A, Dhaulakhandi DB. Meniscal ossicle. J Orthop Traumatol 2009;10(03):143–145
10 Ohishi T, Suzuki D, Yamamoto K, Banno T, Shimizu Y, Ohmura A, Matsuyama Y. Meniscal pullout repair following meniscal ossicle resection: a case report. Knee 2013;20(01):52–57