




# Intraosseous Neurothekeoma of the Hand in a 16-year-old Boy\*

## *Neurotequeoma intraósseo da mão de um jovem de 16 anos*

João José Lobato Guimarães Ferreira Cabral<sup>1</sup>  Inês Maria Spencer Balacó<sup>1</sup>  
Cristina Marta da Gama Gomes Alves<sup>1</sup> António Gabriel de Almeida Matos<sup>1</sup>

<sup>1</sup> Pediatric Orthopedics Service, Centro Hospitalar e Universitário de Coimbra, Hospital Pediátrico, Coimbra, Portugal

Address for correspondence João José Lobato Guimarães Ferreira Cabral, Serviço de Ortopedia Pediátrica, Centro Hospitalar e Universitário de Coimbra, Hospital Pediátrico, Coimbra 3000-602, Portugal (e-mail: cabral.joao@gmail.com).

Rev Bras Ortop 2020;55(1):125–129.

### Abstract

Soft-tissue tumors are rare in the pediatric population. First described in 1969 as myxoma of the nerve sheath, the neurothekeoma is a benign tumor lesion with presumable origin in the nerve sheath. It occurs mainly in female children and presents as a mass of slow, subcutaneous growth, asymptomatic and without alteration of the local pigmentation. It is predominantly located in the head, neck, and extremities of the upper limbs. This report presents the case of a 16-year-old male with a tumor mass originating from the nerve sheath in the 4<sup>th</sup> left metacarpal, intraosseous, and relapsed after previous surgical resection 2 years before this observation. A marginal resection of the tumor mass was performed on the distal region of the fourth metacarpal, followed by curettage of the proximal phalanx and filling with structural autologous bone graft. The patient maintained a favorable postoperative clinical evolution, without local pain or range of motion limitation in his fingers. Radiologically, a progressive trabecular filling of the proximal phalanx of the fourth metacarpal was observed. At 17 months of follow-up, the patient is asymptomatic and shows no signs of relapse. The description of this case serves to increase the familiarity with this rare pathology, and aid its diagnosis and treatment.

### Keywords

- ▶ neurothekeoma
- ▶ hand
- ▶ soft tissue neoplasms
- ▶ biopsy

### Resumo

Os tumores dos tecidos moles são raros em idade pediátrica. Descrito pela primeira vez em 1969 como um mixoma da bainha nervosa, o neurotequeoma é uma lesão tumoral benigna com presumível origem na bainha nervosa. Ocorre maioritariamente em crianças do sexo feminino e apresenta-se como uma massa de crescimento lento, subcutânea, assintomática e sem alteração da pigmentação local. Localiza-se predominantemente na cabeça, no pescoço, e nas extremidades dos membros superiores. Os autores apresentam um caso clínico de um jovem de 16 anos do sexo masculino com

\* Study developed at Pediatric Orthopedics Service, Pediatric Hospital, Hospital and University Center of Coimbra, Portugal. Originally Published by Elsevier Editora Ltda.



**Palavras-chave**

- ▶ neurotequeoma
- ▶ mão
- ▶ neoplasias de tecidos moles
- ▶ biópsia

massa tumoral com origem na bainha nervosa no 4° metacarpo esquerdo, intraóssea e recidivada após ressecção cirúrgica 2 anos antes do estudo. Foi feita ressecção marginal da massa tumoral localizada sobre a região distal do quarto metacarpo e curetagem da falange proximal e preenchimento com enxerto ósseo autólogo corticoesponjoso. O paciente apresentou uma evolução clínica pós-operatória favorável, sem queixas álgicas e sem limitações da mobilidade dos dedos da mão. Radiologicamente, foi observado preenchimento trabecular progressivo da falange proximal do quarto metacarpo. Aos 17 meses de seguimento, o paciente se encontra assintomático e não apresenta quaisquer sinais de recidiva. Com a descrição deste caso, os autores pretendem aumentar a familiaridade com essa rara patologia, seu diagnóstico e tratamento.

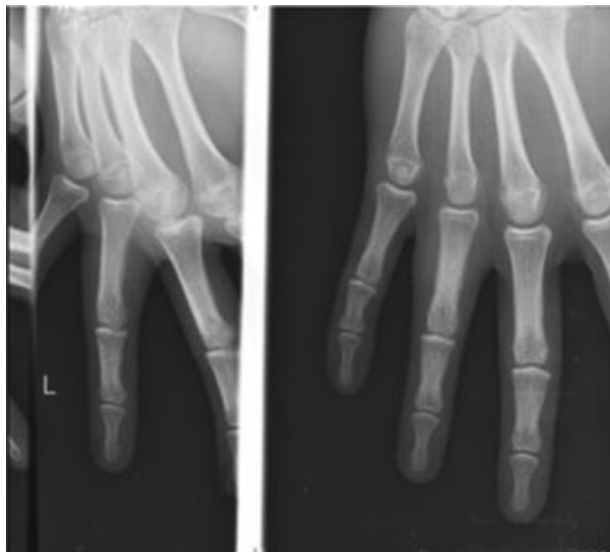**Introduction**

Neurothekeoma is a rare benign tumor lesion, predominantly cutaneous, with presumed origin in the nerve sheath. It occurs mainly in female children and presents as a mass of slow, subcutaneous growth, asymptomatic and without alteration of the local pigmentation. It is predominantly located in the head, neck, and extremities of the upper limbs.<sup>1,2</sup>

This report presents the case of a 16-year-old male with a tumor mass originating from the cubital nerve sheath in the fourth left metacarpal, intraosseous, and relapsed after previous surgical resection 2 years before this observation. With the description of this case, we intend to increase the familiarity of physicians with this rare disease, its diagnosis and treatment.

**Clinical Case**

We report the case of a 16-year-old male, referred to our hospital in 2012 for a suspected giant cell tumor of the flexor tendon sheath of the fourth finger of the left hand, relapsed after a marginal resection 2 years before (▶Fig. 1).



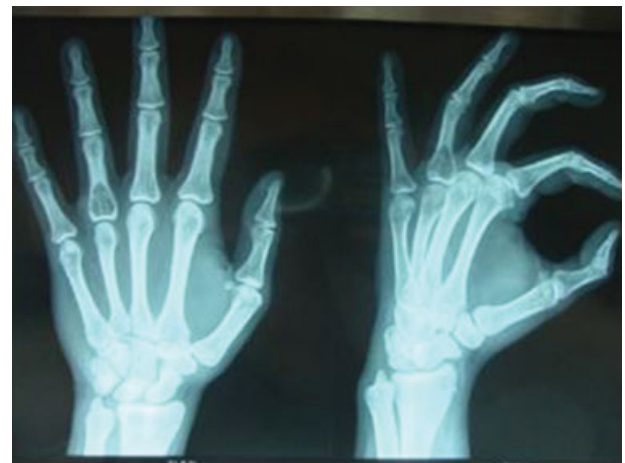**Fig. 1** Radiological control in the hospital of origin follow-up, in 2010.

Over these former two years, the patient had noted a slow, progressive recurrence of swelling with discomfort and occasional edema. The patient did not present functional limitation.

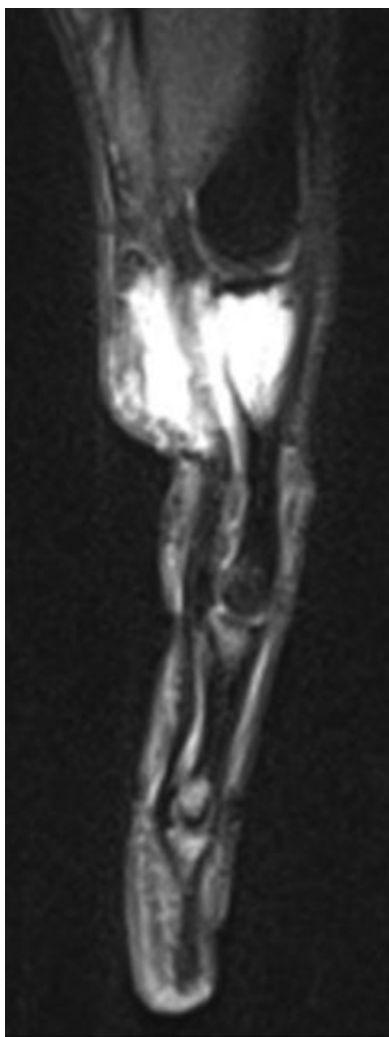A control X-ray was performed after 2 years of progressive symptomatology, and a lytic, septate, intraosseous lesion with cortical insufflation was found at the base of the proximal phalanx of the 4th finger of the left hand (▶Fig. 2).

In 2012, at our hospital, the physical examination showed swelling of the dorsal region of the proximal phalanx of the 4th finger of the left hand, without cutaneous trophic alterations or pain on local palpation. There were no apparent restrictions on finger mobility or distal neurovascular alterations.

On the magnetic resonance imaging (MRI) performed on October 31, 2012, the posterior aspect of the flexor tendons of the 4th finger presented a lobulated tumor lesion with epicenter in the bone marrow of the 4th finger proximal phalanx, T1-hypointense, hyperintense and slightly heterogeneous on T2 and proton density (PD) weighted images (▶Fig. 3). This lesion conditioned marrow insufflation of the proximal portion of the first phalanx of the 4th finger, with apparent cortical rupture and erosion, wrapping and surrounding the flexor tendons, especially in its posterior and anterointernal aspects.



**Fig. 2** Intraosseous lesion, lytic, septate, with cortical insufflation, located at the base of the proximal phalanx of the 4th finger of the left hand.

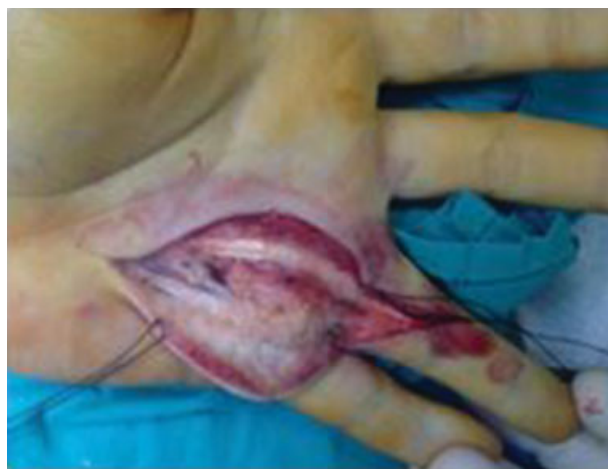

**Fig. 3** Nuclear magnetic resonance, T2, endomedullary tumor invasion extending to the soft tissue.

Intralesional biopsy of the soft tissue mass of the volar and cubital region of the 4th ray of the left hand was performed on November 8, 2012. The histological and immunohistochemical diagnosis was neurothekeoma.

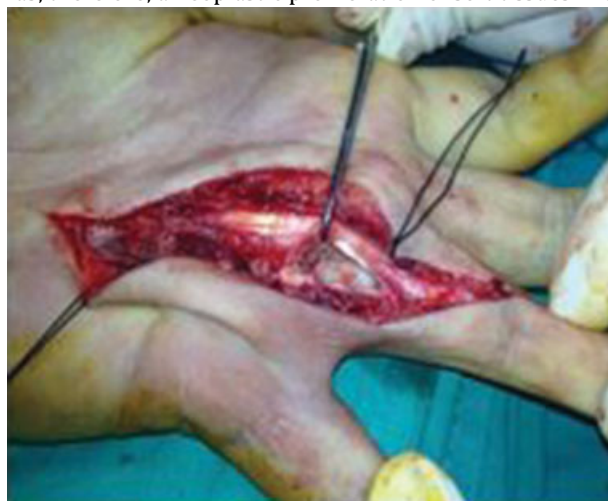On January 3, 2013, marginal resection of the tumoral mass located over the distal region of the 4th metacarpal was performed (► **Fig. 4**) and curettage of the 4th ray proximal phalanx, which presented local intraosseous invasion (► **Fig. 5**). Autologous cortico-cancellous bone graft, collected from the homolateral olecranon, was performed (► **Fig. 6**). The patient was immobilized postoperatively with brachipalmar cast, which he kept for 3 weeks until the follow-up consultation.

Macroscopic examination of biopsied fragments revealed nodular formations consisting of whitish and firm tissue. Microscopically, the nodular areas comprised cell proliferation with relatively monomorphic, oval-shaped nucleus, with thin chromatin, showing eosinophilic cytoplasm of ill-defined limits. Multifocally, glomeruloid cell aggregation was observed centered by a small blood capillary. Proliferation was negative for epithelial membrane antigen (EMA) but was strongly immunoreactive for S100 protein. (► **Fig. 7**). It



**Fig. 4** Soft tissue tumor invasion surrounding the flexor tendons.

was, therefore, a neoplastic proliferation of soft tissues with



**Fig. 5** Intraosseous tumor lesion with cortical destruction.

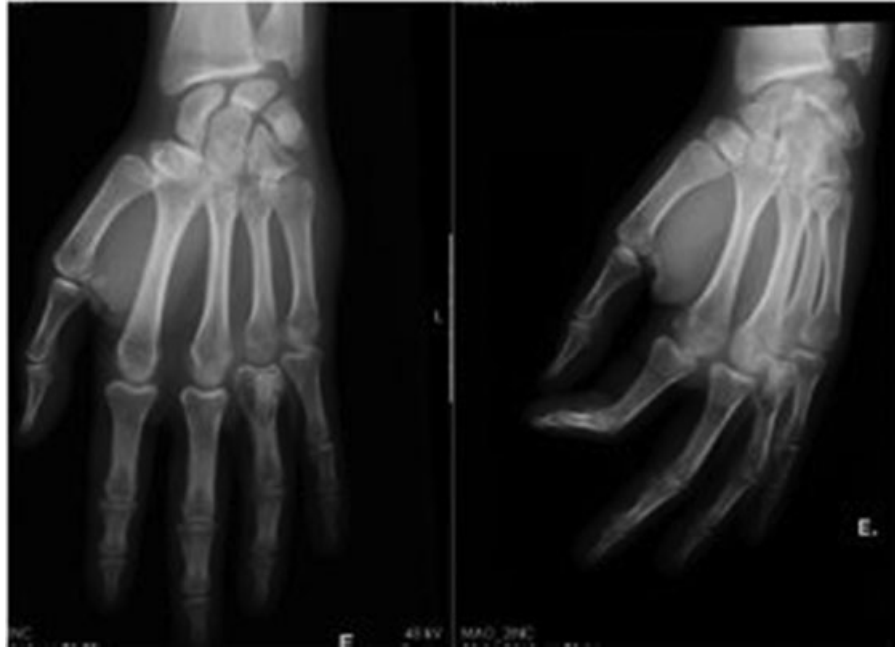Schwannian differentiation, with cellular histomorphological and structural characteristics that categorized it as a neurothekeoma.

The patient maintained a favorable postoperative clinical evolution, without pain complaints and without limitations of the fingers' mobility. At radiological level, progressive trabecular filling of the 4th finger proximal phalanx was observed (► **Fig. 8**).

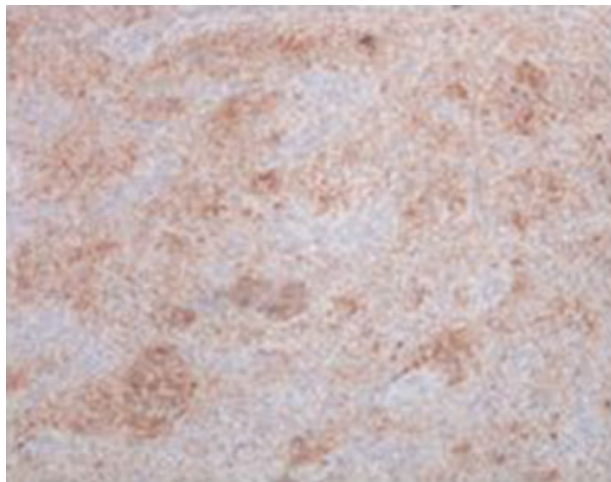At 17 months of follow-up, the patient is asymptomatic and shows no signs of relapse.

## Discussion

Soft-tissue tumors are rare in the pediatric population. First described by Harkin and Reed in 1969<sup>3</sup> as myxoma of the nerve sheath, the neurothekeoma is a benign tumor lesion with presumable origin in the nerve sheath. The term neurothekeoma was described by Gallager and Helwing in 1980 (from Greek: theke – sheath) to connote the histological appearance in nest.<sup>2</sup> Although its characteristics overlap



**Fig. 6** Postoperative X-ray with visualization of autologous cortico-cancellous bone graft.



**Fig. 7** Photomicrograph of neurothekeoma with immunohistochemical staining for protein S100 (100 ×).

with other nervous tissue tumors, such as Schwannoma or neurofibroma, it is a distinct clinicopathological entity.<sup>4</sup>

Histological variations allow classification in myxoid, cellular, and mixed neurothekeoma, depending on the amount of myxoid and cellular tissue present. They are non-capsular tumors composed of multiple cell nodules separated by thin collagen bands. Occasionally, giant multinucleated cells are present.<sup>1,4</sup>

Parenchymal origin of neurothekeoma remains presumed. By neuronal differentiation—presents myxoid areas similar to the classic myxoid neurothekeoma. By smooth muscle differentiation—myofibroblastic or epithelioid variant of dermatofibroma represented by cellular neurothekeoma.

From its first characterization, it is described that the source cell is the Schwann cell that innervates the blood vessels.<sup>1</sup>

A recent immunohistochemical marker allows the differentiation between myxoid neurothekeoma, melanocytic neurothekeoma and nervous system tumors—anti-S100A6, antibody with high sensitivity to neurothekeoma.<sup>4</sup>

Neurothekeoma, which most often has a dermal presentation, makes differential diagnosis, at pediatric age, with histiocytic tumors of fibromatous, lymphocytic, melanocytic, and neural origin.<sup>5</sup>

The indicated treatment is complete surgical resection of the lesion and seems to be the definitive treatment without causing neurological injury.<sup>6-10</sup>

Incomplete resection leads to local recurrence and invasion.<sup>5</sup> Since myxoid and cellular neurothekeomas are benign lesions, there are no records of metastases and this type of injury does not benefit from radiotherapy or adjuvant chemotherapy.<sup>5</sup> Patient follow-up are necessary to detect local recurrences in case of incomplete resections.

The differential diagnosis of neurothekeoma should include<sup>1</sup>:

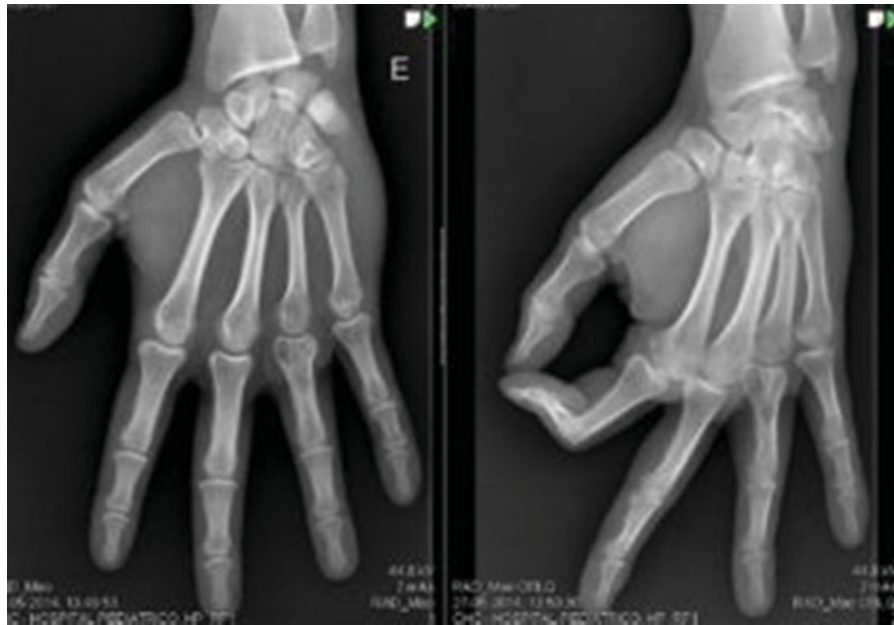Epidermoid cysts, dermatofibromas, smooth muscle tumors, fibrohistiocytic tumors, lipomas;

Melanomas, which may be difficult to distinguish histologically from cellular neurothekeoma (melanocytic tumors are positive for S100, while cellular neurothekeoma are negative for S100);

Schwannomas, similar to myxoid type neurothekeoma; meningiomas, spinal myxoid neurofibroma.

## Conclusion

This is the first described case of an expansive and destructive intraosseous neurothekeoma of the 4th ray of a hand. Complete excision of the lesion is curative.



**Fig. 8** Control after 17 months postoperatively.

**Conflicts of Interest**

The authors declare that there are no conflicts of interest.

**References**

- 1 Iacob G, Tene S, Iuga M, Simion G. A very rare, petro-clival, neurothekeoma tumor. Case Report. Romanian Neurosurg. 2015;29(03):239–246
- 2 Gallager RL, Helwig EB. Neurothekeoma—a benign cutaneous tumor of neural origin. Am J Clin Pathol 1980;74(06):759–764
- 3 Harkin JC, Reed RJ. Tumors of the peripheral nervous system. Atlas of Tumor Pathology. Washington, D. C: Armed Forces Institute of Pathology; 1969
- 4 Laskin WB, Fetsch JF, Miettinen M. The “neurothekeoma”: immunohistochemical analysis distinguishes the true nerve sheath myxoma from its mimics. Hum Pathol 2000;31(10):1230–1241
- 5 Ding YI, Zou F, Peng W, et al. A giant neurothekeoma of the left shoulder blade: A case report. Oncol Lett 2016;11(02): 1130–1134
- 6 Uygur S, Ayhan S, Kandal S, Gureli M, Uluoglu O. Giant neurothekeoma in the forearm of an infant. J Plast Reconstr Aesthet Surg 2009;62(08):e259–e262
- 7 Bhaskar AR, Kanvinde R. Neurothekeoma of the hand. J Hand Surg [Br] 1999;24(05):631–633
- 8 Blumberg AK, Kay S, Adelaar RS. Nerve sheath myxoma of digital nerve. Cancer 1989;63(06):1215–1218
- 9 Donofrio V, Passeretti U, Russo S, Boscaio A, De Rosa G. Neurothekeoma of the thumb. A case report. Tumori 1988;74(06): 751–754
- 10 Kaltman J, Best S, Kaltman S, Lopez E, Velez I. Intraosseous neurothekeoma of the mandible: a rare occurrence. Inter J of Oral Maxil Pathol. 2012;3(01):13–17