




Partial Rupture of the Distal Triceps in an Athlete: Case Report and Description of Surgical Technique*

Ruptura parcial do tríceps distal em um atleta: Relato de caso e descrição de técnica cirúrgica

Eduardo Antônio Figueiredo¹ Paulo Henrique Schmidt Lara¹  Gyoguevara Patriota¹
Ronaldo Roncetti Júnior¹ Paulo Santoro Belangero¹ Benno Ejnisman¹

¹ Orthopedics and Traumatology Department, Escola Paulista de Medicina (EPM), Universidade Federal de São Paulo (Unifesp), São Paulo, SP, Brazil

Address for correspondence Paulo Henrique Schmidt Lara, MD, Departamento de Ortopedia e Traumatologia, Escola Paulista de Medicina (EPM), Universidade Federal de São Paulo (Unifesp), São Paulo, SP, Brazil (e-mail: phslara@gmail.com).

Rev Bras Ortop 2019;54:601–604.

Abstract

Brachial triceps tendon ruptures account for less than 1% of all upper limbs tendinous ruptures. Partial ruptures are underdiagnosed, and a partial rupture may become a total lesion. Complete ruptures usually require surgical treatment; however, there is no well-defined conduct for partial ruptures. This article presents the case of a 42-year-old male jiu-jitsu athlete with partial rupture of the brachial triceps who underwent surgical treatment due to persistent loss of elbow extension strength, even after conservative treatment. The repair was performed with grafting of the long palmar muscle tendon, using a technique developed by the authors. No complications were observed, and the patient presented a satisfactory result, evidenced by the improvement in the parameters of isokinetic studies, which were performed before surgery and at 5 months postoperatively. This technique has proven to be an option for cases of partial rupture of the brachial triceps in patients with high physical demand who do not show improvement with the conservative treatment.

Keywords

- athletic injuries
- tendon injuries
- rupture

Resumo

A ruptura do tendão do tríceps braquial corresponde a menos de 1% de todas as rupturas tendíneas nos membros superiores. As rupturas parciais são subdiagnosticadas, o que pode fazer com que uma ruptura parcial se torne total. As rupturas completas geralmente requerem tratamento cirúrgico, entretanto para rupturas parciais não há uma conduta bem definida. Este artigo apresenta o caso de um atleta de jiu-jitsu, do sexo masculino, de 42 anos, com ruptura parcial do tríceps braquial submetido a tratamento cirúrgico devido à persistência de perda de força de extensão

* Work developed at Sports Traumatology Center, Orthopedics and Traumatology Department, Escola Paulista de Medicina (EPM), Universidade Federal de São Paulo (Unifesp), São Paulo, SP, Brazil. Originally Published by Elsevier Editora Ltda.



Palavras-chave

- ▶ traumatismos em atletas
- ▶ traumatismos dos tendões
- ▶ ruptura

do cotovelo, mesmo após tratamento conservador. Foi feito o reparo com enxerto do tendão do músculo palmar longo com técnica desenvolvida pelos autores. Não foram observadas complicações e o paciente apresentou resultado satisfatório, comprovado pela melhoria nos parâmetros dos estudos isocinéticos, os quais foram aferidos antes da cirurgia e com 5 meses de pós-operatório. Essa técnica demonstrou ser uma opção para casos de ruptura parcial do tríceps braquial em pacientes com alta demanda física que não apresentaram melhoria com o tratamento conservador.

Introduction

Brachial triceps tendon rupture accounts for less than 1% of all upper limbs tendinous ruptures,¹ but the recent development and practice of high energy, contact sports increased its incidence.

Partial ruptures are underdiagnosed, and a partial rupture may become a total lesion.² Complete ruptures usually require surgical treatment;³ however, there is no well-defined conduct for partial ruptures.

Case Report

A male patient, 42 years old, right-handed, swimming instructor and jiu-jitsu practitioner. The patient reports that, during a Jiu-Jitsu training session, he received a blow to the back of his left arm and that the site was painful for 7 days. After this period, he reported pain improvement, but loss of strength for elbow extension, limiting his swimming and jiu-jitsu activities. The patient was referred to our service after 3 months with no improvement under conservative treatment.

There were no changes in the clinical examination, and the muscle strength for elbow extension was similar to the contralateral side.

The radiographic examinations showed no changes. Ultrasonography demonstrated a marked distal triceps tendinopathy with fusiform thickening of its fibers for approximately eight centimeters and high grade intrasubstantial and partial ruptures at approximately eight centimeters from its attachment, particularly compromising the long head and, to a lesser degree, the lateral head.

After 3 months of supervised physical therapy in our service, the patient still presented the loss of strength for the aforementioned activities. As such, we opted for surgical treatment.

Surgical Technique

The patient underwent surgical treatment using the classical posterior approach (▶ Fig. 1). The triceps tendon was intact, but there was fibrosis in the long head and lateral head tendons about four centimeters from the triceps attachment to the olecranon; we believe that this fibrosis was formed at the partial rupture site. The grafting of the long palmar muscle tendon was removed through four small transverse incisions (▶ Fig. 2). Transosseous tunnels were created in the

olecranon with a 2.5 mm drill. Proximally, the graft was passed through the triceps tendon using Pulvertaft suture (▶ Fig. 3). The graft was passed with the elbow in a flexion. The elbow was mobilized throughout the range of motion to ensure proper tensioning.

The patient was immobilized for 14 days with an axillary-palmar plaster cast. After this period, he began rehabilitation for range of motion gain.

Biomechanical Evaluation

The patient was evaluated using an isokinetic dynamometer (CybexII+, New York, NY, USA) both preoperatively and 5 months after surgery. Flexion-extension was evaluated. The right arm was used as the control side.

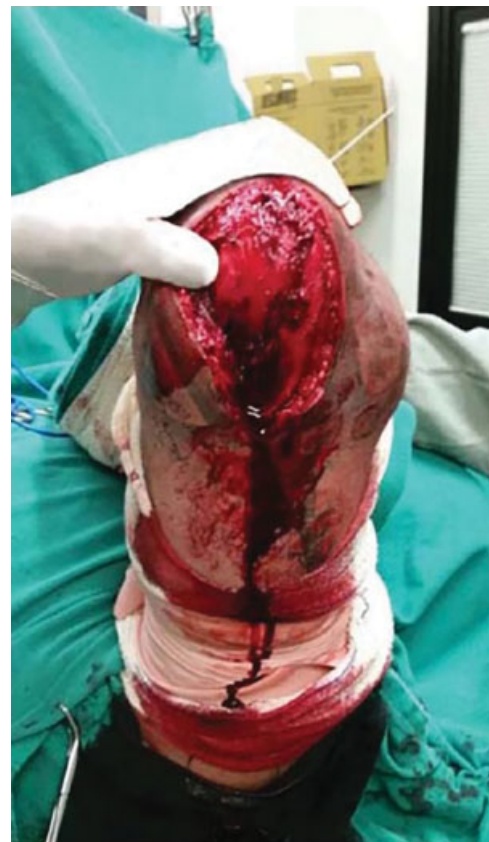

Fig. 1 Posterior surgical approach.

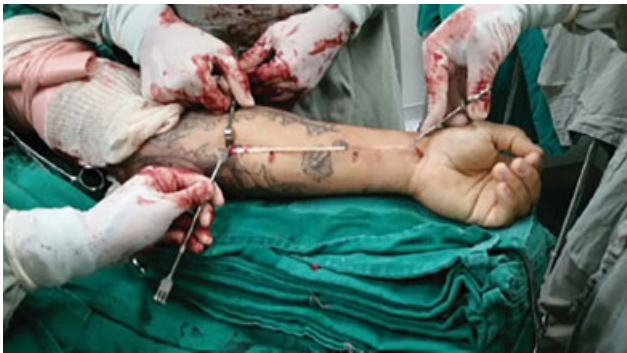

Fig. 2 Graft removal (long palmar muscle tendon).

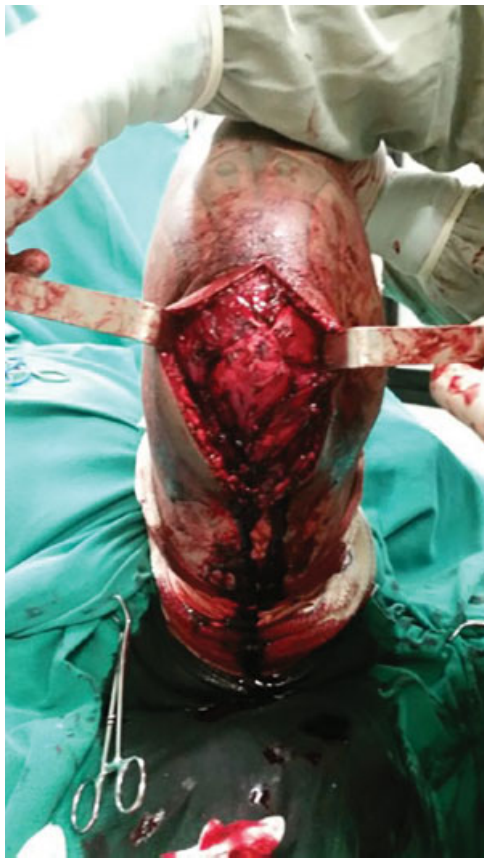

Fig. 3 Final configuration of the reinforcement made with long palmar muscle tendon graft.

Strength Evaluation

The isokinetic force peaking was performed for elbow flexion-extension at 60 and 300° per second. The patient was stabilized in a supine position, with the shoulder in 45° of abduction, and the dynamometer axis was aligned to the humeral epicondyle with the forearm in neutral rotation. The elbow range of motion was stabilized between 30 and 135° of flexion.

Biomechanical Outcome Evaluation

Five months after surgery, the patient presented improvement in the isokinetic peak force values and decrease of the extension and flexion deficits compared to the control side.

At 60°, the extension deficit compared to the control side increased from 22% before surgery to 8.9% five months after the procedure, and at 300°, the extension deficit compared to the control side increased from 24.8% before surgery to 5.2% five months after the procedure. The patient was submitted to an ultrasound examination of the arm five months postoperatively, which demonstrated distal triceps integrity, with no signs of rupture.

Discussion

The diagnosis of partial ruptures of the triceps tendon can be difficult. In some circumstances, a defect is palpable proximal to the olecranon or only the elbow extension is compromised.⁴ In the case presented here, the patient had only loss of elbow extension strength that impaired physical activities. It is worth emphasizing that if the patient had low functional demands, the treatment performed would probably not be required.

Many techniques have been described for triceps tendon reconstruction after complete or partial ruptures. The primary repair of a complete rupture with non-absorbable suture passing through holes drilled in the olecranon has been advocated whenever possible.^{5,6} The use of autografts or allografts has been advocated when primary repair is not possible.⁶

Wagner et al⁷ described a triceps tendon V-Y advancement with repair reinforcement using a plantar muscle graft that was sutured to the medial and lateral fasciae of the forearm.

Scolaro et al⁸ described two cases of chronic rupture treated using a long palmar tendon graft proximally fixated with the Pulvertaft technique.

Khiami et al⁹ described a case of partial rupture in which the medial triceps head was reinserted into the olecranon and sutured to the remaining muscle. Nikolaidou et al¹⁰ performed an 18-month postoperative isokinetic evaluation in a bodybuilder patient submitted to the reconstruction of a total triceps rupture using a synthetic graft. The patient presented superior outcomes on the operated side in all evaluated parameters.

In our case, we used reinforcement with a long palmar tendon graft even in a partial rupture because we believed that it would strengthen the reconstruction, bring adequate tension and allow an earlier rehabilitation. The use of the long palmar muscle graft is a good option, since it is located near the main surgical site and the removal technique is relatively easy; in addition, it has small thickness, allowing the drilling of small holes in the ulna to minimize the risk of complications, such as fractures.

Conflicts of Interest

The authors declare that there is no conflict of interest.

References

- 1 Anzel SH, Covey KW, Weiner AD, Lipscomb PR. Disruption of muscles and tendons; an analysis of 1,014 cases. *Surgery* 1959;45 (03):406-414

- 2 Bennett BS. Triceps tendon rupture. Case report and a method of repair. *J Bone Joint Surg Am* 1962;44(04):741–744
- 3 Mair SD, Isbell WM, Gill TJ, Schlegel TF, Hawkins RJ. Triceps tendon ruptures in professional football players. *Am J Sports Med* 2004; 32(02):431–434
- 4 Herrick RT, Herrick S. Ruptured triceps in a powerlifter presenting as cubital tunnel syndrome. A case report. *Am J Sports Med* 1987; 15(05):514–516
- 5 van Riet RP, Morrey BF, Ho E, O'Driscoll SW. Surgical treatment of distal triceps ruptures. *J Bone Joint Surg Am* 2003;85(10): 1961–1967
- 6 Morrey BF. Rupture of the triceps tendon. In: Morrey BF, editor. *The elbow and its disorders*. Philadelphia: Saunders; 2008: 536–546
- 7 Wagner JR, Cooney WP. Rupture of the triceps muscle at the musculotendinous junction: a case report. *J Hand Surg Am* 1997; 22(02):341–343
- 8 Scolaro JA, Blake MH, Huffman GR. Triceps tendon reconstruction using ipsilateral palmaris longus autograft in unrecognized chronic tears. *Orthopedics* 2013;36(01):e117–e120
- 9 Khiami F, Tavassoli S, De Ridder Baeur L, Catonné Y, Soriali E. Distal partial ruptures of triceps brachii tendon in an athlete. *Orthop Traumatol Surg Res* 2012;98(02):242–246
- 10 Nikolaidou ME, Banke IJ, Laios T, Petsogiannis K, Mourikis A. Synthetic augmented suture anchor reconstruction for a complete traumatic distal triceps tendon rupture in a male professional bodybuilder with postoperative biomechanical assessment. *Case Rep Orthop* 2014;2014:962930