


Fracture of the Humeral Shaft Associated to Elbow Dislocation and Fracture of the Distal-third of the Forearm: Case Report*

Fratura da diáfise de úmero associada a luxação de cotovelo e fratura do terço distal do antebraço: relato de caso

Jonatas Brito Alencar Neto¹ Maria Luzete Costa Cavalcante² Renackson Jordelino Garrido³
Pedro Henrique Messias da Rocha³

¹ Department of Orthopedics and Traumatology, Instituto Doutor José Frota, Fortaleza, CE, Brazil

² Department of Orthopedics, Hospital Walter Cantídio, Universidade Federal do Ceará, Fortaleza, CE, Brazil

³ Hospital Walter Cantídio, Universidade Federal do Ceará, Fortaleza, CE, Brazil

Address for correspondence Maria Luzete Costa Cavalcante, Departamento de Ortopedia e Traumatologia, Instituto Doutor José Frota, Fortaleza, CE, Brazil (e-mail: marialuzetecosta@gmail.com).

Rev Bras Ortop 2019;54:73–77.

Abstract

Humeral shaft fractures combined with elbow dislocation and fracture of the distal third of the bones of the forearm are uncommon. No description of this simultaneous association has been found in the same patient. Some studies report the association of these two lesions; however, no reports on the three ipsilateral lesions have been found at the PubMed, Lilacs and Bireme databases. The present report describes a case that occurred in a 13-year-old boy who suffered a fall from a height of approximately three meters and was admitted to a trauma hospital. Radiographs showed an ipsilateral humeral shaft fracture combined with elbow dislocation and a fracture of the distal-third of the bones of the forearm. Under general anesthesia, the injuries were readily reduced by closed manipulation, obtaining a satisfactory reduction of the injuries. Following this, an antebrachial splint and a commercial Velpeau shoulder immobilizer for the treatment of the humerus diaphyseal fracture were used. After 1 week, the patient presented non-alignment of the diaphyseal fracture of the humerus and was submitted to surgical treatment with flexible retrograde intramedullary nailing, antebrachial cast, and a commercial Velpeau shoulder immobilizer.

Keywords

- ▶ humeral fractures
- ▶ elbow
- ▶ orthopedic pins
- ▶ orthopedic wires
- ▶ internal fixation of fractures

Resumo

A fratura da diáfise do úmero associada a luxação posterolateral do cotovelo e fratura de terço distal dos ossos do antebraço é uma lesão rara, não relatada na literatura pesquisada. Alguns estudos reportam a associação de duas dessas lesões, porém não foram encontrados relatos com as três ipsilateralmente nas bases PubMed, Lilacs e

* Work developed at Instituto Doutor José Frota, Fortaleza, CE, Brazil.

 Maria Luzete Costa Cavalcante's ORCID is <https://orcid.org/0000-0002-3363-6916>.

received
July 14, 2017
accepted
September 14, 2017
published online
February 3, 2018

DOI <https://doi.org/10.1016/j.rbo.2017.09.015>.
ISSN 0102-3616.

Copyright © 2019 by Sociedade Brasileira de Ortopedia e Traumatologia. Published by Thieme Revinter Publicações Ltda, Rio de Janeiro, Brazil

License terms



Palavras-chave

- ▶ fraturas do úmero
- ▶ cotovelo
- ▶ pinos ortopédicos
- ▶ fios ortopédicos
- ▶ fixação interna de fraturas

Bireme. Os autores apresentam o caso de um paciente de 13 anos, do sexo masculino, com história de queda de aproximadamente três metros de altura. Foi atendido em um hospital terciário de referência em traumatologia com diagnóstico de fratura diafisária do úmero associada a luxação do cotovelo, lesão da placa fisária do rádio e fratura de terço distal da ulna ipsilateral esquerda. O paciente foi submetido a redução incruenta de todas as lesões sob sedação anestésica; posteriormente à redução, optou-se pelo uso de tala antebraquiopalmar e tipoia comercial tipo Velpeau como tratamento da fratura diafisária de úmero. Após uma semana, o paciente apresentou desvio da fratura diafisária do úmero, foi submetido a tratamento cirúrgico com hastes flexíveis de forma retrógrada, gesso antebraquiopalmar e tipoia comercial do tipo Velpeau.

Introduction

Humeral shaft fractures correspond to between 3 and 5% of the fractures in children < 16 years old. These lesions are more common in individuals < 3 years old or > 10 years old.¹ The shaft region is involved in < 20% of the humeral fractures in children.²

On the other hand, radial distal third fractures are common in children.³ They are significant when there is involvement of the growth plate and require caution during management to prevent a reduction in the range of motion, as well as permanent deformities.

Elbow dislocations account for 3% of all the dislocations in children. The incidence is higher in the second decade of life, mainly between 13 and 14 years old; these lesions are more common in boys than in girls, with a 2:1 ratio. The trauma mechanism often results from falls with the hand in hyper-extension and the elbow in a 30° flexion.

The simultaneous occurrence of fractures in one or two forearm bones and an ipsilateral humeral shaft fracture is called floating elbow.⁴ It represents 2% of the trauma lesions in children and normally results from high-energy traumas.⁵

However, there were no reports in the searched literature, namely the PubMed, Lilacs and Bireme databases, of the three concurrent, ipsilateral lesions (humeral shaft fracture associated with elbow dislocation and fracture of the distal third of the forearm bones) in the same patient.

Case Report

A 13-year-old boy with a history of a fall from a height of three meters was admitted at a reference trauma hospital with pain, edema, deformity, and movement limitation in the left arm. At the clinical examination, the patient was in good general conditions, eupneic, responsive, and oriented to time and space. The affected limb presented no distal radial pulse alterations. The neurological exam was unremarkable. The radiographic exam revealed the diagnosis of an oblique humeral shaft fracture with a 2 cm shortening and varus angulation associated with an ipsilateral posterior elbow dislocation, a Salter Harris I epiphyseal dislocation of the distal third of the radius, and a greenstick fracture of the distal third of the ulna (▶ Fig. 1).

The patient was submitted to closed manipulation of the elbow dislocation, of the epiphysis dislocation, and of the ulnar greenstick fracture under anesthetic sedation, with satisfactory reduction (▶ Fig. 2). An antebrachiopalmar splint associated with a commercial Velpeau shoulder immobilizer was used to treat the humeral shaft fracture with satisfactory reduction and alignment. After 1 week, due to a deviation in the humeral fracture, the patient was submitted to surgical treatment with retrograde flexible rods (Titanium Elastic Nail System; Synthes, Solothurn, Switzerland), followed by the application of an antebrachiopalmar cast and the use of a commercial Velpeau shoulder immobilizer (▶ Fig. 3).

Flexible rods were introduced with 2 cm access, one at a posterior transtriceps location and the other posterolateral, between the triceps and biceps brachii, with the proper protection of the soft parts. Two 2.5 mm-thick rods were introduced, configuring 80% of the humeral medullary canal of the patient (6.25 mm); the angulation of each rod was calculated at 30° with the apex at the fracture site.²

After the fixation with the rods, the elbow stability was evaluated by 30° and 60° joint varus and valgus stress, with unremarkable results.

The patient was followed-up at an outpatient facility at 15 days, and at 1, 2, 3, and 5 months. Anteroposterior and profile X-rays of the arm, of the elbow, and of the wrist were taken at each visit; moreover, bone consolidation and joint functionality were evaluated, as well as possible complications. The early movement for the gain of the range of motion of the elbow started at the first week postoperative, but the patient reported pain and difficulty to recover his range of motion due to the discomfort at the entrance points of the rods. The antebrachiopalmar cast was removed at 5 weeks, followed by exercises for the gain of range of motion and strengthening of the wrist.

At the 3rd month postprocedure, there was a cutaneous rash at the entrance point of the flexible rods, resulting in exposure. After treatment with serial dressings, the healing was complete. The introduction of the antegrade rod by the proximal lateral aspect of the humerus might prevent this complication.

The rods were removed 5 months after the procedure. The boy is under outpatient follow-up and motor rehabilitation. He presents loss of the last 5° of extension and flexion of the

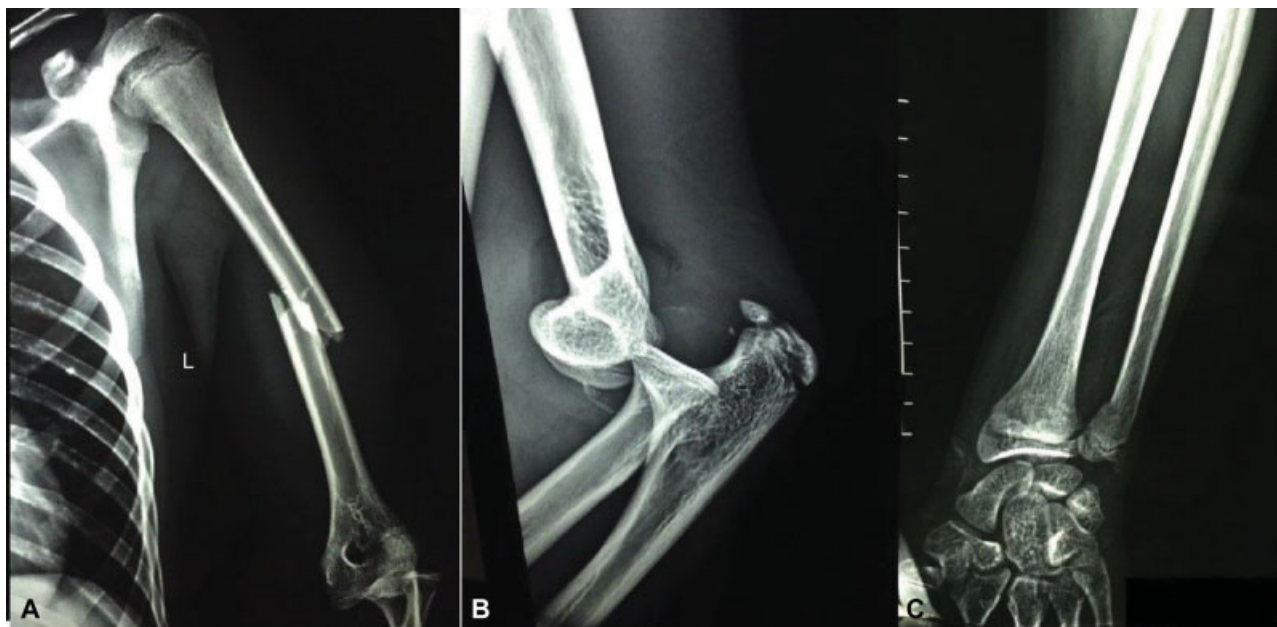


Fig. 1 Fracture of the left humeral shaft (A); Left elbow dislocation (B); Left radial epiphyseal lesion and greenstick fracture of the distal third of the left ulna (C).

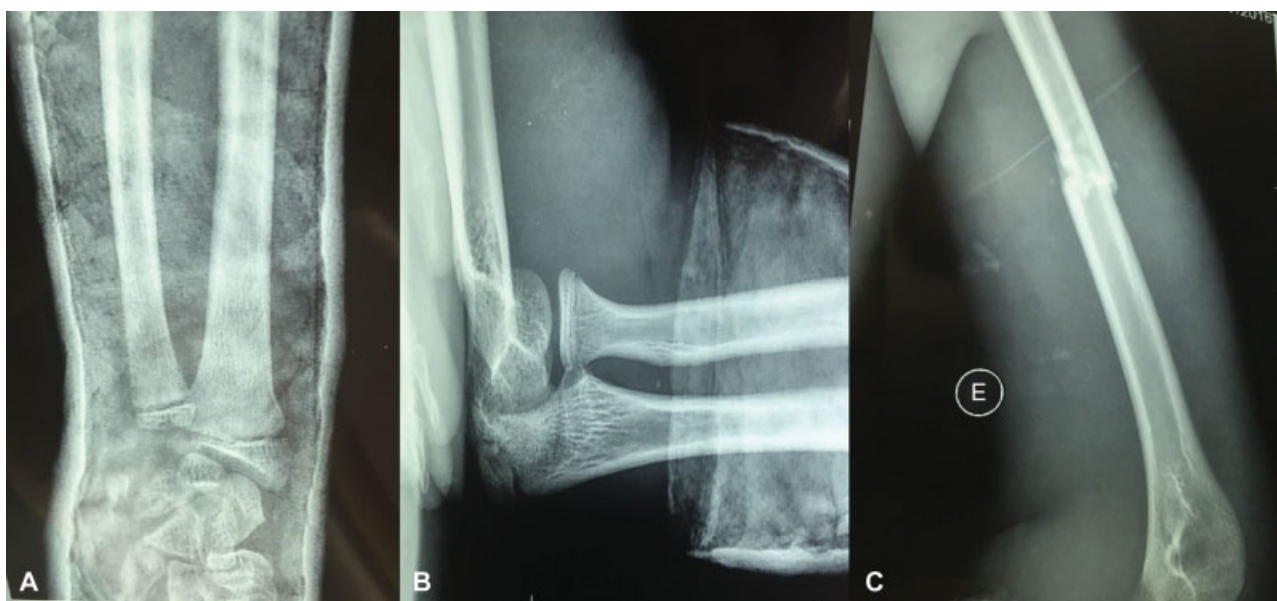


Fig. 2 Closed manipulation of the left distal radial epiphysis dislocation and the left ulnar greenstick fracture (A); Closed manipulation of the left elbow dislocation (B); Closed manipulation of the left humeral shaft fracture (C).

elbow, fully preserved pronosupination, and complete range of motion of the wrist with no pain or instability in the elbow, the wrist or the hand (→ Fig. 4).

Discussion

The incidence of elbow dislocation in children is of between 3 and 6%; humeral shaft fractures account for 5% of the total number of fractures in this group.^{1,2,6} Approximately 15% of all fractures in children involve the physes. Radial distal fractures, however, represent up to a third of all the pediatric fractures.⁷ Twenty percent of these fractures involve the

physes zone of the distal third of the radius.² Among distal radial physesal lesions, 58% are Salter Harris type II.⁸

Some studies associated two from these three lesions, often with the simultaneous occurrence of fractures in one or both forearm bones and in the humeral shaft; this lesion is called floating elbow, with an incidence of between 2 and 17%.^{5,9} No reports were found in the searched literature describing the association of these three lesions in the same patient.

The treatment of associated lesions must consider each injury to reestablish the anatomy, the joint congruity, and the range of motion of the limb. In the reported case, the closed manipulation of the elbow dislocation and the radial

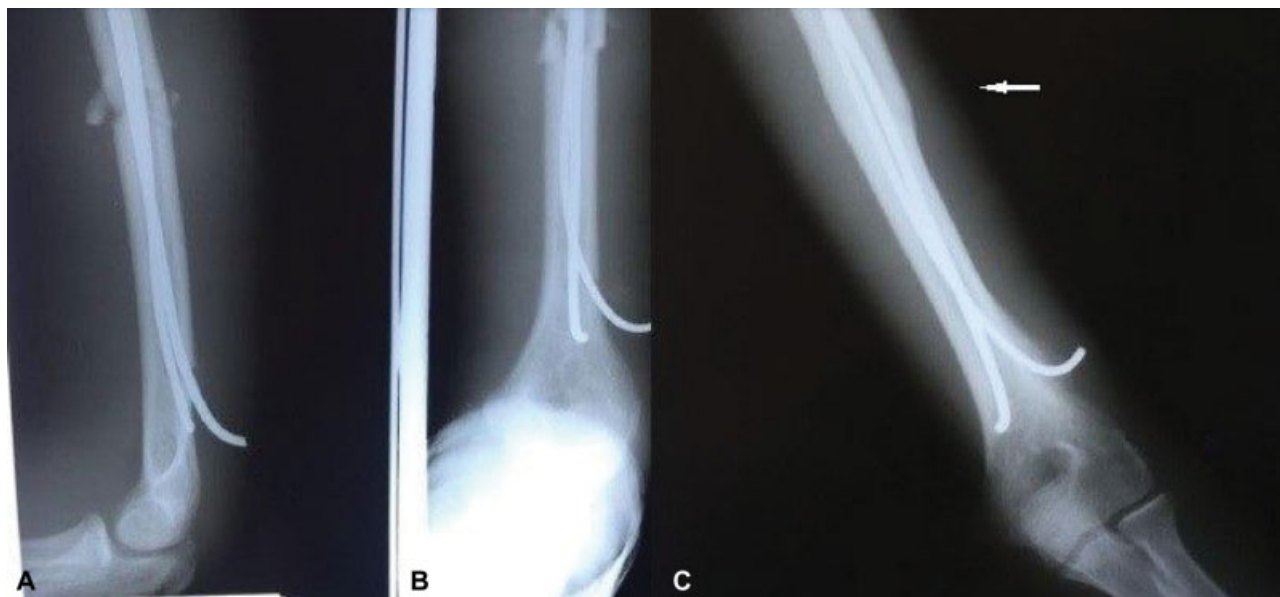


Fig. 3 Profile and anteroposterior radiographs showing the adequate fixation with flexible rods (A) and (B); fracture consolidation after 5 months (C).

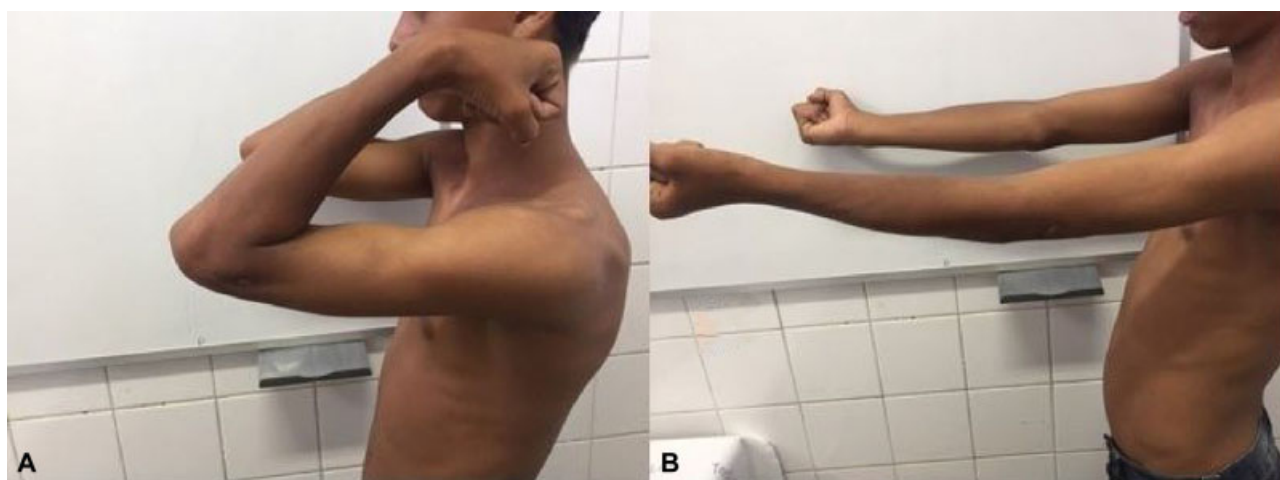

Fig. 4 Range of motion of the patient after losing 5° of flexion (A) and 5° of extension (B).

epiphysis dislocation was performed and followed by the immobilization of the distal joint with an antebrachio-palmar splint.⁸ Most distal radial fractures in children can be treated without surgery due to the higher bone remodeling ability. Radiographical and clinical criteria warranted the nonsurgical treatment of this patient, including the frontal angulation of the fracture of $< 10^\circ$ and the lack of a neurovascular lesion.²

The initial approach method for a humeral shaft fracture is supported by the literature.¹⁰ The patient fulfilled the radiographical criteria that allowed the nonsurgical treatment, including a varus deviation of $< 30^\circ$, and an internal rotation of $< 15^\circ$,² which characterize a stable fracture. However, after 1 week, the reduction was lost and, then, we opted for the surgical treatment.

The use of flexible rods is indicated for the treatment of humeral shaft fractures.² Compared with the conservative

treatment, the rods improve anatomical alignment, reduce hospitalization time, enable a faster return to daily activities, and allow an improved pain control.¹⁰

Conflicts of Interest

The authors have no conflicts of interest to declare.

References

- 1 Canavese F, Marengo L, Cravino M, Giacometti V, Pereira B, Dimeglio A, et al. Outcome of conservative versus surgical treatment of humeral shaft fracture in children and adolescents: comparison between nonoperative treatment (Desault's Bandage), external fixation and elastic stable intramedullary nailing. *J Pediatr Orthop* 2017;37(3):e156–63
- 2 Rockwood CA, Beaty JH, Kasser JR. *Rockwood and Wilkins' fractures in children*. Philadelphia: Lippincott, Williams & Wilkins; 2015

- 3 Barnes J, Webb M, v Fearon P. . Salter-Harris II forearm fracture reduction and fixation using a buttress plate. *BMJ Case Rep* 2014; 2014:bcr2013202868
- 4 Stanitski CL, Micheli LJ. Simultaneous ipsilateral fractures of the arm and forearm in children. *Clin Orthop Relat Res* 1980;(153): 218–22
- 5 Malheiros DS, Bárbara GHS, Mafalda LG, Madureira JL Jr, Braga GF, Terra DL. Floating Elbow In Children: A Descriptive Study Of 31 Cases Attended In A Reference Center For Pediatric Trauma. *Rev Bras Ortop* 2015;46(5):500–4
- 6 Subasi M, Isik M, Bulut M, Cebesoy O, Uludag A, Karakurt L. Clinical and functional outcomes and treatment options for paediatric elbow dislocations: Experiences of three trauma centres. *Injury* 2015;46(Suppl 2):S14–8
- 7 Pannu GS, Herman M. Distal radius-ulna fractures in children. *Orthop Clin North Am* 2015;46(2):235–48
- 8 Abraham A, Handoll HH, Khan T. Interventions for treating wrist fractures in children. *Cochrane Database Syst Rev* 2008;(2): CD004576
- 9 Suresh S. Management of “floating elbow” in children. *Indian J Orthop* 2007;41(4):386–9
- 10 Kelly DM. Flexible intramedullary nailing of pediatric humeral fractures: indications, techniques, and Tips. *J Pediatr Orthop* 2016;36(Suppl 1):S49–55