



Biomechanical Evaluation of Different Tibial Fixation Methods in the Reconstruction of the Anterolateral Ligament in Swine Bones*

Avaliação biomecânica de diferentes métodos de fixação tibial na reconstrução do ligamento anterolateral em ossos suínos

Rogério Nascimento Costa¹ Rubens Rosso Nadal¹ Paulo Renato Fernandes Saggin¹
Osmar Valadão Lopes Junior¹ Leandro de Freitas Spinelli² Charles Leonardo Israel²

¹Knee Surgery Service, Hospital São Vicente de Paulo, Passo Fundo, RS, Brazil

²Laboratory of Bioengineering, Biomechanics and Biomaterials, Universidade de Passo Fundo, Passo Fundo, RS, Brazil

Address for correspondence Rogério Nascimento Costa, Serviço de Cirurgia do Joelho, Hospital São Vicente de Paulo, Passo Fundo, RS, Brazil (e-mail: rogerioortopediasantacasa@hotmail.com).

Rev Bras Ortop 2019;54:183–189.

Abstract

Objective The present study aims to evaluate different methods of tibial fixation in the reconstruction of the anterolateral ligament (ALL). In addition, the present paper aims to compare the effectiveness of these methods and their mechanisms of failure in swine knees.

Methods A total of 40 freshly frozen swine limbs were divided into 4 groups of 10 specimens, according to the tibial fixation technique used. In group A, the tibial fixation of the tendon graft was made through an anchor passing the graft. In group B, the tibial fixation was performed through a metal interference screw in a single bone tunnel. In group C, the tibial fixation included an anchor associated with a tendinous suture (but not with a wire crossing the tendon). In group D, two confluent bony tunnels were drilled and combined with an interference screw in one of them.

Results The lowest mean force (70.56 N) was observed in group A, and the highest mean force (244.85 N) was observed in group B; the mean values in the other 2 groups ranged from 171.68 N (group C) to 149.43 N (group D). Considering the margin of error (5%), there was a significant difference between the groups ($p < 0.001$).

Conclusion Fixation with an interference screw in a single tunnel bone showed the highest tensile strength among the evaluated techniques.

Keywords

- ▶ anterior cruciate ligament
- ▶ articular ligaments
- ▶ knee
- ▶ orthopedic procedures

Resumo

Objetivo Avaliar a força de resistência à tração de diferentes métodos de fixação tibial na reconstrução do ligamento anterolateral (LAL). Além disso, comparar os mecanismos de falha da fixação tibial dessa reconstrução em joelhos suínos.

* Work developed at the Instituto de Ortopedia e Traumatologia of Passo Fundo, RS, Brazil



Palavras-chave

- ▶ ligamento cruzado anterior
- ▶ ligamentos articulares
- ▶ joelho
- ▶ procedimentos ortopédicos

Métodos Foram usados 40 membros recém-congelados de suínos, divididos em quatro grupos de dez espécimes, conforme as técnicas de fixação tibial usadas. No grupo A, a fixação tibial do enxerto tendíneo foi feita por meio de uma âncora e seu fio transpassou o enxerto. No grupo B, a fixação tibial foi feita por meio de parafuso de interferência metálico em túnel ósseo único. No grupo C, a fixação tibial incluiu uma âncora associada à sutura de ponto sobre o tendão (sem a presença de fio que transpassasse o tendão) e, no grupo D, foram usados dois túneis ósseos confluentes associados a um parafuso de interferência em um dos túneis.

Resultados A força média menos elevada (70,56 N) ocorreu no grupo A e a mais elevada (244,85 N), no grupo B; as médias dos outros dois grupos variaram entre 171,68N (grupo C) e 149,43 N (Grupo D). Considerando-se a margem de erro fixada (5%), foi observada diferença significativa entre os grupos ($p < 0,001$).

Conclusão A fixação com parafuso de interferência em túnel ósseo único apresentou a maior força de resistência à tração dentre as técnicas avaliadas.

Introduction

Anterior cruciate ligament (ACL) ruptures are among the most common injuries in athletes.^{1,2} However, in up to 25% of the ACL reconstructions, patients report residual rotational instability, demonstrating that achieving complete axial stability with surgically isolated ACL reconstruction remains a challenge.³ Recently, the anterolateral ligament (ALL) has been described and recognized as a potential contributor to rotational laxity.^{2,4,5} This structure was first described by Segond⁶ in 1879 as a “pearly fibrous band evident in internal rotation”^{6,7} and, for more than 130 years, there were several different ALL accounts, but few actually focused on its structure. The anatomy and biomechanical properties of the ALL were recently described,⁸⁻¹⁰ showing its importance in complete function restoration in ACL reconstruction.² Anterolateral ligament reconstruction is believed to reduce residual pivot-shift after an intra-articular reconstruction and thus improve postoperative knee kinematics.¹¹

Although several techniques describe ALL reconstruction, there is no gold standard for its fixation.

Anterior cruciate ligament reconstruction with hamstring autografts has a failure rate ranging from 4¹² to 27.3%¹³ However, these values may be underestimated, since the exact number of failed ACL reconstructions is difficult to calculate.¹⁴ Similar to ACL reconstructions, a secure clamping technique is paramount to withstand graft forces in ALL reconstructions, allowing rehabilitation protocols with weight loads for an early return to sports activity.¹⁵

The present study aims to analyze the tensile strength required for graft tibial insertion failure in four tibial fixation methods commonly used in anterolateral ligament reconstruction.

Material and Methods

The tensile force in Newtons (N) required for failure of four different fixation modes used in ALL reconstruction was

biomechanically analyzed at the laboratory. A total of 40 freshly frozen swine hind limbs were divided into 4 groups of 10 specimens according to the method of tibial fixation used. In group A, the tibial fixation of the tendon graft was performed with an anchor (Hexagon) and Ultrabraid wire (Smith & Nephew, London, UK) passing through the graft. In group B, the tibial fixation was performed with a 7 × 20 mm Traumédica metal interference screw in a single bone tunnel. In group C, the tibial fixation included an anchor (Hexagon) with tendon suture (but not transecting it) and, in group D, 2 confluent bone tunnels were associated with a 7 × 20 mm Traumédica interference screw in 1 of them. All of the anatomical parts were removed from animals with ~ 100 kg and aged between eight and nine months old. None of the samples showed signs of previous lesions or of degenerative disease, and all of them had a functionally stable knee joint. The swine knees were evenly dissected. All of the peripheral knee structures were sectioned and excised, leaving only the tibia (▶ Fig. 1). The swine foot extensor tendons¹⁶ were dissected and removed to be used as tendinous grafts, standardized with 12 cm in length and 4 mm in diameter (▶ Fig. 2). The width of each tibial plateau was measured to standardize the samples (▶ Fig. 3 and ▶ Table 1).

Surgical Technique

After removing all muscles, ligaments, and joint capsules from the swine knees, the tibias were prepared for the test. The digital extensor tendons were dissected and extracted from the parts; next, all of the samples were stored at -20°C for between 24 and 48 hours until testing. Prior to the assay, each sample was thawed overnight at 4°C. The tests were performed between 24 and 72 hours after thawing. All of the tests were performed at room temperature, and the samples were constantly kept in a container with saline solution. All of the fixation methods were performed at the site considered the anatomical tibial insertion of the ALL, between the fibular head and the Gerdy tubercle,¹⁶ as described by Viceinte et al¹⁷ and by Helito et al.^{5,18}

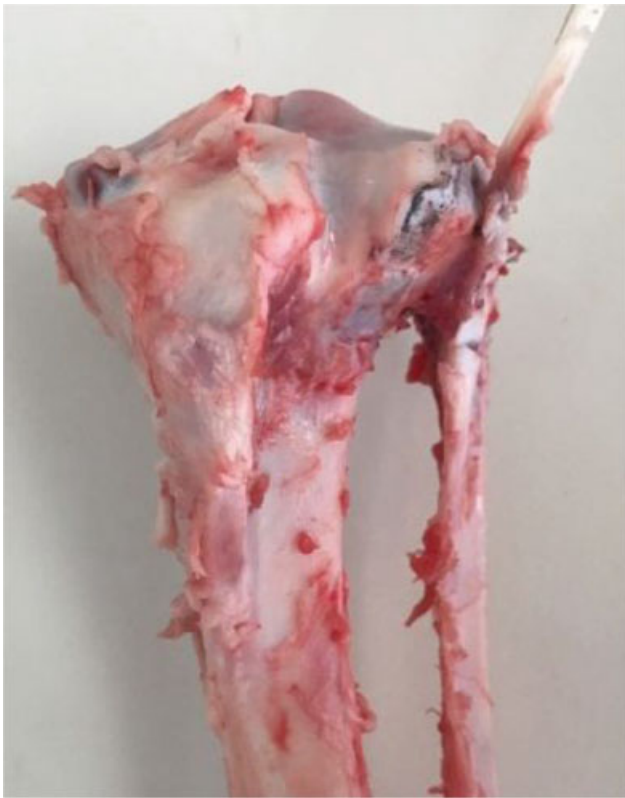

Fig. 1 Tibia preparation.

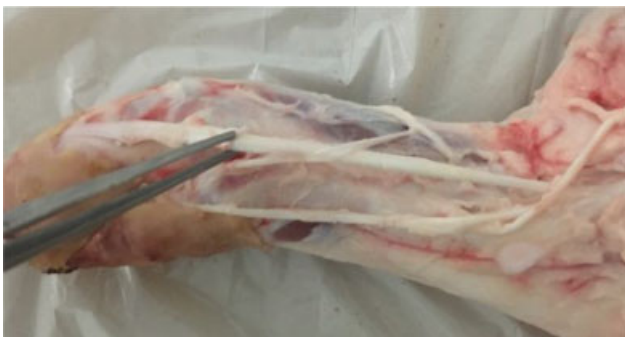

Fig. 2 Graft preparation.

Sample Preparation

After the preparation of the sample, the graft was fixed to the tibia according to the method ascribed to each group.

Group A

Tendon graft fixed with a 5 mm anchor (Hexagon) and Ultrabraid suture passing through the part, with 5 surgical knots¹⁹ (Pauchet technique) (► **Fig. 4A**).

Group B

Tendon graft fixed with a 7 × 20 mm Traumédica metal interference screw into a 6 × 30 mm bone tunnel at mid-distance between the fibular head and the Gerdy tubercle (► **Fig. 4B**).

Group C

Tendon graft fixed with a 5 mm anchor and 5 surgical knots¹⁹ with Ultrabraid wire – Pauchet technique – and

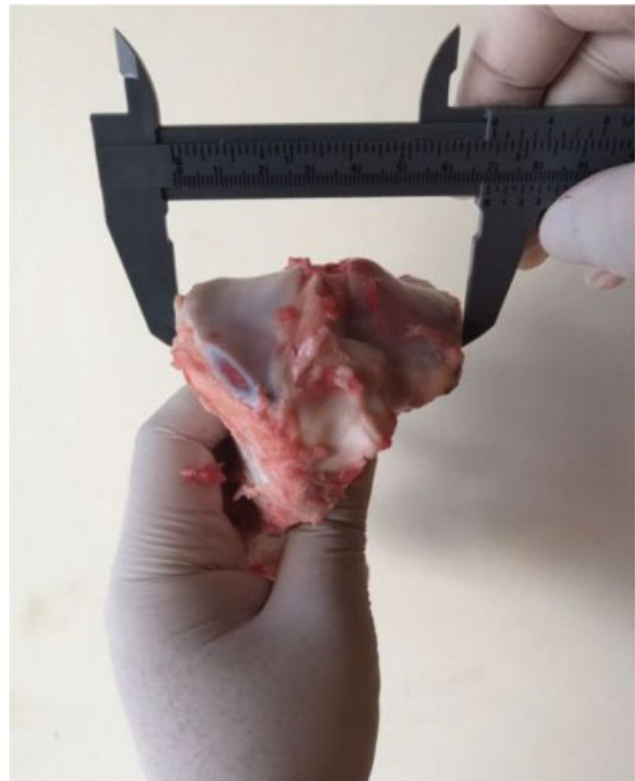

Fig. 3 Plateau width.

Table 1 Mediolateral distance from the tibial plateau (mm)

Group	Mean	Standard deviation	Coefficient of variation (%)
A	66.70	2.41	3.61
B	65.90	2.85	4.32
C	66.90	3.84	5.74
D	67.90	2.38	3.51

suture over the folded tendon (cavalier). Two “arms” were formed, 1 with 8 cm (posterior) fixed at the load cell, and another with 4 cm (anterior), in which a proximal suture was made and again fixed at the load cell, constituting the double graft described by Sonnery-Cottet et al²⁰ (► **Fig. 4C**).

Group D

Two bone tunnels were prepared with a 6 × 30 mm drill at 90° angles from each other for communication between them. The tendon was passed through the tunnels, resulting in a graft with two “arms.” The graft arm in the 8 cm posterior tunnel was fixed with a 7 × 20 mm metal interference screw, and the graft arm in the 4 cm anterior tunnel was fixed with a proximal suture and attached to the load cell, constituting the double graft described by Sonnery-Cottet et al²⁰ (► **Fig. 4D**).

Biomechanical Tests

The groups were submitted to a tensile biomechanical test with an UPM 200 Universal Tensile Testing Machine with a capacity of 200N and 20T (Schenck, Passo Fundo, RS, Brazil)

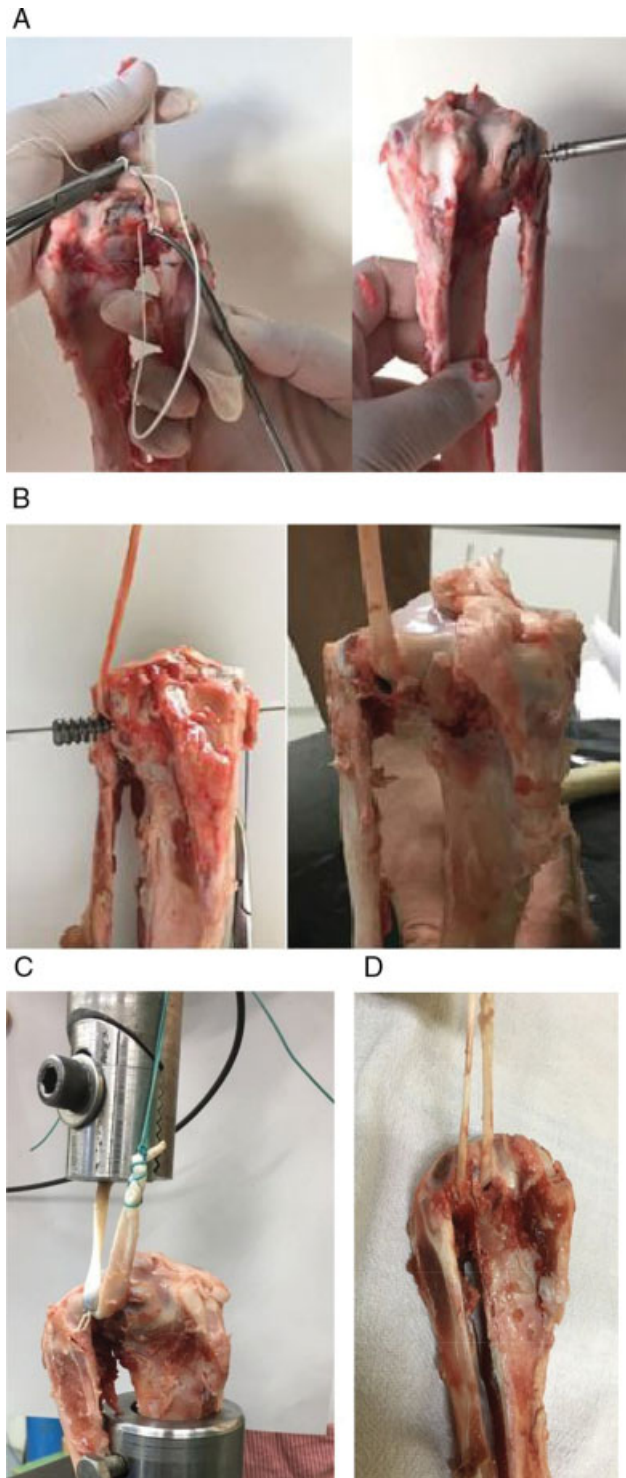


Fig. 4 A, Group A. B, Group B. C, Group C. D, Group D.

with a 20 kgf load cell (9 USB (HBM, Inc. Marlborough, MA, USA), and speed of 60 mm/minute. The strength parameters were recorded by a computer with a Spider 8 software system (HBM, Inc. Marlborough, MA, USA) complemented with a Catman Easy 3.1 data acquisition amplifier (HBM, Inc. Marlborough, MA, USA) using the acquisition routines provided by the manufacturer.

The tibias were positioned beneath the load cell attached to the machine by a tubular support secured by a bone

screw (→ **Fig. 5**). The tendon was fixed as a graft in the proximal tibial region as previously described, so that ~ 4 cm of tendon remained free and 4 cm were attached to the load cell; the tibial axis was visually aligned with the axis of the machine. During the assembly, the tubular support was fixed to the base of the machine with a bench vise, allowing only the proximal displacement of the tendon, which was attached to the moving element of the machine. The test was performed with the tibia in ~ 30° of flexion, simulating the ALL tensile angle.

The evaluated parameters were the following: maximum limit tensile strength of the different types of ligament fixation, expressed in Newtons; and failure modes. Failures were defined by a sudden drop at the graph curve (N) during testing. The test was then discontinued, and the graph was preliminarily analyzed.

The present study was approved by the Ethics Committee of our University regarding researches with animals under the number CEUA 039/2016.

Statistical Analysis

Data were expressed as mean, standard deviation (SD) and coefficient of variation (CV) for numerical variables, and as absolute frequencies for the categorical variable.

The sample size was determined from data from previous studies.^{9,21,22} The tensile strength was compared between groups with an F test (analysis of variance [ANOVA]) with multiple size comparisons. Data normality and equality of variances hypothesis were respectively determined by the



Fig. 5 Tibia position during tests.

Shapiro-Wilk and by the Levene tests, and size comparisons were used due to the rejection of equality of variances between the groups.^{22,23}

The margin of error used in the statistical test decision was 5.0%. Data was entered in an Excel (Microsoft Corporation, Redmond, WA, USA) spreadsheet, and the statistical calculations were performed with IBM SPSS Statistics for Windows, Version 23.0 (IBM Corp., Armonk, NY, USA).^{22,23}

Results

► **Table 1** shows the statistical data of the plateau width from each group, highlighting a very small variability.

The maximum CV was 5.74%, evidencing the high homogeneity of tibia size in each group.

► **Table 2** shows the average strength in each group. For the fixed margin of error (5%), there was a significant difference between the groups ($p < 0.001$), whereas multiple comparison tests (between group pairs) demonstrated significant differences, except for groups C and D.

The variability expressed by the CV was reasonably elevated in group D, being $> 50\%$, and it was deemed reduced in the remaining groups, which presented values $< 33.3\%$.

► **Table 3** presents the types of failures in each group. The most frequent were: nine cases of failure by graft rupture in group A; eight cases of tibial tunnel graft slip in group B; seven cases of second arm proximal knot loosening in group C; and six cases of tibial cortical breakage in group D.

Discussion

The models were submitted to biomechanical tests to allow the direct comparison of different techniques and fixation devices of the substitute ALL graft in swine tibias.

The fixation with interference screws in a single bone tunnel had the highest tensile strength for ALL reconstruction, being adequate to the human native ligament requirement as shown by Helito et al,²⁴ who demonstrated the ALL biomechanics resistance with a maximum strength of 204.8 N and an average stiffness of 41.9 N/mm. These results allow the selection of suitable grafts and fixation methods for possible ALL reconstructions associated with ACL reconstructions.²⁴ This suggests that the single bands of all grafts, both autologous or homologous, commonly used in the clinical

Table 2 Mean force per group

Groups	Mean	Standard deviation	Coefficient of variation (%)
A	70.56 ^a	12.49	17.70
B	244.85 ^b	34.89	14.25
C	171.68 ^c	21.56	12.56
D	149.43 ^c	85.44	57.17
p-value $p^a < 0,001^*$			

*Significant difference at 5%. ^a Per F test (Anova) with comparison per size test. Distinct subscribed letters indicate significant differences between corresponding groups.

Table 3 Failure type per group

Failure type	Group			
	A (n)	B (n)	C (n)	D (n)
Graft rupture	9	2	–	3
Knot loosening	1	–	–	–
Tibial tunnel graft slips	–	8	–	–
Second arm proximal knot loosening	–	–	7	–
Distal knot loosening	–	–	2	–
Anchor loosening	–	–	1	–
Cortical rupture	–	–	–	6
Femoral fixation loosening	–	–	–	1
Total	10	10	10	10

practice for knee ligament reconstruction, have the required biomechanical resistance features,²⁴ emphasizing the importance of “sufficient” fixation methods.

The attachment of soft tissues, such as ligaments, to bone is routinely used in orthopedic surgery and sports medicine.^{25,26} Fixation with interference screws provides a tight fit between the bone, the graft/tendon and the screw, being frequently used to attach replacement ligaments in drilled tunnels for ligament reconstruction. Suture anchors are used in surgical procedures when tissue attachment to a bone surface is required.²⁶ The ideal method should provide adequate mechanical fixation and strength equal to or greater than those occurring in rehabilitation before tendon graft integration to the bone.^{25,26}

In groups A and C, using anchors as the fixation method, the transtendinous suture was shown to weaken the graft, making it more vulnerable to lower tensile loads. This was exemplified by the mean inferiority of group A (70 N) compared with group C (149 N). However, anchors allow direct implantation (with no need for drilling, threading or predrilling) with a self-insertion tip, in addition to improving and tensioning individual sutures. Suture anchors produce tension throughout the tendon-bone interface. The size and positioning of the implant on cortical or spongy bone determines the strength of the fixation.²¹ Barber et al²⁷ concluded that some more recent suture anchors showed significant improvements in load-to-failure values when compared to braided polyester sutures. Therefore, it is observed that the suture material also influences the failure mode.²⁷

In the present study, the fixation in groups B and D was performed with interference screws. In group B, only one bone tunnel was made; in group D, two divergent tunnels were prepared and communicated to the graft passage, as reported. Group B presented a higher tensile strength compared to the other groups, whereas group D showed early failure in all of the samples, such as cortical breakage and a tensile strength discrepancy with a reasonably high CV. Therefore, we conclude that this surgical technique is not reproducible in swine bones, requiring other tests in human

bones. The failure patterns (►Table 3) resulting from the tensile strength in each group show that the failure mechanism was variable, depending on the fixation method, with one type of failure predominating in each group.

A potential bias of our study was the use of swine knees. Nurmi et al²⁸ reported that the trabecular bone density of the pig tibia was significantly higher compared with the human tibia at a peripheral computed tomography (CT) quantitative scanning.^{28,29} Despite this, swine tibias were often used in similar experimental studies (mainly for ACL reconstructions), and no significant differences were found regarding the use of interference screws for graft fixation in pigs and humans.²¹ In a previous study about interference screw graft fixation in swine and human bones, the maximum differences in tensile strength were insignificant.²⁸ Direct comparisons among human specimens are challenging due to the difficulty of controlling factors such as differences in donor age and in bone density. Therefore, we have decided to use swine bones, allowing us to control these factors.^{29–31}

Another potential bias relates to the location of the ALL, visually determined by the surgeon while building the parts. The tension was linear instead of rotational, as in humans, and slow, rather than fast, as in sprains.

In other studies, the tibial ALL fixation point was also constant and slightly posterior to midway between the Gerdy tubercle and the fibular head. This fixation may be associated with a Segond fracture, an anterolateral tibial bone avulsion found in about 9% of the patients with ACL ruptures.^{5,7,32}

The present study involved the zero-time biomechanical test in immediate postoperative conditions. Therefore, no histological comparison was possible.¹³ Lastly, neither the graft slippage measurement to reduce error, nor intra- or interobserver reliability tests were performed.

Conclusion

Fixation with an interference screw in a single bone tunnel had the highest tensile strength among the evaluated techniques. The converging tunnels in swine tibia were not reproducible, requiring additional tests in human bones for further evaluation.

Conflicts of Interest

The authors have no conflicts of interest to declare.

References

- Mall NA, Chalmers PN, Moric M, Tanaka MJ, Cole BJ, Bach BR Jr, et al. Incidence and trends of anterior cruciate ligament reconstruction in the United States. *Am J Sports Med* 2014;42(10):2363–2370
- Schon JM, Moatshe G, Brady AW, Cruz RS, Chahla J, Dornan GJ, et al. Anatomic Anterolateral Ligament Reconstruction of the Knee Leads to Overconstraint at Any Fixation Angle. *Am J Sports Med* 2016;44(10):2546–2556
- Helito CP, Bonadio MB, Gobbi RG, da Mota E Albuquerque RF, Pécora JR, Camanho GL, et al. Combined intra- and extra-articular reconstruction of the anterior cruciate ligament: the reconstruction of the knee anterolateral ligament. *Arthrosc Tech* 2015;4(03):e239–e244
- Sonnery-Cottet B, Thauat M, Freychet B, Pupim BH, Murphy CG, Claes S. Outcome of a combined anterior cruciate ligament and anterolateral ligament reconstruction technique with a minimum 2-year follow-up. *Am J Sports Med* 2015;43(07):1598–1605
- Helito CP, Demange MK, Bonadio MB, Tirico LE, Gobbi RG, Pécora JR, et al. Anatomy and histology of the knee anterolateral ligament. *Orthop J Sports Med* 2013;1(07):2325967113513546
- Segond P. *Recherches cliniques et expérimentales sur les épéanchementssanguins du genou par entorse*. Paris: Aux Bureaux du Progres Medical; 1879
- Claes S, Vereecke E, Maes M, Victor J, Verdonk P, Bellemans J. Anatomy of the anterolateral ligament of the knee. *J Anat* 2013;223(04):321–328
- Kennedy MI, Claes S, Fuso FA, Williams BT, Goldsmith MT, Turnbull TL, et al. The anterolateral ligament: an anatomic, radiographic, and biomechanical analysis. *Am J Sports Med* 2015;43(07):1606–1615
- Parsons EM, Gee AO, Spiekerman C, Cavanagh PR. The biomechanical function of the anterolateral ligament of the knee. *Am J Sports Med* 2015;43(03):669–674
- Spencer L, Burkhart TA, Tran MN, Rezensoff AJ, Deo S, Catherine S, et al. Biomechanical analysis of simulated clinical testing and reconstruction of the anterolateral ligament of the knee. *Am J Sports Med* 2015;43(09):2189–2197
- Dodds AL, Gupte CM, Neyret P, Williams AM, Amis AA. Extra-articular techniques in anterior cruciate ligament reconstruction: a literature review. *J Bone Joint Surg Br* 2011;93(11):1440–1448
- Maletis GB, Cameron SL, Tengan JJ, Burchette RJ. A prospective randomized study of anterior cruciate ligament reconstruction: a comparison of patellar tendon and quadruple-strand semitendinosus/gracilis tendons fixed with bioabsorbable interference screws. *Am J Sports Med* 2007;35(03):384–394
- Beynonn BD, Johnson RJ, Fleming BC, Kannus P, Kaplan M, Samani J, et al. Anterior cruciate ligament replacement: comparison of bone-patellar tendon-bone grafts with two-strand hamstring grafts. A prospective, randomized study. *J Bone Joint Surg Am* 200284-A(09):1503–1513
- Kamath GV, Redfern JC, Greis PE, Burks RT. Revision anterior cruciate ligament reconstruction. *Am J Sports Med* 2011;39(01):199–217
- Harvey A, Thomas NP, Amis AA. Fixation of the graft in reconstruction of the anterior cruciate ligament. *J Bone Joint Surg Br* 2005;87(05):593–603
- Getty R. *Sisson/Grossman. Anatomia dos animais domésticos*. 5a ed. Rio de Janeiro: Interamericana; 1981
- Vincent JP, Magnussen RA, Gezmez F, Uguen A, Jacobi M, Weppe F, et al. The anterolateral ligament of the human knee: an anatomic and histologic study. *Knee Surg Sports Traumatol Arthrosc* 2012;20(01):147–152
- Helito CP, Miyahara HS, Bonadio MB, Tirico EL, Gobbi RG, Demange MK, et al. Anatomical study of the anterolateral ligament of the knee. *Rev Bras Ortop* 2013;48(04):368–373
- Cirino LMI. *Manual de técnica cirúrgica para a graduação*. São Paulo: Sarvier; 2006
- Sonnery-Cottet B, Dagggett M, Helito CP, Fayard JM, Thauat M. Combined anterior cruciate ligament and anterolateral ligament reconstruction. *Arthrosc Tech* 2016;5(06):e1253–e1259
- Yang DL, Cheon SH, Oh CW, Kyung HS. A comparison of the fixation strengths provided by different intraosseous tendon lengths during anterior cruciate ligament reconstruction: a biomechanical study in a porcine tibial model. *Clin Orthop Surg* 2014;6(02):173–179
- Altman DG. *Practical statistics for medical research*. London: Chapman & Hall Publishers; 1991
- Conover WJ. *Practical nonparametric statistics*. New York: John Wiley & Sons; 1980

- 24 Helito CP, Bonadio MB, Rozas JS, Wey JM, Pereira CA, Cardoso TP, et al. Biomechanical study of strength and stiffness of the knee anterolateral ligament. *BMC Musculoskelet Disord* 2016;17:193
- 25 Cole BJ, Sayegh ET, Yanke AB, Chalmers PN, Frank RM. Fixation of soft tissue to bone: techniques and fundamentals. *J Am Acad Orthop Surg* 2016;24(02):83–95
- 26 Suchenski M, McCarthy MB, Chowanec D, Hansen D, McKinnon W, Apostolakis J, et al. Material properties and composition of soft-tissue fixation. *Arthroscopy* 2010;26(06):821–831
- 27 Barber FA, Herbert MA, Coons DA, Boothby MH. Sutures and suture anchors-update 2006. *Arthroscopy* 2006;22;10. 1063.e1-1069.e1
- 28 Nurmi JT, Sievänen H, Kannus P, Järvinen M, Järvinen TL. Porcine tibia is a poor substitute for human cadaver tibia for evaluating interference screw fixation. *Am J Sports Med* 2004;32(03):765–771
- 29 Kim MK, Na SI, Lee JM, Park JY. Comparison of bioabsorbable suture anchor fixation on the tibial side for anterior cruciate ligament reconstruction using free soft tissue graft: experimental laboratory study on porcine bone. *Yonsei Med J* 2014;55(03):760–765
- 30 Scheffler SU, Südkamp NP, Göckenjan A, Hoffmann RF, Weiler A. Biomechanical comparison of hamstring and patellar tendon graft anterior cruciate ligament reconstruction techniques: The impact of fixation level and fixation method under cyclic loading. *Arthroscopy* 2002;18(03):304–315
- 31 Suggs J, Wang C, Li G. The effect of graft stiffness on knee joint biomechanics after ACL reconstruction—a 3D computational simulation. *Clin Biomech (Bristol, Avon)* 2003;18(01):35–43
- 32 Hess T, Rupp S, Hopf T, Gleitz M, Liebler J. Lateral tibial avulsion fractures and disruptions to the anterior cruciate ligament. A clinical study of their incidence and correlation. *Clin Orthop Relat Res* 1994;(303):193–197