

# Tenotomy of the Gluteus Maximus in Total Hip Arthroplasty with Prevention of Sciatic Nerve Injury

## *Tenotomia do glúteo máximo em artroplastia total do quadril como prevenção de lesão do nervo ciático*

Leonardo Morais Paiva<sup>1,2</sup> Karina Maria Alécio de Oliveira<sup>1,2</sup> Diogo Ranier de Macedo Souto<sup>1,2</sup>  
Sílvio Leite de Macedo Neto<sup>1,2</sup> Nicolay Jorge Bonvine Kircov<sup>1,2</sup> Anderson Freitas<sup>1,2</sup>

<sup>1</sup>Hip Service, Hospital Ortopédico e Medicina Especializada (HOME), Brasília, DF, Brazil

<sup>2</sup>Hospital de Base do Distrito Federal, Brasília, DF, Brazil

Address for correspondence Leonardo Morais Paiva, Serviço de Quadril, Hospital Ortopédico e Medicina Especializada (HOME), Brasília, DF, Brazil (e-mail: leopmorais@yahoo.com.br).

Rev Bras Ortop 2019;54:206–209.

### Abstract

#### Keywords

- ▶ sciatic nerve/injuries
- ▶ hip arthroplasty
- ▶ tenotomy/methods

#### Resumo

#### Palavras-chave

- ▶ nervo ciático/lesões
- ▶ artroplastia de quadril
- ▶ tenotomia/métodos

The authors report a single case of complex primary hip total arthroplasty in a 34-year-old female patient with a 5.5 cm lower limb dysmetria, in whom a maximum gluteus tenotomy was performed in order to prevent sciatic nerve injury. The surgery was performed under electroneurophysiological monitoring of the fibular and tibial branches of the sciatic nerve, collecting pretenotomy, posttenotomy, and postarthroplasty reduction data. The findings demonstrate that the maximum gluteus tenotomy improved the motor response of the fibular component of the sciatic nerve.

Os autores relatam um único caso de artroplastia total de quadril primária complexa em uma paciente do sexo feminino de 34 anos, com dismetria de membros inferiores de 5,5 cm, na qual foi feita tenotomia do glúteo máximo a fim de prevenir lesão do nervo ciático. Tal cirurgia foi feita sob monitoração eletroneurofisiológica dos ramos fibular e tibial do nervo ciático. Foram coletados dados pré-tenotomia, pós-tenotomia e pós-redução artroplástica. Os achados demonstram que a tenotomia do glúteo máximo melhorou a reposta motora do componente fibular do nervo ciático.

### Introduction

Total hip arthroplasty (THA) in patients with lower limb shortening is a challenging and technically demanding procedure. The prevalence of nerve damage after THA ranges from 0.3 to 3.7%.<sup>1</sup> This injury is related to several causes, such as excessive nerve stretching, mechanical compression or traction due to retraction at surgical approach, and flexural hip contracture.<sup>2</sup> Sciatic nerve palsy related to THA is one of the most common complications of transoperative neuropathy.<sup>2,3</sup>

Its main causes include operated limb lengthening when dysmetria exceeds 4 cm. Studies defining risk factors for sciatic injury in arthroplasty patients show that a shortening up to 4 cm is an important, isolated factor.<sup>3</sup>

Due to the risk of nerve damage in shortened limbs, neurophysiological monitoring by motor evoked potential, sensory evoked potential, and spontaneous electromyography is essential for intraoperative control and prevention of neurological injury.<sup>4</sup> Real-time nerve monitoring during surgical procedure has been advocated at acetabular

received  
May 15, 2017  
accepted  
July 13, 2017

DOI <https://doi.org/10.1016/j.rbo.2017.07.001>  
ISSN 0102-3616.

Copyright © 2019 by Sociedade Brasileira de Ortopedia e Traumatologia. Published by Thieme Revinter Publicações Ltda, Rio de Janeiro, Brazil

License terms



fractures treatment and complex THAs to avoid sciatic nerve injury. Some studies have shown that the use of this method during complex hip surgeries is feasible and appropriate in addition to being effective at alerting the surgeon to the possibility of nerve damage.<sup>4,5</sup>

The anatomical correlation between the gluteus maximus tendon and the sciatic nerve is already described as an etiologic factor of deep gluteal pain. This condition is characterized by pain in the hip region or the posterior thigh, and it results from root changes due to discogenic compression or radicular compressions by non-discogenic causes, including subgluteal space compression; this fact was confirmed by recent endoscopic decompression procedures of the sciatic nerve with gluteus maximus tenotomy.<sup>5</sup>

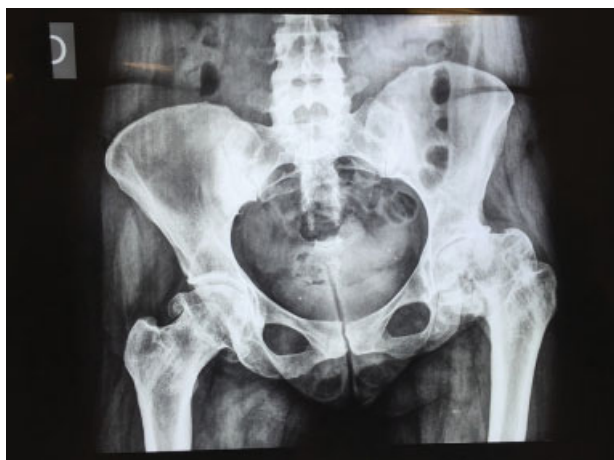As such, the description of the intraoperative electrophysiological pattern of the sciatic nerve in a complex coxarthrosis case with more than 4 cm dysmetria and treated with THA associated with maximal gluteus tenotomy may direct future scientific products with a higher level of evidence to provide therapeutic guidelines and avoid neurological damage during the procedure, since the electrographic improvement of the motor evoked potential of the fibular branch was noted.

## Case report

A hip radiography of a 34-year-old female patient diagnosed with bilateral coxarthrosis showed Tönnis grade IV coxarthrosis (►Fig. 1) on the left hip. In addition, the left lower limb had a 5.5 cm shortening at scanometry, and the patient presented lameness, low back pain and knee pain. The left hip was functionally impaired, with a Harris hip score (HHS) of 52 points.

The surgical treatment for left THA was scheduled, and the patient was informed about the risks related to the procedure, especially the risk of sciatic nerve injury.

The patient was submitted to a spinal anesthesia with codeine analgesia, with no motor block. In right lateral recumbency position, electroencephalographic monitoring electrodes were placed and successive evoked potential tests



**Fig. 1** Posterior-anterior hip radiography—bilateral coxarthrosis and lower left limb shortening.

—sensory, motor and electromyographic—were performed in spontaneous conditions to evaluate the functions of the fibular and tibial branches of the left sciatic nerve, using controls for biological and non-biological artifacts. The initial neurophysiological evaluation showed an anesthetic baseline with absence of denervation activity at rest, at the spontaneous electromyography in the tibialis anterior (M1), gastrocnemius (M2), fibular (M3) and short extensor digitorum (M4) muscles of the affected limb before tenotomy (►Fig. 2a). The electrophysiological pattern from the anesthetic baseline did not change after the Kocher-Langenbeck access. After dissection and visualization of the gluteus maximus tendon, tenotomy was performed at 1 cm from its insertional base, before femoral neck osteotomy, with a posttenotomy potential amplitude gain greater than 50% at the fibular and short extensor digitorum muscles compared with the anesthetic baseline (►Fig. 2b). This electro-neurophysiological pattern was sustained throughout the surgical procedure, even after arthroplasty reduction.

After the completion of the surgical procedure, the patient was asked to actively perform plantar dorsiflexion and hallux extension, and both movements were normal. The clinical evaluation of the lower limb dysmetria in the operating room was done by medial malleoli equalization after pelvic tilt correction, resulting in lower limbs equalization (►Fig. 3).

The surgical procedure lasted 93 minutes from the beginning of electrophysiological monitor placement until skin suture. No clinical alterations or technical complications in the prosthetic implantation were observed during surgery.

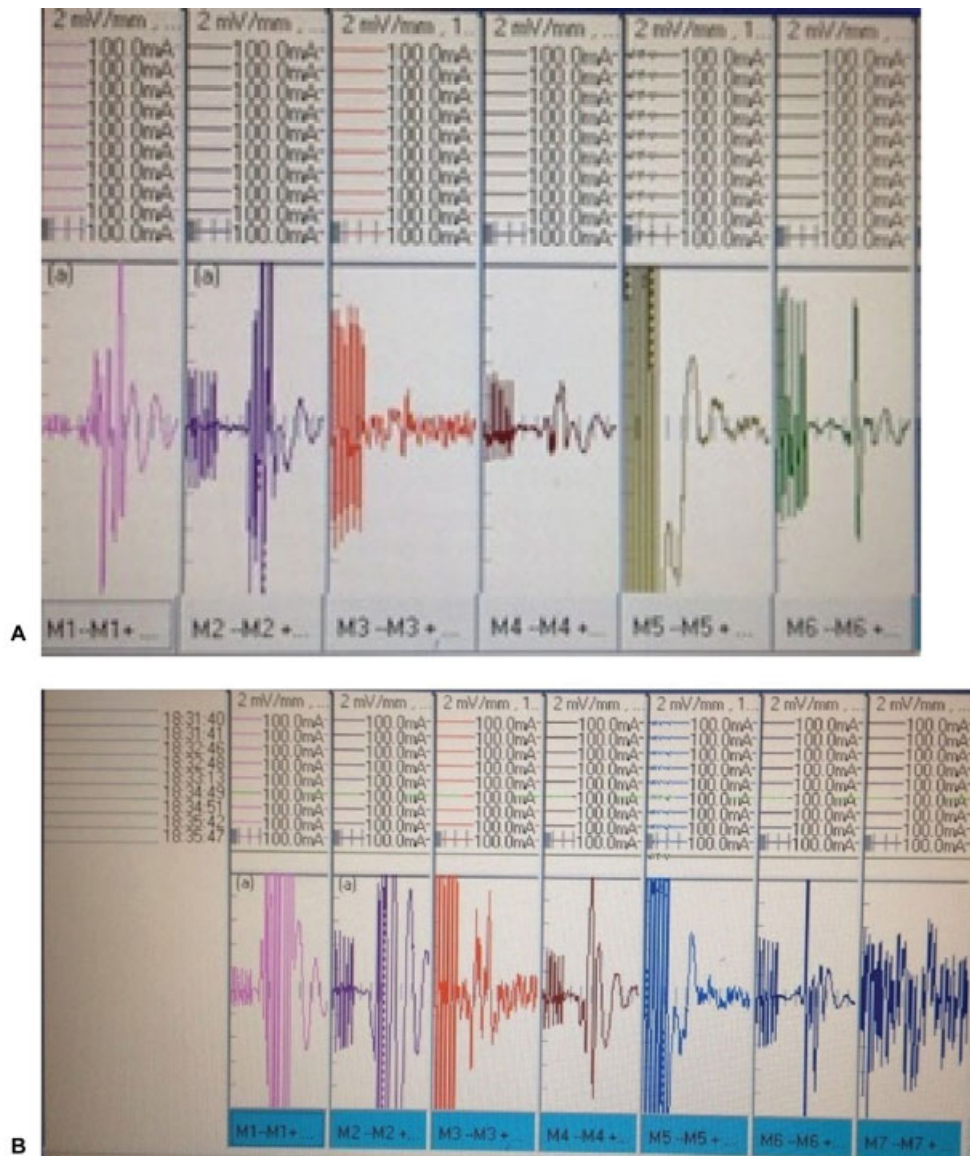
## Discussion

Lower limb dysmetria exceeding 4 cm has a high incidence of neurological damage at THA.<sup>5</sup>

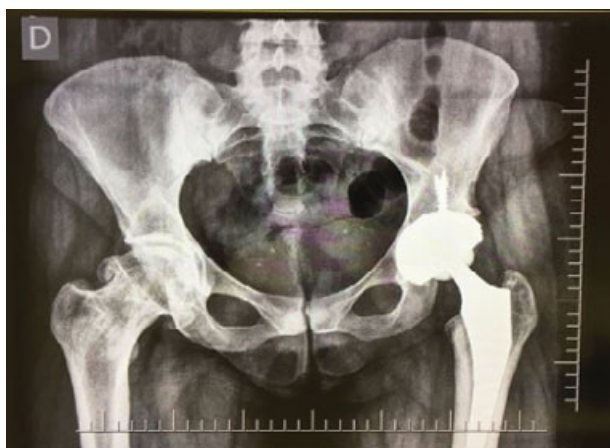In this report, the authors describe a possible protective technique to reduce such incidence.

The intraoperative electrophysiological monitoring procedure analyzes nerve and muscle functions in real time, providing preliminary information about the neuromuscular state of the patient in the immediate preoperative period; moreover, the literature already ratifies its significance during THA in dysmetric patients. This fact is confirmed by our findings and supplemented by information of improved motor evoked potentials electrophysiological patterns.

In this case, baseline changes (initial findings) were reversed after tenotomy, which is important to: support the surgeon regarding these early alterations, rendering him/her not responsible for such postoperative findings; to inform the surgeon about initial hip innervation conditions through the neuromuscular evaluation of the muscles corresponding to this innervation; to prove that the tenotomy was effective in the preservation and functional recovery of compromised structures; and to prove that the surgical technique currently applied was not harmful to the patient.



**Fig. 2** A, A, Pretenotomy: motor evoked potentials chart, in which M3 and M4 correspond to the fibular and short finger extensor muscles, respectively. The wave amplitude in M1, M2 and M3 is 10 mV, 2 mV and 3 mV, respectively (request M1 and M4 wave amplitude). B, Posttenotomy: electrophysiological evaluation chart of M1 to M6 with M7 presentation. M1 and M2 waves now present 7 and 9 mV, respectively.



**Fig. 3** Demonstrative photograph of residual dysmetria in postoperative malleolar evaluation.

Gluteus maximus tenotomy is described for the treatment of deep gluteal pain, which can result from non-discogenic compression (sciatic nerve compression).<sup>5</sup> The description of this procedure as a protective measure against sciatic nerve injury during THA (as presented by the authors) requires studies with greater scientific evidence. Nevertheless, the electro-neurophysiological results presented here support us to stimulate large centers in performing prospective clinical studies to ratify these results.

**Conflicts of interest**

The authors declare that there is no conflict of interest.

**References**

- 1 Higuchi Y, Hasegawa Y, Ishiguro N. Leg lengthening of more than 5 cm is a risk factor for sciatic nerve injury after total hip arthroplasty for adult hip dislocation. *Nagoya J Med Sci* 2015;77(03):455–463
- 2 Farrell CM, Springer BD, Haidukewych GJ, Morrey BF. Motor nerve palsy following primary total hip arthroplasty. *J Bone Joint Surg Am* 2005;87(12):2619–2625
- 3 Sutter M, Hersche O, Leunig M, Gugli T, Dvorak J, Eggspuehler A. Use of multimodal intra-operative monitoring in averting nerve injury during complex hip surgery. *J Bone Joint Surg Br* 2012;94(02):179–184
- 4 Pring ME, Trousdale RT, Cabanela ME, Harper CM. Intraoperative electromyographic monitoring during periacetabular osteotomy. *Clin Orthop Relat Res* 2002;(400):158–164
- 5 Martin HD, Reddy M, Gómez-Hoyos J. Deep gluteal syndrome. *J Hip Preserv Surg* 2015;2(02):99–107