



Journal of Coloproctology

www.jcol.org.br



Historical Article

Albucasis: pioneer of the modern anorectal surgery

ARTICLE INFO

Keywords:

Albucasis
Al-Zahrawi
Al-Tasrif
Anorectal surgery
Rectal fistula
Hemorrhoids

ABSTRACT

Albucasis is one of the world's pioneers in surgery. In his book, "Al-Tasrif", he described the surgical procedures and tools, as well as post-operative care in detail. He introduced colorectal surgeries in detail and used topical substances to accelerate recovery. Albucasis considered different approaches for anorectal surgeries and used them according to the complexity of the cases. Many of these methods were first invented by him and the effect of his ideas on modern surgical methods is evident. In this article, we discuss anorectal diseases treated by Albucasis using surgical procedures.

Albucasis: pioneiro da moderna cirurgia anorretal

RESUMO

Albucasis foi um dos pioneiros do mundo todo em cirurgia. Em seu livro "Al-Tasrif", ele descreveu os procedimentos e ferramentas cirúrgicas, bem como os cuidados pós-operatórios em detalhes. Ele incluiu cirurgias colorretais em detalhes e também utilizou substâncias tópicas para acelerar a recuperação. Albucasis considerou diferentes abordagens para cirurgias anorretais e as utilizou de acordo com a complexidade dos casos. Muitos desses métodos foram inventados por ele e o efeito de suas ideias nos métodos cirúrgicos modernos é evidente. Neste artigo, discutimos doenças anorretais tratadas por Albucasis utilizando procedimentos cirúrgicos.

Palavras-chave:

Albucasis
Al-Zahrawi
Al-Tasrif
Cirurgia anorretal
Fístula retal
Hemorroidas

Introduction

The Islamic Golden Age refers to a period of scientific flourishing in the history of Islam dated from the 8th century to the 14th century. During this era, Muslims pioneered in different scientific fields, including medicine, and for the first time, surgery was considered as a distinct part of medicine and mentioned as "hand work or iron work".¹ Before this period, surgery was underestimated compared with taking medication and surgeons were considered inferior to physicians. Most of the credits due to progress in surgery in this period goes to Abul Qasim Khalaf ibn al-Abbas al-Zahrawi (Albucasis) known as "The father of surgery" (Fig. 1).^{2,3}

Albucasis (936–1013 CE) was born in Madina Azahara, which is located on the western outskirts of Córdoba, Andalusia (Spain). He spent most of his life in Madina Azahara. Around 1000CE, he wrote "Al-Tasrif or The Method

of Medicine", a thirty-volume medical encyclopedia in Arabic, which was a result of several years of experience in medicine. In addition to sections on medicine and surgery, there were sections on pharmacology, weights, and measures, therapeutics, dietetics, psychotherapy, midwifery, and medical chemistry.^{4,5}

Albucasis' treatise on surgery was a complete narrative of all perspectives of surgery presented in his day, which included discussions of dentistry, obstetrics and gynecology, ear, nose and throat surgery, general surgery, head and neck surgeries, urology, dermatological surgeries, ophthalmology, and traumatology. Also, most of the contents of the 30th volume of Al-Tasrif were influenced by his experiences. The Greek authorities can be considered as the basis for his works, of whom Paulus of Aegina (ca. 625–690) was the most impressive. As Albucasis states: "Whatever I know, I owe solely to my assiduous reading of the books of the ancients, to my desire to

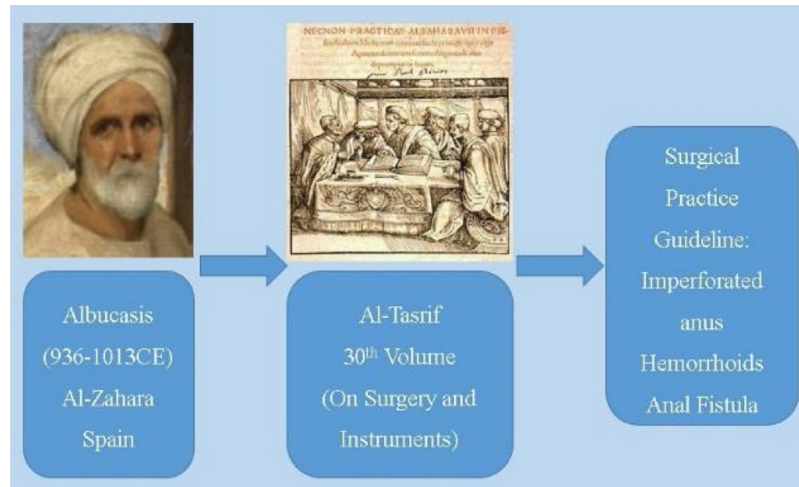


Fig. 1 – Albucasis.

understand them and to appropriate this science; then I have added the observation and experience of my whole life”.

Undoubtedly, Galen (c.130 AD–c.210 AD) was the leader of surgery in the Greco-Roman world. However, most of the great surgeons believe that Galen’s skills and achievements as a surgeon were surpassed by those of Albucasis.^{6,7} Therefore, Albucasis’ accomplishments in surgery were great as the French surgeon, Guy de Chauliac (c1300–1368). He mentioned Albucasis’ Al-Tasrif over two hundred times in his book, “Great Surgery” (1363).⁸ Surely, Albucasis was the great master of surgery in the Islamic golden age.

Ectopic pregnancy, an emergency condition in obstetrics and gynecology, was first described by Albucasis, which was a life-threatening condition in his day. He also identified the hereditary nature of hemophilia.

From the 30th volume of Al-Tasrif: on surgery and instruments

In the 30th volume of Al-Tasrif titled “On Surgery and Instruments”, he described different surgical procedures and over 200 surgical instruments, many of which had never been mentioned in any book earlier (Fig. 2). Albucasis’ essay concerning surgery and instruments consists of 300 pages, which can be divided into the following subjects: cauterization, general surgery, and orthopedics.

Two-hundred surgical instruments described in the 30th volume of Al-Tasrif are extraordinary, of which a hook to remove nasal polyps, tonsillectomies and tracheotomies, speculum, and metallic syringe for extracting bladder calculi, ophthalmic surgery, procedures for thyroid cystectomy, and breast surgery can be mentioned. The 30th volume, as the largest treatise in Al-Tasrif, was a surgical practice guideline that covered all aspects of surgery, including venesection or bloodletting, obstetrics, wound treatment and emergency medicine, arrow extraction, and orthopedics. He also wrote the scrubbing in surgery, as well as the use of suture materials—not only the customary and

well-known catgut but also the use of silk, wool, and other substances.

As mentioned above, although Albucasis’s studies and achievements have been widely considered in most of surgical fields, few published articles are available on his studies in colorectal surgeries. Therefore, we reviewed his investigations on this topic and were fascinated about the way he operated imperforated anus, anal fistula, anal fissure, hernia, and hemorrhoids. Accordingly, in this article, we mainly aimed at reviewing his impressive procedure to treat anorectal diseases using surgery.

Imperforated anus

Many infants are born with imperforate anus, which is due to a thin layer of skin obstructed the anus. The skin should be torn using fingers or a sharp knife and should not damage any muscles. A piece of cotton, which is soaked in wine and olive oil, should be put in the anus, and the midwife should use appropriate ointments until the wound heals completely. If there is any doubt that the anus may be obstructed once again, a lead pipe should be put in it for some days, and only in cases, where the lead pipe is defecated by the child, it should be taken out. Sometimes, the anus is obstructed again because of an abscess or vesicle; therefore, it should be drained and a lead pipe should be used as mentioned above.

Hemorrhoids

There are two types of hemorrhoids: internal hemorrhoids and external hemorrhoids. Internal hemorrhoids bleed continuously and look like a cluster of grapes. External hemorrhoids have the same color as the surrounding skin and are wet most of the time. Also, they may bleed or secrete yellow discharges. Internal hemorrhoids can be treated as follows:

The patient should sit in a squatting defecation position; therefore, the inner parts of anus prolapses, then the piles must be grabbed immediately with a hook or fingers’ nails and they should be cut from the very proximal end using proper tools. Then, some spicy powders should be applied to the




Fig. 2 – Surgical instruments devised or utilized by Albucasis: 30th volume of Al-Tasrif.

wound or it should be cauterized, followed by using proper medicines and lotions until the wound heals completely. If hemorrhoids did not prolapse, then burning enema should be used to help the patient for prolapse hemorrhoids.

External hemorrhoids are easier to cure. They must be grabbed with your fingernails or a hook and be cut. Then, as mentioned above, they must be cured with appropriate medications until the wound fully heals. If the patient does not want to cut the piles with a knife, then it can be proceed using two folded strings and a needle: the needle should be inserted and strongly be attached inside the base of the pile and then, the needle should be taken out and string must be wrapped around it and tied tightly, then the procedure should be repeated for all the piles, but one pile that is left untouched can bleed out. Next, a piece of tissue should be soaked in

rose oil or wax, and the patient must be asked to cover the hemorrhoids with it till they fall off. Afterward, appropriate medications and lotions should be used until the wound completely heals.

Anal fissure

It is caused mostly due to dry humor and constipation. Chronic fissures cannot be solely cured with medicine. Therefore, they must be scraped with your fingernails or using a scalpel until they become wet, and the outer skin, which inhibits the wound from healing cannot be seen anymore. Then, proper medications should be used. If the wound does not heal, it should be scraped more times.

Anal fistulas

Fistulas are mostly due to a node or solidity located in buttocks. If these nodes become chronic, a white watery substance or clear pus will drain out. Sometimes these fistulas drain into intestine or rectum and perforate them. Also, defecating gas or feces may exit from the dermal site of the fistula or even worms can exit from it.

Some fistulas connect rectum to the bladder, sexual ducts, hip joint, or coccyx. The fistula that has perforated the anus can be diagnosed as follows: the index finger is inserted inside the anus and a thin copper or iron rod is inserted inside the initiating fistula. If the fistula is deviating, a lead rod or a hoarse hair must be used.

Therefore, when it is inserted, if the other end of the rod is palpable, then the fistula perforates the anus and vice versa. If it perforates the bladder, urine will come out. Also, this kind of fistula cannot be cured using medications and lotions. If it is connected to hip joint or coccyx when a rod is inserted, the patient feels pain in the site. Besides, there is continuous pus excretion. Fistulas that are perforated are almost impossible to treat; however, non-chronic and imperforated fistulas can be treated using the following procedure: the patient must lie on his back while his thighs touch his stomach and his feet point to the ceiling. Then, a rod must be inserted inside the fistula as mentioned before. If the fistula is perforated, it is almost impossible to treat. However, it has reported rarely curable. A hot metal rod must be inserted inside the fistula until it touches the other end and the procedure must be repeated two or three times until no excess burnt flesh left, then a wick, which is soaked in oil, must be used to bring out all of the burnt flesh followed by using proper medications.

To treat imperforated fistulas, the fistula should be cut to the point that the rod falls out, followed by cutting the feather-like flesh. Then, proper medications must be used until the wound completely heals. If bleeding disrupts the procedure, the best measure is cauterizing the site or using burning medicines; however, cauterizing is the better choice since it burns the excessive flesh, as well. Next, a wick soaked in oil mixed with sulfur must be used; to bring out all the burnt flesh and pus. Afterward, astringents and wound healing medications have found to be useful. If the wounds heal completely, they will not appear again. When the fistula reaches the depth of buttocks and is far from the skin, then inside the anus should be explored with fingers. If you feel the rod over a thin

layer of flesh or membrane-like tissue, then it is almost perforated. Performing surgery, in this case, is only due to greed or hope. There are three methods to perform this surgery; 1) Cauterizing the fistula; 2) Cutting the fistula using wicks. Caution must be taken to prevent damage to the anal sphincter, which may result in stool incontinence. Then, it must be cured as mentioned before; 3) Cutting the fistula to the end and followed by puncturing the anal end to perforate it into the anus. Next, all the flesh must be brought out and the wound should be cured. Also, remember to keep the perforation to anus open; therefore, the patient would feel better.

Sometimes, the rod reaches a site, where skin and anal ring meet. In these cases, a needle-shaped rod can be used, which is perforated on both ends.

A rope made of 5 strings must be inserted inside the pipe, and then it must be inserted inside the fistula. If the other end is open, the rope should be grabbed from inside the anus and the two ends of the rope must be tied together and stay in place for one or two days, and then the rope should be pulled in a way that all the excess flesh falls off. Afterward, proper medicines must be used. If the fistula is not perforated, then puncture it unless it is too deep in the anus.

Discussion

Albucasis is known as the father of modern surgery and the chief of all surgeons.² In Volume 30 of his book, "Al-Tasrif", he describes surgical methods and tools, such as knives, hooks, scalpels, forceps, and cautery devices.³ Al-Tasrif has been translated into several languages and many of his methods have been used unchanged for centuries. Colorectal surgery is one of the topics that have been discussed in detail. Imperforate anus, fistula, hemorrhoid, fissure, and hernia have been previously considered.

Albucasis described the imperforate anus as a congenital disease that is treated with creating orifice in the perineum by finger or knife. To prevent postoperative stenosis, he suggested temporary lead stents or tubes.⁹ In some cases, multiple surgeries may be required due to restenosis.

In his book, anal fistulas were classified by number (single or multiple) and anatomic location. Deep fistulas and those involving bladder and intestine were found to be poorer in prognosis and in these cases, he had warned inexperienced surgeons. Symptoms of fistula were described as pus, feces, and gas discharge. He used rigid probes to detect direct fistulas and used flexible types to detect curved fistulas. In these surgeries, he placed the patient in a lithotomy position. His methods for treating fistulas include cauterization, un-roofing the tract, and insertion of spun yarn in the fistula (Seton placement in modern medicine).¹⁰ The possible complications include damage to the anal sphincter and fecal incontinence, which occur mostly in the deep fistulas.

He had divided hemorrhoids into two types of internal and external. He first treated patients with non-invasive therapeutic methods, which he had mentioned in earlier chapters of his book. In order to operate internal hemorrhoids, he put the patient in a squatting defecation posture until the hemorrhoids came out. The methods he recommended for

hemorrhoid resection included the use of a knife, cauterization, and thread ligation.

Albucasis described chronic constipation as the cause of the fissure and used debridement of the fissure to reach fresh tissue. He also recommended washing the fissure with warm water and applying topical balm to accelerate recovery.

He classified hernias based on anatomic location and time of occurrence. Also, Albucasis considered the defect in the fascia as the cause of the hernia. The risk factors for hernia were listed as trauma, straining, and lifting heavy objects. He prescribed fast-acting laxatives (bowel irrigation) before hernia repair. Albucasis noted that patients with incarcerated hernias were more likely to die. He treated hernias by hand reduction and repair of abdominal wall defects. He also used the cauterization method for groin hernia.¹¹

Conclusions

In conclusion, several Albucasis' methods in colorectal surgery have been cleverly designed and modeled in modern surgical procedures.

Conflicts of interest

The authors declare no conflicts of interest.

REFERENCES

- Hajar R. The air of history part III: the golden age in arab islamic medicine an introduction. *Heart Views*. 2013;14:43–6.
- Elgohary MA. Al Zahrawi: the father of modern surgery. *Ann Ped Surg*. 2006;2:82–7.
- Annajar J. Abu Alkasem Al Zehrawi (Albucasis 936-1013). *Childs Nerv Syst*. 2010;26:857–9.
- Chavoushi SH, Ghabili K, Kazemi A, Aslanabadi A, Babapour S, Ahmedli R, et al. Surgery for gynecomastia in the islamic golden age: Al-Tasrif of Al-Zahrawi (936-1013 AD). *ISRN Surg*. 2012;2012:934965.
- Amr SS, Tbakhi A. Abu Al Qasim Al Zahrawi (Albucasis): pioneer of modern surgery. *Ann Saudi Med*. 2007;27:220–1.
- Toledo-Pereyra LH. Galen's contribution to surgery. *J Hist Med Allied Sci*. 1973;28:357–75.
- Dunn PM. Galen (AD 129-200) of Pergamun: anatomist and experimental physiologist. *Arch Dis Child Fetal Neonatal Ed*. 2003;88:F441–3.
- Watters DA. Guy de Chauliac: pre-eminent surgeon of the middle ages. *ANZ J Surg*. 2013;83:730–4.
- Yesildag E, Muniz RM, Buyukunal SN. How did the surgeons treat neonates with imperforate anus in the eighteenth century? *Pediatr Surg Int*. 2010;26:1149–58.
- Garcia-Aguilar J, Belmonte C, Wong WD, Goldberg SM, Madoff RD. Anal fistula surgery. Factors associated with recurrence and incontinence. *Dis Colon Rectum*. 1996;39:723–9.
- Tebala GD. History of colorectal surgery. *Int J Colorectal Dis*. 2015;30:723–48.

Masoud Nouri-Vaskeh  a,b,c,* , Soroush Mostafavi  d , Hadi Alizadeh  d , Abdolhassan Kazemi  e,**

^a Immunology Research Center, Tabriz University of Medical Sciences, Tabriz, Iran

^b Connective Tissue Diseases Research Center, Tabriz University of Medical Sciences, Tabriz, Iran

^c Network of Immunity in Infection, Malignancy and Autoimmunity (NIIMA), Universal Scientific Education and Research Network (USERN), Tehran, Iran

^d Student Research Committee, Tabriz University of Medical Sciences, Tabriz, Iran

^e Philosophy and History Research Center, Tabriz University of Medical Sciences, Tabriz, Iran

* Corresponding author at: Director of Medical Ethics and History Research Center, Tabriz University of Medical Sciences, Daneshgah St., Tabriz, Iran Tel/fax: (+98)4133373745.

** Corresponding author at: Connective Tissue Diseases Research Center, Tabriz University of Medical Sciences, Tabriz, Iran Tel: (+98) 4133369331 Fax: (+98) 4133369315. E-mails: mnvaskeh@tbzmed.ac.ir, mnvaske@gmail.com (M. Nouri-Vaskeh), kazemi1338@gmail.com (A. Kazemi).

6 April 2020
2237-9363/

<https://doi.org/10.1016/j.jcol.2020.05.016>