



## Original Article

# Anal PAP, HPV tests and magnifying chromoendoscopy with biopsies in the diagnosis of anal intraepithelial neoplasia

Carmen Aguiar <sup>a,\*</sup>, Laura García <sup>b</sup>, María Belén Boccardo <sup>a</sup>, Macarena Vassel <sup>a</sup>, Alejandra Arriola <sup>a</sup>, Sylvia Jaumandreu <sup>c</sup>, María Carmen Rodríguez <sup>d</sup>, Carmen Alvarez <sup>d</sup>, Isabelle Heard <sup>e</sup>

<sup>a</sup> Médica Uruguaya Corporación de Asistencia Médica (MUCAM), Área de Diagnóstico y Tratamiento HPV Rectoanal, Montevideo, Uruguay

<sup>b</sup> Centro Hospitalario Pereira Rossell (CHPR), Administración de Servicios de Salud del Estado (ASSE), Laboratorio de Biología Molecular, Departamento de Patología Clínica, Montevideo, Uruguay

<sup>c</sup> Laboratorio de Citopatología, Sylvia Jaumandreu, Montevideo, Uruguay

<sup>d</sup> Laboratorio Carmen Álvarez Santin, Montevideo, Uruguay

<sup>e</sup> Independent Researcher, Paris, France

## ARTICLE INFO

## Article history:

Received 9 March 2020

Accepted 2 May 2020

Available online 4 June 2020

## Keywords:

Anal intraepithelial neoplasia (AIN)

Anal PAP

Magnifying chromoendoscopy

HPV test

## ABSTRACT

**Introduction:** Anal intraepithelial neoplasia (AIN) is the most likely precursor of squamous cells cancer which represents 90% of anal cancers. The use of biomolecular tests as a screening method has been extended by gynecology. Given the similarities that exist between the HPV disease in the lower genital tract and anorectal sectors, it is expected that HPV tests can provide information for the diagnosis, treatment and follow-up for AIN-affected patients.

**Objectives:** Comparing the performance of anal cytology, PAP and HPV tests (Hybrid Capture and Papillocheck) against the histology of the diagnosis of low- and high-grade AIN in risk groups.

**Material and methods:** A cross-sectional study was carried out to evaluate diagnostic methods for low- and high-grade AIN in 73 patients. Samples for anal PAP, Papillocheck and Hybrid Capture were taken from all patients who then, regardless of the results, underwent magnifying chromoendoscopy (MCE) along with biopsy. Diagnostic test performances and their 95% confidence intervals (CI: 95%) were calculated as well as the likelihood ratio for each test.

**Results:** Of the 73 patients, 49 (67%) were women. The average age of the patients was 38 years. In 38 patients (52%), the histology was positive with 10 (14%) grade II AIN or higher. There were no statistically significant differences in sensitivity nor in specificity for low- and high-grade AINs between any of the tests.

\* Corresponding author.

E-mails: [caguiar6042@gmail.com](mailto:caguiar6042@gmail.com), [carycarus@yahoo.com](mailto:carycarus@yahoo.com) (C. Aguiar).

<https://doi.org/10.1016/j.jcol.2020.05.003>

2237-9363/© 2020 Sociedade Brasileira de Coloproctologia. Published by Elsevier Editora Ltda. This is an open access article under the CC BY-NC-ND license (<http://creativecommons.org/licenses/by-nc-nd/4.0/>).

**Conclusion:** Anal PAP, the Hybrid Capture test (HC2, Qiagen) and PapilloCheck (Greiner Bio One) were highly sensitive but not specific for low- and high-grade AINs. Therefore, a biopsy should be conducted against a positive result of any of the tests to confirm AIN and the degree of dysplasia. The screening method selection depend on the availability but also costs of the test should be considered, since all the diagnostic tests have similar performance.

© 2020 Sociedade Brasileira de Coloproctologia. Published by Elsevier Editora Ltda. This is an open access article under the CC BY-NC-ND license (<http://creativecommons.org/licenses/by-nc-nd/4.0/>).

## Papanicolau anal, testes de HPV e cromoendoscopia de ampliação com biópsias no diagnóstico de neoplasia intraepitelial anal

### R E S U M O

#### Palavras-chave:

Neoplasia intraepitelial anal  
Papanicolau anal  
Cromoendoscopia de ampliação  
Teste de HPV

**Introdução:** A neoplasia intraepitelial anal é o precursor mais provável do câncer de células escamosas, que representa 90% dos tumores anais. O uso de exames biomoleculares como método de triagem foi ampliado pela ginecologia. Considerando-se as semelhanças entre as apresentações de HPV no trato genital inferior e anorretal, espera-se que os exames de HPV possam fornecer informações para o diagnóstico, tratamento e acompanhamento dos pacientes com neoplasia intraepitelial anal.

**Objetivo:** Comparar o desempenho da citologia anal, Papanicolau, exames para HPV (teste de captura híbrida e Papillocheck) e histologia no diagnóstico de neoplasia intraepitelial anal de baixo e alto grau em grupos de risco.

**Material e métodos:** Foi realizado um estudo transversal para avaliar métodos de diagnóstico de neoplasia intraepitelial anal de baixo e alto grau em 73 pacientes. Amostras para Papanicolau anal, Papillocheck e captura híbrida foram coletadas de todos os pacientes; independentemente dos resultados desses exames, todos foram submetidos a cromoendoscopia de ampliação (CEA) e biópsia. O desempenho dos exames e seus intervalos de confiança de 95% (95% CI) foram calculados, bem como a razão de verossimilhança para cada teste.

**Resultados:** Dos 73 pacientes, 49 (67%) eram mulheres. A idade média dos pacientes foi de 38 anos. A histologia foi positiva em 38 pacientes (52%), dos quais dez (14%) apresentaram neoplasia intraepitelial anal grau II ou superior. Não foram observadas diferenças estatisticamente significativas na sensibilidade ou especificidade para as neoplasias intraepiteliais anal de baixo e alto grau entre qualquer um dos exames.

**Conclusão:** O Papanicolau anal, o teste de captura híbrida (HC2, Qiagen) e o Papillocheck (Greiner Bio One) foram altamente sensíveis, mas não específicos para neoplasia intraepitelial anal de baixo e alto grau. Portanto, uma biópsia deve ser realizada após um resultado positivo em qualquer um dos testes para confirmar o diagnóstico de neoplasia intraepitelial anal e seu grau. A seleção do método de triagem depende da disponibilidade, mas os custos devem ser considerados, uma vez que todos os testes apresentam desempenho semelhante.

© 2020 Sociedade Brasileira de Coloproctologia. Publicado por Elsevier Editora Ltda. Este é um artigo Open Access sob uma licença CC BY-NC-ND (<http://creativecommons.org/licenses/by-nc-nd/4.0/>).

### Introduction

Anal intraepithelial neoplasia (AIN) is the likely precursor of squamous cells cancer that accounts for 90% of anal cancers. The conviction of this statement arises from retrospective research on a series anal cancer cases but there is still a substantial lack of knowledge regarding the natural history of AIN.<sup>1,2</sup> Nevertheless, there are certainties regarding its infectious etiology and relationship with 40 HPV genotypes capable of causing cellular changes in mucosal epithelia.<sup>2,3</sup>

The importance of this topic lies in the increase in the incidence of anal cancer, especially in men who have sex with men

(MSM). The incidence of anal cancer in this group is higher than 100 per 100.000 inhabitants, annually, especially if they are associated with the human immunodeficiency virus (HIV) infection, i.e., HIV+.<sup>4</sup> According to the existing data, the anal cancer incidence in VIH- MSM and women with history of HPV in the lower genital tract the incidence is 30 per 100,000 people. These figures are comparable to the incidence of cervical cancer prior to the implementation of prevention programs.<sup>5–9</sup> In Uruguay, the annual incidence of anal cancer in the general population is more frequent in women than men, at 2.09 per 100.000 vs. 1.33 per 100.000 inhabitants, respectively.<sup>10</sup> Presently, there is no data about anal cancer in Uruguayan

risk groups. Other authors have demonstrated that anoperineal condylomas is a clinical marker of AIN<sup>11,12</sup>; therefore, its presence leads to the search of anorectal internal lesions.

To this day, there is no international consensus on AIN diagnosis. An anal PAP is performed, and, in case of a positive result, a biopsy is indicated using anoscope and colposcope. This gynecological technique, when applied to the lower digestive tract, is described as high resolution anoscopy, HRA.<sup>3,6,13–15</sup> We use high resolution digestive endoscopy which allows the most magnification and the possibility to diagnose the disease in the lower rectum in areas of squamous metaplasia, something that can not be achieved using HRA.

The sensitivity of an anal PAP ranges between 80 and 90%, but the specificity does not exceed 50%.<sup>12–15</sup> In a previously published work, the sensitivity and specificity for anal PAP was seen to be 92% and 42%, respectively. As a result of the low specificity of the anal PAP, a biopsy under magnification and endoscopic staining was recommended as a procedure derived from a positive anal PAP test.<sup>16</sup>

The use of HPV tests has been extended to gynecology as a cervical cancer screening method in women over 30 years of age. The similarities that exist between HPV disease in the lower genital tract and anorectal sector has led to the application of similar screening strategies for the study of anal canal lesions.<sup>17–20</sup> If we consider that oncoviruses are inducers of changes in the cellular genome leading to anal cancer, the detection and typing of these viruses could deliver an important tool for the diagnosis and subsequent decisions to be made in this pathology. It is expected that HPV tests provide information for the diagnosis, treatment and monitoring of anorectal HPV lesions.

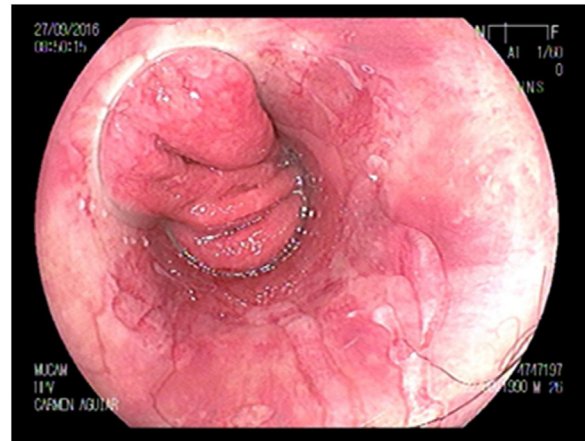
So far, HPV tests have not been validated for anal samples, but obtaining cell samples by brushing the anal canal is a simple procedure for detecting and genotyping HPV infection. This is the first work in our country for the assessment of the performance of these techniques in the study of anal lesions. This work has been approved by the Ethics Committee of the Médica Uruguaya Corporación de Asistencia Médica (MUCAM); there were no conflicts of interest.

## Objectives

The study aims to compare the performance of anal cytology (PAP) and two different HPV tests (Hybrid Capture and Papillocheck) for the diagnosis of AIN in different risk group populations, with histology as the gold standard.

## Material and methods

A cross-sectional study was carried out to evaluate diagnostic methods for high-grade AIN and any AIN. Seventy-three patients consulting the Área de Diagnóstico y Tratamiento de VPH Rectoanal (ADT-VPH) of MUCAM (Montevideo, Uruguay), between March 2017 and December 2018, were included in the study. According to their risk for AIN, patients were classified into four risk groups: Group 1—HIV-infected MSM, Group 2—non HIV-infected MSM, Group 3—women with HPV-related



**Fig. 1 – Fenestrated anoscope used to take PAP samples.**

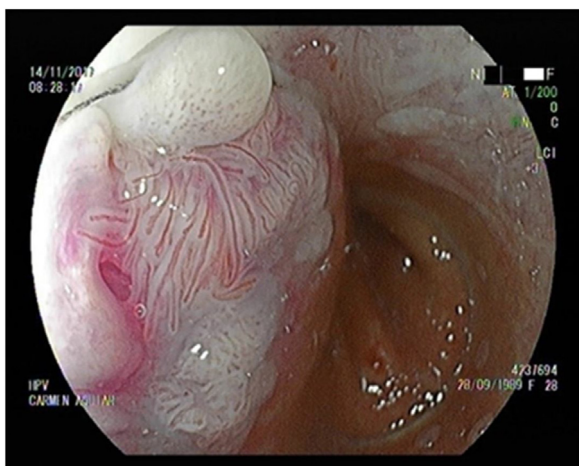
lesions in the lower genital tract and Group 4—men or women with warts in the anoperineal skin. Patients were eligible if they were older than 25 years of age, referred by a physician for the study of HPV-related anorectal lesions, attended the ADT-VPH for the first time, had not received prior treatment for HPV-related anorectal lesions and accepted participation in the study by signing a written informed consent form.

All patients underwent an anoscopy using a fenestrated disposable plastic transparent anoscope. (Fig. 1) For the cytology, two samples were taken from the anorectal mucosa in different locations, using a small wooden tongue depressor, introduced through the anoscope. A PAP smear was performed, extended on the slide and introduced in 95% ethylic alcohol. Subsequently, an HPV test sample was taken from anorectal mucosa using a cytobrush, also through the anoscope; the cytobrush was placed in a viral transport medium. These samples were sent for analysis to two different laboratories (cytology and molecular).

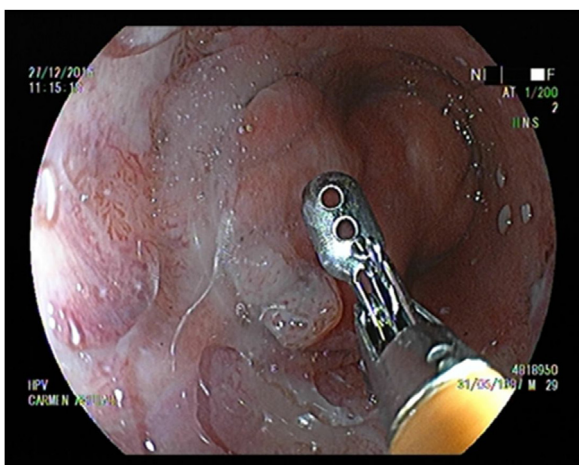
For the anal cytology, results including atypical squamous cells of undetermined significance (ASC-US), low-grade squamous intraepithelial lesion (LSIL), atypical squamous cells, not excluding HSIL (ASC-H) and high-grade squamous intraepithelial lesions (HSIL) were considered positive.

Two HPV tests were performed:

- 1) Hybrid Capture, HC2 DIGENE (QIAGEN) the reference HPV test for cervical screening. This test detects nucleic acids from 13 high-risk HPV genotypes (16, 18, 31, 33, 35, 39, 45, 51, 52, 56, 58, 59, 68) using Hybrid Capture and signal amplification through chemiluminescence. The results were categorized as positive or negative.
- 2) PapilloCheck typing test (Greiner, Germany) can detect 24 HPV genotypes, 18 high risk (16, 18, 31, 33, 35, 39, 45, 51, 52, 53, 56, 58, 59, 66, 68, 70, 73 and 82) and 6 low risk (6, 11, 40, 42, 43, 44/55) ones by amplifying a fragment of the E1 gene through a polymerase chain reaction (PCR), followed by microarrays with specific probes immobilized on a chip. The results were categorized as positive when the diagnosed genotype was one of the 13 genotypes that the Hybrid Capture test could diagnose.



**Fig. 2 – Condylomas, flat lesions and mosaic pattern, seen using magnifying chromoendoscopy.**



**Fig. 3 – Condyloma biopsy under magnification, using conventional biopsy forceps.**

Anal histology was reported as 1. Absence or presence of AIN [AIN+: low-grade lesion (LG-AIN) or high-grade lesion (HG-AIN)] or 2. Absence or presence of HG-AIN (AIN +: HG-AIN).

Patients were asked to attend a magnifying chromoendoscopy (MCE) and biopsy, within a period no longer than one month after the collection of samples, regardless of the results.

We used an EC-L 590ZW/M videocolonoscope, EPX 4450 processor and LL-4450 power source. Electronic staining with LCI and the Bli-br filter at 100x optical magnification of the anal canal and lower rectum was used. This technique discerns fine changes in the pit patterns and selects a portion of the visible light spectrum. These filters allow the vascular and glandular patterns to be highlighted for better visualization. The lesions are well visualized as condylomas, flat lesions or mosaic pattern (Fig. 2). Biopsies were performed with conventional biopsy forceps, obtaining 2–4 mm fragments (Fig. 3) When no lesions were observed, biopsy samples of all four quadrants of the transition anorectal mucosa were taken.

**Table 1 – Sample characteristics.**

Variable	n	%
Sex		
Female	49	67
Male	24	33
Average age in years/Standard deviation	38	±1
Group		
1. Men HIV+ that have sex with men	7	10
2. Men HIV- that have sex with men	8	11
3. Women with a story of HPV infection in genital tract	24	33
4. Men or women with perianal warts	34	47
Prevalence		
Citology (PAP) Positive	47	64
HSIL	8	11
ASC-H	10	14
LSIL	23	32
ASC-US	6	8
Papillocheck positive	49	67
Hybrid capture positive	53	73
Anal intraepithelial neoplasia	38	52
High-grade AIN <sup>a</sup>	10	14

<sup>a</sup> Positive histology associated with AIN II or higher.

The research was carried out in accordance to the Helsinki Declaration, evaluated and approved by the MUCAM's Ethics Committee.

### Statistical analysis

Sensitivity, specificity, positive predictive value (PPV), negative predictive value (NPV), positive likelihood ratio (PPC) and negative likelihood ratio (NPC) of the cytology and both HPV tests (Papillocheck and Hybrid Capture) were calculated to detect AIN+ and HG-AIN+.

The diagnostic tests' parameters (sensitivity, specificity, VPP, NPV, CPP and NPC) and their 95% confidence intervals (CI: 95%) were calculated using STATA v12.0. The sensitivity and specificity of the diagnostic tests was compared by contrasting the calculated 95% CI, along with determining the likelihood ratio of both the tests. Contrast of proportions were used, resulting in a significance level of  $\alpha = 0.05$ .

### Results

Seventy-three patients were enrolled, two-thirds (67%, n = 43) were women and one-third (33%, n = 24) men. The mean age of the patients was 38 years (Standard Deviation – SD = 10.84 years), the youngest patient was 25 years and the oldest 68 (Table 1).

10% of the patients (n = 7) belonged to Group 1, 11% (n = 8) to Group 2, 33% (n = 24) to Group 3 and 44% (n = 34) to Group 4 (Table 1).

In the histological analysis, 52% patients presented AIN and 14% were diagnosed with high-grade AIN (Table 1).

The anal PAP was positive in 64% (n = 47) of patients (Table 1). For the diagnostic test for AIN, the sensitivity was 76%, specificity 49%, PPV 62%, NPV 65%, PPC 1.48 and NPC 0.49 (Table 2).

**Table 2 – Clinical performance of Papillocheck, Hybrid Capture and anal PAP against histological analysis of the biopsies taken using Magnifying Chromoendoscopy.**

	AIN +	AIN -	Total	95% CI					
				SENS %	SPEC %	PPV%	NPV	PPC	NPC
Papillocheck positive	27	22	49	71	37	55	54	1,13	0.78
Papillocheck negative	11	13	24	55–87	20–55	40–70	32–76	0.82–1.57	0.10–1.51
Hybrid capture positive	29	24	53	76	31	55	55	1.11	0.75
Hybrid capture negative	9	11	20	61–87	18–48	41–67	34–74	0.75–1.3	0.38–1.5
Pap positive	29	18	47	76	49	62	65	1,48	0,49
Pap negative	9	17	26	61–91	32–66	48–76	47–83	1.03–2.14	0.25–0.95

AIN+, Presence of Anal Intraepithelial Neoplasia; AIN-, Absence of Anal Intraepithelial Neoplasia; SENS, Sensitivity; SPEC, Specificity; PPV, Positive Predictive Value; NPV, Negative Predictive Value; PPC, Positive Probability Coefficient; NPC, Negative Probability Coefficient; CI, Confidence Interval.

**Table 3 – Comparison of cytology, Papillocheck test and Hybrid Capture test sensitivity and specificity as diagnostic tools for Anal Intraepithelial Neoplasia. Contrast of proportions.**

	PAP	Papillocheck	Difference	p
Sensitivity	76%	71%	5%	NS
Specificity	49%	37%	12%	NS
	PAP	Hybrid capture	Difference	P
Sensitivity	76%	76%	0%	NS
Specificity	49%	31%	18%	NS
	Papillocheck	Hybrid capture	Difference	P
Sensitivity	71%	76%	–5%	NS
Specificity	37%	31%	6%	NS

**Table 4 – Comparison of cytology, Papillocheck Test and Hybrid Capture test sensitivity and specificity as diagnostic tools for high-grade anal intraepithelial neoplasia (AIN-II, AIN-III). Contrast of proportions.**

	PAP	Papillocheck	Difference	P
Sensitivity	90%	70%	20%	NS
Specificity	49%	37%	12%	NS
	PAP	Hybrid capture	Difference	P
Sensitivity	90%	70%	20%	NS
Specificity	49%	31%	18%	NS
	Papillocheck	Hybrid capture	Difference	P
Sensitivity	70%	70%	0	NS
Specificity	37%	31%	6%	NS

Papillocheck was positive in 67% (n=49) for the 13 genotypes that the hybrid capture could diagnose. The diagnostic test for AIN showed a sensitivity of 71%, specificity of 37%, PPV of 55%, NPV of 54%, PPC of 1.13 and NPC of 0.78 (Table 2).

The Hybrid Capture was positive in 73% (n = 53) of patients (Table 1). For the AIN diagnostic test, it showed a sensitivity of 76%, specificity of 31%, PPV of 55%, NPV of 55%, PPC of 1.11 and NPC of 0.75 (Table 2).

The comparison of anal PAP, Hybrid Capture and Papillocheck tests showed no statistical difference in their relationship to the diagnosis of AIN or HG-AIN (AIN-II, AIN-III) (Tables 3 and 4).

HPV 16 was the most frequent genotype at 33% (n = 16), followed by HPV 39 at 27% (n = 13) and HPV 59 at 20% (n = 10) (Table 5).

**Table 5 – High-risk HPV genotypes distribution detected by PapilloCheck test.**

Genotypes	n	(%)
16	16	33
39	13	27
59	10	20
52	8	16
51	7	14
56	7	14
45	6	12
68	6	12
58	5	10
31	4	8
33	4	8
18	3	6
35	3	6

n, absolute frequency; (%), Percentual relative frequency.

## Discussion

The distribution throughout the risk groups was inhomogeneous, similar to the previously published series,<sup>16</sup> with a low recruitment of the higher risk groups 1 and 2, where

the infection and presence of lesions is most expected. HIV- MSM have an estimated anal cancer incidence rate of 30/100,000, which is comparable to the incidence rate

of cervical cancer before widespread cervical PAP screening was introduced (40–50/100,000). The incidence of anal cancer among HIV+MSM is thought to be even higher (70–100/100,000).<sup>4,6</sup> In our series, most patients belonged to Group 4 (47%) but there is not enough data about anal cancer incidence in this group.

There were no statistically significant differences between sensitivity and specificity of any of the three diagnostic tests. However, cytology's specificity was the highest.

However, the PAP test depends on the observer, because it takes training to be able to interpret the anal canal samples. These samples may be contaminated with fecal matter and blood, which causes an increase in the number of unsatisfactory results. We had no unsatisfactory results in our series, probably because the samples were taken using an anoscope.

The low specificity shown by the three tests, PAP (49%), Papillocheck (37%) and Hybrid Capture (31%), may have been influenced by the quality of the reference test. A satisfactory histological analysis depends on the samples. The anal canal raises some difficulties, such as sphincter mobility and the presence of hemorrhoids. Thus, a precise cut is needed but not always achieved. Our purpose is to intensify the study of the endoscopic mucosal patterns that can predict different grades of dysplasia,<sup>16,20</sup> to avoid unnecessary biopsies.

The diagnostic yield for high-grade AIN showed no statistical difference, nor did the sensitivity and specificity. No statistical difference was found between the three tests, but both sensitivity and specificity of the anal PAP test were higher (Tables 3 and 4).

High-risk genotypes 16, 39 and 59 were the most frequently found (Table 5), and HPV 16 alone or with other genotypes was observed in 33% of the samples. These results were consistent with the results of other series.<sup>21–23</sup> This is an important epidemiological finding, since anal cancer prevention may be another benefit provided by the HPV vaccine, both for men and women.

In a recent metanalysis, it was determined that HPV 16 is the most carcinogenic of all high-risk viruses, found in the 85% of anal cancers. There is also a close link between HPV 16 and high-grade AIN, especially in HIV+ patients.<sup>2</sup>

The high prevalence of high-risk infections in patients under 25 years of age leads us to believe that the anal canal may be a reservoir that will not always result in illness (Table 1). The persisting high-risk infection, as stated by other authors, appears to be the most important predisposing factor. This persistence will depend on local immunity factors and on the virus itself.

With the obtained results, it doesn't seem possible to attribute a cancer-screening role to Papillocheck and Hybrid Capture in prevention programs. Their application could be beneficial in patients who present a persisting HG-AIN. In such cases, to determine the viral genotype would be of major significance to the carcinogenic potential of HPV 16 and for the still unknown anal oncogenic potential of the other high-risk genotypes.

The found predictive values should be interpreted with caution, given that they were obtained from a sample with determined prevalence (52% and 14% for AIN and HG-AIN, respectively), and they may vary in populations with different prevalence rates.

This study has some limitations. The sample size was not calculated due to de fact that there where not enough available tests. Also, each group is represented by a relatively small number of patients which limits the generalization of the conclusions drawn. Despite our efforts to bring attention to HPV in the lower digestive tract, there is still not enough awareness on the matter among physicians and patients.

This study has several strengths. The main strength is the application for the first time, and with encouraging results, of the Magnifying Chromoendoscopy in the diagnosis of a digestive disease such as the intraepithelial anorectal neoplasia. Another strength of this study is that it compares the diagnostic yield of three different techniques and contrasts them with the reference test.

## Conclusions

Anal PAP, Hybrid Capture 2 test (HC2, Qiagen) and Papillocheck test (Greiner Bio One) showed good sensibility but were not specific in the low- and high-grade AIN. Following a positive result, biopsies are needed to confirm the AIN and the degree of dysplasia. The screening method selection depend on the availability but also costs of the test should be considered, since all the diagnostic tests have similar performance.

This work has been financially supported by the Comisión Honoraria de Lucha Contra el Cáncer (CHLCC), support of Research Projects 2018 fund. CHLCC did not participate in the study design, collection, analysis interpretation of data, writing of the report or the decision to submit the article for publication.

## Conflicts of interest

The authors declare no conflicts of interest.

## REFERENCES

1. Daling JR. Human papillomavirus, smoking and sexual practices in the etiology of anal cancer. *Cancer*. 2004;101:270–80.
2. Lin C, Franceschi S, Clifford GM. Human papillomavirus types from infection to cancer in the anus, according to sex and HIV status: systematic review and meta-analysis. *Lancet Infect Dis*. 2018;18:198–206.
3. Palefsky JM, Rubin M. The epidemiology of anal human papillomavirus and related neoplasia. *Obstet Gynecol Clin North Am*. 2009;36:187–200.
4. Palefsky JM. Human papillomavirus-related disease in people with HIV. *Curr Opin HIV AIDS*. 2009;4(1):52–6.
5. Berry M, Jay N, Cranston R, Darragh T, Holly E, Welton M, et al. Progression of anal high-grade squamous intraepithelial lesions to invasive anal cancer among HIV infected men who have sex with men. *Int J Cancer*. 2014;134:1147–55.
6. D'Souza G, Wiley DJ, Li X, Chmiel JS, Margolick JB, Cranston RD, et al. Incidence and epidemiology of anal cancer in the multicenter AIDS cohort study. *J Acquir Immune Defic Syndr*. 2008;48:491–9.
7. Park I, Palefsky JM. Evaluation and management of anal intraepithelial neoplasia in HIV-negative and HIV-positive men who have sex with men. *Curr Infect Dis Rep*. 2010;12:126–33.

8. Moscicki A, Darragh T, Berry JM, Roberts J, Khan M, Boardman L, et al. Screening for anal cancer in women. *Low Genit Tract Dis.* 2015;19:27-42.
9. Sanjosé S, Palefsky J. Cervical and anal HPV infections in HIV positive women and men. *Virus Res.* 2002;89:201-21.
10. Comisión Honoraria de Lucha contra el Cáncer. Registro Nacional de Cáncer. IV Atlas de Incidencia del Cáncer en el Uruguay. 2014:2007-11.
11. Metcalf A, Dean T. Risk of dysplasia in anal condyloma. *Surgery.* 1995;118:724-6.
12. Pera M, Sugrañez G, Ordi J. Asociación entre la infección por el virus del papiloma humano, las lesiones premalignas del cáncer anal y el virus de la inmunodeficiencia humana: estudio prospectivo en individuos con condilomas acuminados. *Med Clin (Barc).* 1999;113:13-7.
13. Hillman RJ, Cuming T, Darragh T, Nathan M, Berry-Lawthorn M, Goldstone S, et al. IANS international guidelines for practice standards in the detection of anal cancer precursors. *J Low Genit Tract Dis.* 2016;20:1-9.
14. Berry JM, Chrobak D, Jay N, Palefsky JM. Who is ready to screen for anal squamous intraepithelial lesions and why should they perform high-resolution anoscopy? *Sex Transm Dis.* 2014;41:254-6.
15. Richel O, Hallensleben N, Kreute A, van Noesel CJ, Prins JM, de Vries HJ. High-resolution anoscopy: clinical features of anal intraepithelial neoplasia in HIV positive men. *Dis Colon Rectum.* 2013;56:1237-42.
16. Aguiar C, Jamandreu S, Alvarez Santín C, Rodríguez Álvarez MC, Ortega C. Lesiones rectoanales internas por VPH, diagnóstico mediante PAP anal y anoscopía de alta resolución con biopsias, 1era serie en Uruguay. *Rev Med del Uruguay.* 2015;31:96-101.
17. Chin-Hong PV, Berry JM, Cheng SC, Catania JA, Da Costa M, Darragh TM, et al. Comparison of patient- and clinician-collected anal cytology samples to screen for human papillomavirus-associated anal intraepithelial neoplasia in men have sex with men. *Ann Intern Med.* 2008;149:300-6.
18. Nadal S, Calore E, Nadal L. Citología anal para rastreamiento de lesiones pré-neoplásicas. *Rev Assoc Med Bras.* 2007;53:147-51.
19. Panther L, Wagner K, Proper J, Fugelso DK, Chatis PA, Weeden W, et al. High resolution anoscopy findings for men who have sex with men: inaccuracy of anal cytology as a predictor of histology high grade and intraepithelial neoplasia and the impact of HIV serostatus. *Clin Infect Dis.* 2004;38:1490-2.
20. Aguiar C, Jamandreu S, Alvarez C, Rodríguez MC. Uso de la cromosocopia digestiva con magnificación en el diagnóstico de la neoplasia intraepitelial anal. *Acta Gastroenterol Latinoam.* 2018;48:206-12.
21. Heard I, Poizot-Martin I, Potard V, Etienney I, Crenn-Hebert C, Moore C, et al. Prevalence and risks factors for anal oncogenic papillomavirus infections among HIV-infected women in France in the combination antiretroviral therapy. *Era J Infect Dis.* 2016;213:1455-61.
22. Berry JM, Palefsky JM, Jay N, Cheng SC, Darragh TM, Chin-Hong PV. Performance characteristics of anal cytology and human papillomavirus testing in patients with high resolution anoscopy guided biopsy of high grade anal intraepithelial neoplasia. *Dis Colon Rectum.* 2009;52:239-47.
23. Machalek DA, Poynten M, Jin F, Fairley CK, Farnsworth A, Garland SM, et al. Anal human papillomavirus infection and associated neoplastic lesions in men who have sex with men: a systematic review and meta-analysis. *Lancet Oncol.* 2012;13:487-500.