



Case Report

Management of rectal stump leak following emergency Hartmann's procedure

Sarah Johnston ^{a,*}, Penelope De Lacavalerie^{a,b}

^a Nepean and Blue Mountains Local Health District, Department of Colorectal Surgery, Sydney, Australia

^b University of New South Wales-Sydney, Conjoint Associate Lecturer South West Clinical School, Liverpool, Australia

ARTICLE INFO

Article history:

Received 14 October 2019

Accepted 15 January 2020

Available online 12 February 2020

Keywords:

Hartmann's procedure

Rectal stump leak

Post-operative complication

Sepsis

Palavras-chave:

Procedimento de Hartmann

Vazamento de coto retal

Complicação pós-operatória

Sepse

ABSTRACT

We report on the management of three cases of rectal stump leak and sepsis following urgent Hartmann's procedure for perforated sigmoid diverticulitis or large bowel obstruction. Two patients had significant risk factors for poor tissue healing. All patients developed features of sepsis and computer tomography scans demonstrated rectal stump leak with adjacent collections. All patients required reoperation for drainage and washout of abscess. An intraperitoneal catheter system was introduced together with drains in order to continue on the ward until tract was formed. There was no mortality and minimal morbidity. The key to management of rectal stump leak is the early and aggressive drainage of the associated collection and continued irrigation of the stump.

© 2020 Sociedade Brasileira de Coloproctologia. Published by Elsevier Editora Ltda. This is an open access article under the CC BY-NC-ND license (<http://creativecommons.org/licenses/by-nc-nd/4.0/>).

Gerenciamento do vazamento do coto retal após o procedimento de emergência de Hartmann

RESUMO

Relatamos o tratamento de três casos de vazamento de coto retal e sepse após o procedimento de urgente de Hartmann para diverticulite sigmoide perfurada ou obstrução do intestino grosso. Dois pacientes apresentaram fatores de risco significativos para uma má cicatrização tecidual. Todos os pacientes desenvolveram características de sepse e tomografia computadorizada demonstraram vazamento de coto retal com coleções adjacentes. Todos os pacientes necessitaram de reoperação para drenagem e lavagem do abscesso. Um sistema de cateter intraperitoneal foi introduzido junto com os drenos para continuar na

* Corresponding author.

E-mail: sjoh7338@uni.sydney.edu.au (S. Johnston).

<https://doi.org/10.1016/j.jcol.2020.01.005>

2237-9363/© 2020 Sociedade Brasileira de Coloproctologia. Published by Elsevier Editora Ltda. This is an open access article under the CC BY-NC-ND license (<http://creativecommons.org/licenses/by-nc-nd/4.0/>).

enfermaria até a formação do trato. Não houve mortalidade e morbidade mínima. A chave para o gerenciamento do vazamento de coto retal é a drenagem precoce e agressiva da coleta associada e a irrigação contínua do coto.

© 2020 Sociedade Brasileira de Coloproctologia. Publicado por Elsevier Editora Ltda. Este é um artigo Open Access sob uma licença CC BY-NC-ND (<http://creativecommons.org/licenses/by-nc-nd/4.0/>).

Introduction

Sigmoid colon resection, formation of an end colostomy and rectal stump oversewing (Hartmann's procedure) is a widely accepted management strategy for complicated diverticular disease and large bowel obstruction. This approach removes the risk of leakage at the site of colorectal anastomosis. However, the rectal stump itself is prone to leakage from its suture/staple line, with resulting pelvic sepsis and significant morbidity and mortality. Despite the large body of literature published on Hartmann's procedure there is a lack of information regarding the optimal management strategy for this not uncommon post-operative complication. Therefore, we report here, our management of three patients who developed persistent rectal stump leak and pelvic sepsis following emergency Hartmann's procedure.

Case reports

Case 1

A 62-year-old man newly diagnosed with acute renal failure secondary to multiple myeloma underwent an emergency Hartmann's procedure for Hinchey III diverticulitis. His post-operative course was complicated by an unplanned return to theatre on day 3 for re-look laparotomy due to post-operative haemorrhage. For treatment of his multiple myeloma the patient had been commenced on dexamethasone pre-operatively and bortezomib on post-operative day 2. He attended three times a week haemodialysis. Four weeks later he became hypotensive requiring admission to the intensive care unit. An Abdomen and Pelvic Computer Tomography (CTAP) revealed a pelvic abscess communicating with the rectal stump. The patient was taken back to theatre for drainage of the abscess, washout and drainage of the rectal stump. To achieve this lower aspect of the laparotomy wound was re-opened and an 18 Fr Foley catheter and corrugated drain inserted via this opening into the rectal stump and abscess cavity respectively after extensive washout of the peritoneal cavity (Fig. 1). Washout of the rectal stump was achieved via a 24 Fr Foley catheter inserted via the anus. The abdominal Foley catheter was flushed with 50 mL twice daily for 6 days, with removal of the rectal Foley after 4 days. The patient had a slow recovery and was discharged to the rehab ward two months following the initial Hartmann's procedure.

Case 2

A 68-year-old man underwent an emergency Hartmann's procedure for management of a retroperitoneal abscess sec-

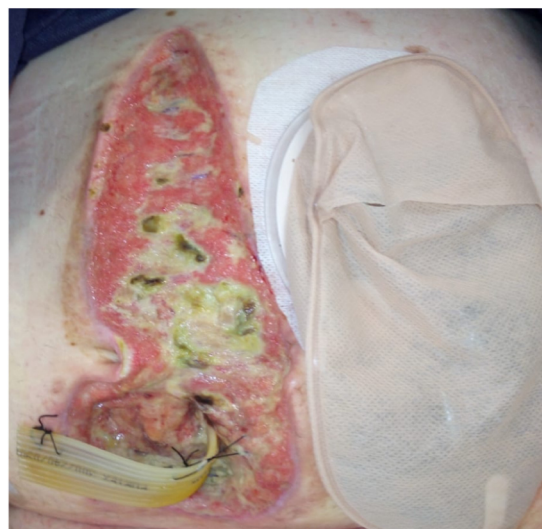

Fig. 1 – Photo demonstrating drainage of abscess secondary to rectal stump leak via insertion of a corrugated drain through the lower aspect of laparotomy wound.

ondary to perforated descending colon diverticulitis. Three weeks post-operatively the patient developed abdominal pain and fevers. Bloods revealed persistently raised inflammatory markers and a CTAP sinogram demonstrated a left intraperitoneal collection with communication to the sigmoid stump. Clinical evidence of fistula was seen with feculent output from percutaneously placed drains. Following failure of control with two CT guided percutaneous drains the patient was taken to theatre on day 39 post-op for flexible sigmoidoscopy, washout of long recto-sigmoid stump and drainage of collection. In theatre, the patient had endoscopic washout of the stump, a small laparotomy incision based on the percutaneous drain site at the skin was followed through into the peritoneal cavity in order to drain the abscess, wash the abdomen and place a 26 Fr Foley catheter through into the defect of the sigmoid colon palpable on finger exam for further washout of stump from above. A Yates (corrugated) drain was placed in the abscess cavity. The Foleys catheter was flushed daily on the ward until its removal 5 days later. The patient was discharged home with the Yates drain in situ. He was clinically well at his follow-up appointment two weeks post-discharge when the drain was removed.

Case 3

A 75-year-old female underwent an emergency Hartmann's procedure for a large bowel obstruction secondary to a sigmoid diverticular stricture. The patient was a smoker

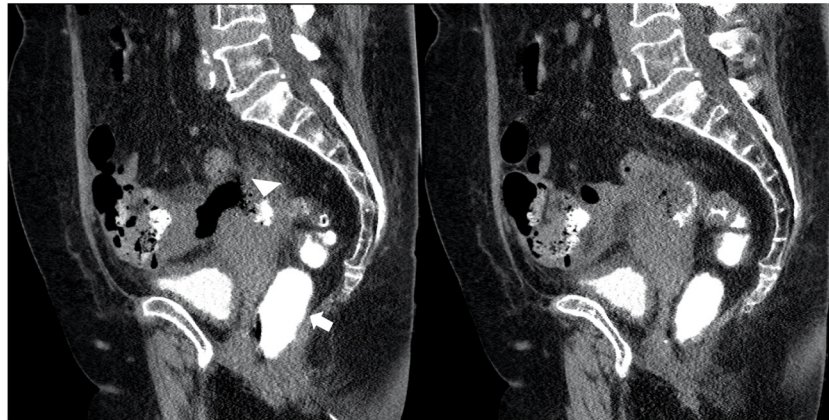


Fig. 2 – Sagittal computed tomography scan with rectal contrast demonstrating a rectal stump leak with passage of contrast from the rectum (arrow) into the adjacent collection (triangle).

with a 100 pack-year smoking history and morbid obesity. Her post-operative course was complicated by ileus, which required parenteral nutrition. She was discharged home on post-operative day 18 and re-admitted via the emergency department on post-operative day 21 with fevers. Her bloods demonstrated raised inflammatory markers and a CTAP with rectal contrast evidence of rectal stump leak with adjacent collection (Fig. 2). The following day she underwent flexible sigmoidoscopy and insertion of an 18 Fr rectal tube into the abscess cavity. The patient was discharged home with the rectal tube in situ and community nursing performed daily flushes. The rectal tube was removed 5 days post-discharge and at her clinic follow-up two weeks later the patient was systemically well.

Discussion

Hartmann's Procedure (HP) is the operation of choice for many surgeons faced with left colon pathology requiring emergency surgical intervention due to the high risk of leak from a colorectal anastomosis.¹ Therefore, it is ironic that the creation of a rectal stump comes with its own inherent risk of leak and resulting pelvic sepsis.

In the literature the occurrence of pelvic abscess following HP varies with the indication for intervention. An extended HP for malignancy has a quoted rate of 3.7%–30%,^{1–3} compared to 7.7%–20% for HP performed in the treatment of perforated diverticulitis.⁴ It has been theorised that the formation of a pelvic abscess is most likely due to leakage or blowout of the rectal stump staple line. There is no convincing evidence for or against this theory. Most published studies do not report on rectal stump leak and the two that have report a rate of 1.8%⁵ and 3%.⁶ This is significantly below the rate of pelvic abscess outlined above. Conversely, a 2005 study found that 87% of patients who developed a pelvic abscess following an extended Hartmann's procedure had a defect in the staple line, with no defects seen in patients without an abscess.¹

The pathophysiology of a rectal stump leak is not fully understood. One proposed mechanism is that the anal sphincter acts as a high resistance barrier to the drainage of

remaining faeces or mucous in the rectal stump resulting in high pressures and blow out of the staple line.⁷ Other risk factors for pelvic sepsis following an extended HP for malignancy are male gender, an extended HP with transection and stapling/suturing <2 cm above the pelvic floor and absence of foot pulses. Interestingly the same study found there was no association between post-operative pelvic sepsis and usual contributors to poor tissue healing such as smoking, corticosteroid treatment and pre-operative radiotherapy.¹ The finding of absent foot pulses as a predictor of rectal stump leak is interesting, as they serve as a surrogate marker of iliac blood supply, which would be the main blood supply of a short rectal remnant. It has been demonstrated in the literature that blood flow reduction at the rectal stump is a significant predictor for anastomotic leak in anterior resection.⁸ Therefore, it would follow that inadequate blood supply would also result in leak from a poorly healed rectal stump following HP. Our case series show an overall male preponderance (2:1) in keeping with the literature. Case 1 had significant risk factors for poor tissue healing with the early institution of chemotherapy, while Case 3 had a significant smoking history.

The three cases of rectal stump leak following HP described in our case series were diagnosed at an average of 23 days post-operatively and presented with systemic signs of sepsis. We had no cases of leak diagnosed in the early post-operative period. This is consistent with other published reports that found an average of 21⁷ and 35 days¹ between operation and detection of pelvic abscess. Given there is no standardised treatment of rectal stump leak following HP, timing of diagnosis and extent of contamination are important in guiding management. In their paper Schein et al., proposed two methods to eliminate the source of ongoing infection. Firstly, they suggested closure of the rectal stump but only in the presence of a long original rectal stump with healthy distal tissue able to be closed by staples or sutures and the absence of severe pelvic sepsis. This method is most likely to be appropriate for early leaks. Secondly, they described a re-look laparotomy and a "washout system" whereby the rectal stump is left open and irrigated for 5–7 days with tubes placed via the proximal opening and anus. Of the nine patients treated with this 'washout' method, there was one death and no signifi-

cant morbidity from the open rectal stump.⁹ Tottrup & Frost managed 31 patients with dilation of the staple/suture line, transanal drainage and daily catheter flushes. Healing was achieved in 19 patients (61%).¹ Our management strategy for late rectal stump leak and pelvic abscess similarly employs preferential drainage via the anus, paired with guided entry into the abscess cavity through the abdominal wall and the use of Foley catheters for ongoing irrigation on the ward. The use of a natural orifice for drainage of a collection is advantageous to lower procedural-associated morbidity, while the Foleys catheters allow for ongoing irrigation even following discharge home.

Conclusions

There is no standardized management of a rectal stump leak following Hartmann's procedure. We propose that optimal treatment requires definitive drainage of pelvic sepsis and irrigation of the rectal stump. We have provided three highly adaptable techniques that have allowed for the universally successful management of this complication in our patients.

Compliance with ethical standards

The patients' written consent was obtained for publication of this case series.

Conflicts of interest

The authors declare no conflicts of interest.

REFERENCES

1. Tottrup A, Frost L. Pelvic sepsis after extended Hartmann's procedure. *Dis Colon Rectum*. 2005;48:251–5.

2. Sverrisson I, Nikberg M, Chabok A, Smedh K. Hartmann's procedure in rectal cancer: a population-based study of postoperative complications. *Int J Colorectal Dis*. 2015;30:181–6.
3. Westerduin E, Musters GD, van Geloven AAW, Westerterp M, van der Harst E, Bemelman WA, et al. Low Hartmann's procedure or intersphincteric proctectomy for distal rectal cancer: a retrospective comparative cohort study. *Int J Colorectal Dis*. 2017;32:1583–9.
4. Cirocchi R, Afshar S, Shaban F, Nascimbeni R, Vettoretto N, Di Saverio S, et al. Perforated sigmoid diverticulitis: Hartmann's procedure or resection with primary anastomosis—a systematic review and meta-analysis of randomised control trials. *Tech Coloproctol*. 2018;22:743–53.
5. Constantinides VA, Tekkis PP, Senapati A. Association of Coloproctology of Great Britain I. Prospective multicentre evaluation of adverse outcomes following treatment for complicated diverticular disease. *Br J Surg*. 2006;93:1503–13.
6. Zingg U, Pasternak I, Dietrich M, Seifert B, Oertli D, Metzger U. Primary anastomosis vs Hartmann's procedure in patients undergoing emergency left colectomy for perforated diverticulitis. *Colorectal Dis*. 2010;12:54–60.
7. Westerduin E, Aukema TS, van Geloven AAW, Bemelman WA, Tanis PJ. Dutch Snapshot Research G. What to do with the rectal stump during sphincter preserving rectal cancer resection with end colostomy: a collaborative snapshot study. *Colorectal Dis*. 2018;20:696–703.
8. Vignali A, Gianotti L, Braga M, Radaelli G, Malvezzi L, Di Carlo V. Altered microperfusion at the rectal stump is predictive for rectal anastomotic leak. *Dis Colon Rectum*. 2000;43:76–82.
9. Schein M, Kopelman D, Nitecki S, Hashmonai M. Management of the leaking rectal stump after Hartmann's procedure. *Am J Surg*. 1993;165:285–7.