



Original Article

Comparison between conventional and structured magnetic resonance imaging reports in perianal fistula



Paula Carolinada Silveira Pozzi Barbosa^a, Denise Maria Rissato Camilo^b,
Thiago Franchi Nunes^b, Carlos Henrique Marques dos Santos ^{a,b,*},
Diogo Iengo Nakamura^a

^a Hospital Regional Rosa Pedrossian, Campo Grande, MS, Brazil

^b Hospital Universitário Maria Aparecida Pedrossian, Universidade Federal de Mato Grosso do Sul, Campo Grande, MS, Brazil

ARTICLE INFO

Article history:

Received 13 July 2019

Accepted 6 October 2019

Available online 1 November 2019

Keywords:

Rectal fistula

Magnetic resonance imaging

Diagnosis

Radiology

Therapeutics

ABSTRACT

Rationale: Very often magnetic resonance imaging is used in the study of complex anal fistulae, but conventional reports may contribute little to what really matters to the coloproctologist.

Objective: To compare the clarity and usefulness of the conventional report compared to structured magnetic resonance imaging in cases of anal fistula.

Method: 30 magnetic resonance exams already performed with an evaluation of anal fistula were again evaluated without the radiologist having access to the old report and a new structured report was prepared. Five proctologists evaluated the 30 conventional and 30 structured reports and answered questionnaires with eight questions comparing their practical aspects. The results were tabulated and submitted to statistical treatment considering a significant $p < 0.05$.

Results: There was a statistically significant difference in favor of the structured report in the questions “clearly defines whether it is an active fistula or fibrosis”, “clearly states whether the tract is single or multiple”, “whether the patient has anal fistula or not”. The other questions did not present differences between the groups.

Conclusion: The structured magnetic resonance report presented clearer information and was better evaluated in relation to the conventional one in the analysis of proctologists in the study of anal fistulae.

© 2019 Sociedade Brasileira de Coloproctologia. Published by Elsevier Editora Ltda. This is an open access article under the CC BY-NC-ND license (<http://creativecommons.org/licenses/by-nc-nd/4.0/>).

* Corresponding author.

E-mail: carlos.marques@anhanguera.com (C.H. Santos).

<https://doi.org/10.1016/j.jcol.2019.10.003>

2237-9363/© 2019 Sociedade Brasileira de Coloproctologia. Published by Elsevier Editora Ltda. This is an open access article under the CC BY-NC-ND license (<http://creativecommons.org/licenses/by-nc-nd/4.0/>).

Comparação entre laudo convencional e estruturado de ressonância magnética na fistula perianal

R E S U M O

Palavras-chave:

Fístula retal
Imagem por ressonância magnética
Diagnóstico
Radiologia
Terapêutica

Racional: Com muita frequência utiliza-se ressonância magnética no estudo de fístulas anais complexas, porém, laudos convencionais podem contribuir pouco para o que realmente importa ao coloproctologista.

Objetivo: Comparar a clareza e utilidade do laudo convencional com uma proposta de laudo estruturado de ressonância magnética em casos de fístula anal.

Método: 30 exames de ressonância magnética já com laudo realizados para avaliação de fístula anal foram novamente avaliados sem que o radiologista tivesse acesso ao laudo antigo e foi confeccionado novo laudo estruturado. Cinco médicos proctologistas avaliaram os 30 laudos convencionais e os 30 estruturados e responderam a questionários com oito questões comparando aspectos práticos dos mesmos. Os resultados foram tabulados e submetidos a tratamento estatístico considerando-se significante $p < 0,05$.

Resultados: Houve diferença estatisticamente significante em favor do laudo estruturado nos quesitos “define claramente se é fistula ativa ou fibrose”, “declara claramente se o trajeto é único ou múltiplo”, “fica clara a informação se o paciente tem ou não fistula anal”. Os demais quesitos não apresentam diferença entre os grupos.

Conclusão: O laudo estruturado de ressonância magnética apresentou informações mais claras e foi melhor avaliado em relação ao convencional na análise dos proctologistas no estudo de fístulas anais.

© 2019 Sociedade Brasileira de Coloproctologia. Publicado por Elsevier Editora Ltda. Este é um artigo Open Access sob uma licença CC BY-NC-ND (<http://creativecommons.org/licenses/by-nc-nd/4.0/>).

Introduction

Anal fistulas are common conditions in coloproctology outpatient clinics. It is believed that an anal abscess may progress to fistula in 26–38% of cases, particularly in men in their 40s. Most fistulas are inter-sphincteric or low trans-sphincteric; therefore, palpation of fibrosis on physical examination can determine if there is little sphincter involvement, and classic surgical treatment such as fistulotomy or fistulectomy may be indicated, with a high cure rate and a small chance of fecal incontinence.¹

However, there are many situations in which the outpatient examination alone does not provide sufficient safety to refer the patient for surgery, such as in cases where the fistulous tract is not palpable, suggesting high, suprasphincteric or extra-sphincteric fistulae in women, complex fistulas, recurrences, Crohn's disease-associated fistulas, etc. In these cases, imaging tests have been recommended for a better study of the fistulous tract, its relation with the sphincters, presence of purulent collections, and secondary tracts. The available methods include fistulography, ultrasound, computed tomography, and Magnetic Resonance Imaging (MRI).^{2,3}

Fistulography, which has been widely used in the past, is practically in disuse today due to its low sensitivity and specificity compared to other methods.⁴ Tomography, which is increasingly used in emergency rooms, is an excellent exam in cases of anal abscess, but it is not as accurate as MRI or ultrasound for fistulae evaluation.⁵ The latter has shown very good results, especially when using the three-dimensional

transducer, having as its main problem the high cost, not being available in most centers, and requiring highly trained professionals to perform it. Thus, MRI has been used as the main imaging method in the cases of anal fistulas mentioned above.⁴⁻⁶

Despite the high quality of the method, there is often a gap between what radiologists offer in the report and what coloproctologists really need to know for surgical programming. Detailed descriptions of non-fistula-related pelvic structures, brief descriptions of the fistulous tract, and classifications poorly used or unused in attending physician practice are some examples of everyday situations that often make an excellent radiological method of little practical use. This problem is not specific to anal fistulas and, to solve it, the creation and publication of structured reports, which are jointly constructed by radiologists dedicated to a specific area and by specialists, has been increasingly frequent in order to elaborate objective reports that really provide the needed information.⁷⁻¹²

Based on successful correlated experiences and the need for clearer information in the description of anal fistulae, we came up with the idea of preparing a structured MRI report for anal fistula study and its evaluation by professionals in the field.

Objective

Compare the clarity and usefulness of conventional reporting with a proposal for a magnetic resonance structured reporting in cases of anal fistula.

Method

The study was evaluated and approved by the Research Ethics Committee of the Mato Grosso do Sul Regional Hospital. We selected 30 consecutive pelvic MRI reports from the Mato Grosso do Sul Regional Hospital from January to December 2018, all with anal fistula and indicated for its study. All exams had a descriptive report and also had been made available to patients and attending physicians. Patients' identification data were removed from the reports, and each exam received a number from 1 to 30 so that later it could be paired with the structured report.

A structured MRI report model was constructed to clarify the information considered useful to coloproctologists for the study of anal fistulas and that could also contribute to treatment (Table 1).

Subsequently, each of the 30 exams was again evaluated and a new report was prepared, now using the structured model, in order to generate two reports for each exam, one conventional and the other structured. The next step was to present the 60 reports to five coloproctologists to analyze each report and make an objective assessment of their quality. To this end, a questionnaire with 9 questions was elaborated (Table 2), which should be answered for each report analyzed, thus totaling 150 questionnaires for the conventional reports and 150 for the structured ones. In this questionnaire, the first eight questions (regarding the fundamental information) had "yes" or "no" answer choices, which assessed the adequacy of the fundamental and crucial information from all reports of anorectal fistula patients. Question 9 assessed overall satisfaction.

Responses were tabulated and compared between groups, whose results were statistically analyzed using the McNemar test. The comparison between both types of report models, in relation to the degree of satisfaction with the information contained in the report, was performed using the nonparametric Wilcoxon test. For such, the SPSS Statistics software, version 24.0, was used considering a significance level of 5%.

Results

The answers to questions 1–8 of the 300 questionnaires, (150 for conventional and 150 for structured reports) are shown in Table 3. In the question "Does the report adequately state whether the fistula is active or fibrous?" there was a significant change in the profile of responses (McNemar test; $p < 0.001$), and of the 100 negative (no) responses in the descriptive report evaluation, 72.0% ($n = 72$) of them became positive (yes) in the structured report. Still for this question, only 6.7% ($n = 3$) of the 50 positive responses in the descriptive report became negative in the structured report.

In the question "Does the report adequately describe the fistulous tract, whether single or multiple?" there was also a significant change in the response profile (McNemar test; $p < 0.001$), and of the 36 negative responses in the descriptive report evaluation, 97.2% ($n = 35$) of them became positive in the structured report. Still for this question, only 0.9% ($n = 1$)

of the 114 positive answers in the descriptive report became negative in the structured report.

Regarding the question "Does the report adequately state whether the fistula opening is internal or external?", of the 103 negative responses in the descriptive report all were positive in the structured report, although none of the positive responses in the descriptive report became negative in the structured report. Therefore, it was not possible to perform the McNemar test; however, the change to the positivity of responses in the structured report is evident. The same was observed in the questions "Does the report adequately state the relationship with sphincter?" and "Does the report adequately state if there are abscesses?" in which 24 and 12 negative responses, respectively, became positive in the structured report. Also, for these two questions, none of the positive answers in the descriptive report became negative in the structured report.

In the question "Does the report mention the classification developed by Parks, Gordon and Hardcastle?" there was no significant change in the response profile (McNemar test; $p = 0.061$), although presenting a tendency to do so, and of the 127 negative responses in the descriptive report evaluation, 15.7% ($n = 20$) of them became positive in the structured report. Yet for this question, 39.1% ($n = 9$) of the 23 positive responses in the descriptive report became negative in the structured report.

Finally, in the question "Assuming the image description is correct, does the patient have anorectal fistula?"—similar to the two initial questions, there was a significant change in the response profile (McNemar test; $p = 0.007$), and of the 5 negative answers in the descriptive report evaluation, 40.0% ($n = 2$) of them became positive in the structured report. Yet for this question, only 9.0% ($n = 13$) of the 14 positive answers in the descriptive report became negative in the structured report.

Results are presented as relative frequency (absolute frequency); p -value in McNemar test. Bold results show changes in the responses from the descriptive to the structured report.

In the last survey question inquiring "how satisfied he was with the information contained in the report", where 1 = not at all satisfied; 2 = dissatisfied, 3 = neutral; 4 = satisfied, and 5 = very satisfied, there was a difference between the degree of satisfaction with the descriptive report and the structured one (Wilcoxon test, $p < 0.001$), with the degree of satisfaction with the descriptive report ranging from 1 to 5, median satisfaction of 3 (neutral), while the degree of satisfaction with the structured report ranged from 2 to 5, with a median satisfaction of 5 (very satisfied). These results are illustrated in Fig. 1.

Discussion

If an imaging test usually generates a high expectation for the patient and their relatives, in the case of MRI study for anal fistulas, it can be said that the attending physician expects the most from this test. This is because the diagnosis is already made and the treatment, often surgical, is already indicated, so that, for the patient, MRI adds little. Regarding the coloproctologist, the fistulous tract relationship with the sphincters, presence or absence of secondary tracts, tract extension, etc.,

Table 1 – Structured reporting model of pelvic magnetic resonance imaging.

Equipment: GE Discovery 750W 3.0 Tesla
 Paramagnetic Contrast: Omniscan intravenous, 15 mL
 Clinical indication: perianal fistula study
 Report:
 Main findings:
 Intersphincteric/transsphincteric/suprasphincteric/extrasphincteric fistula
 Inner orifice: .H in circumference of anal canal at pectineal level
 External orifice: .H to .cm from anal edge
 Tract: linear/tortuous/horseshoe
 [additional comments]
 Fistulous tract extension: cm
 Secondary branching: [comments]
 Example: linear/horseshoe/circumferential in the intersphincter/ischioanal/supra-elevator space
 Abscess / microabscess: present/absent
 [additional comments]
 Diffusion Behavior (DWI): Signs of Activity/Fibrosis
 Other findings:
 Examples:
 “Bladder: distended, thin walls and homogeneous content.” “Prostate and seminal vesicles: normal signal intensity and morphology.” “Anal and rectosigmoid canal: no evidence of expansive or stenosing lesions.” “No free fluid or collection in pelvic cavity.” “Absence of pelvic lymph node enlargement.”

Table 2 – Questionnaire applied to coloproctologists for evaluation of magnetic resonance reports.

1. Does the report adequately state whether the fistula is active or is fibrosis?	Yes	No
2. Does the report adequately describe the fistulous tract, whether single or multiple?	Yes	No
3. Does the report adequately state whether the fistula opening is internal or external?	Yes	No
4. Does the report properly state the relationship with sphincter?	Yes	No
5. Does the report adequately state if there are abscesses?	Yes	No
6. Does the report adequately state if there are other associated diseases?	Yes	No
7. Does the report mention the classification by Parks, Gordon and Hardcastle?	Yes	No
8. Assuming the image description is correct, does the patient have anorectal fistula?	Yes	No
	1 – not at all satisfied	
	2 – dissatisfied	
9. How satisfied are you with the information in this report?	3 – neutral	
	4 – satisfied	
	5 – very satisfied	

Table 3 – Answers to questions about the MRI report for anal fistula diagnosis, both for descriptive and structured reports.

Question	Response according to the report model			p-value
	Structured	Descriptive		
		Yes	No	
1. Does the report adequately state whether the fistula is active or is fibrosis?	Yes	94.0 (47)	72.0 (72)	<0.001
	No	6.0 (3)	28.0 (28)	
2. Does the report adequately describe the fistulous tract, whether single or multiple?	Yes	99.1 (113)	97.2 (35)	<0.001
	No	0.9 (1)	2.8 (1)	
3. Does the report adequately state whether the fistula opening is internal or external?	Yes	100.0 (47)	100.0 (103)	–
	No	0.0 (0)	0.0 (0)	
4. Does the report properly state the relationship with sphincter?	Yes	100.0 (126)	100.0 (24)	–
	No	0.0 (0)	0.0 (0)	
5. Does the report adequately state if there are abscesses?	Yes	100.0 (138)	100.0 (12)	–
	No	0.0 (0)	0.0 (0)	
6. Does the report adequately state if there are other associated diseases?	Yes	100.0 (127)	100.0 (23)	–
	No	0.0 (0)	0.0 (0)	
7. Does the report mention the classification by Parks, Gordon and Hardcastle?	Yes	60.9 (14)	15.7 (20)	0.061
	No	39.1 (9)	84.3 (107)	
8. Assuming the image description is correct, does the patient have anorectal fistula?	Yes	91.0 (132)	40.0 (2)	0.007
	No	9.0 (13)	60.0 (3)	

are key information for surgery programming and a better outcome. However, it is often frustrating to receive a report in which such information is unclear and, despite the cost, dif-

ficulty, and time spent by the patient, adds little to what was already known at the time of the proctological examination. This is certainly not due to method failure, as MRI has been

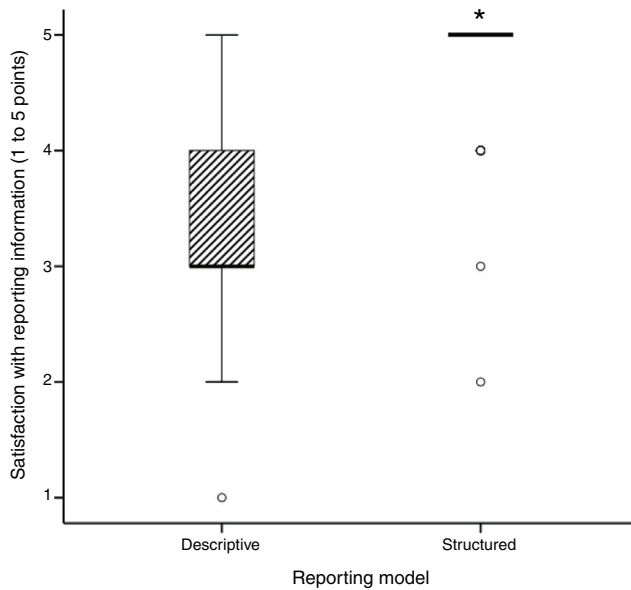


Fig. 1 – Box plot graph illustrating the degree of satisfaction with the information contained in the MRI report, according to the descriptive and structured report models. The bold horizontal line represents the median, the box with the diagonal lines represents the interquartile range between the 25th and 75th quartiles, the bars represent the lower and upper adjacent values, and the circles represent the outliers. ^a Significant difference from the descriptive model (Wilcoxon test, $p < 0.001$).

recognized as an excellent exam in the study of anal fistulas. There has probably been a lack of closer proximity between radiologists and coloproctologists for the definition of what is intended with the examination. This was the motivation for this investigation and we believe the goal has been achieved.

The idea of creating structured reports emerged a few years ago in various fields of medicine. In a study of structured reports for coronary CT angiography, physicians' knowledge of the degree of stenosis in the main coronary arteries was improved when structured reports were used.¹³ Similarly, structured reports have been shown to improve the clinical impact on tumor staging and surgical planning for pancreatic and rectal carcinoma.¹⁴ One study showed that less than 50% of free-text CT reports used for pancreatic cancer staging included standard terminology for vascular involvement, a key component in determining resectability.¹⁵ Such shortcomings could be overcome by using structured reporting models. Brook et al.¹⁴ compared the results of the structured versus unstructured CT report findings for staging and subjective assessment of pancreatic adenocarcinoma resectability and confirmed the best quality of structured reporting.

MRI has also been the subject of publications regarding structured reporting. Gassenmaier et al.⁷ demonstrated the advantage of structured reporting on shoulder MRI. The Korean Society of Radiology has published a consensus of MRI structured reporting on rectal cancer,⁸ while other authors have shown the benefits of structured MRI reporting on multiple sclerosis,⁹ endometrial cancer,¹⁰ and endometriosis.¹¹

In the study of anal fistula, there are already other publications regarding the structured MRI report, which allows us to make comparisons with the results obtained here, although they are different reports and the method of analysis is not exactly the same as the one used here. Thippavong et al.¹⁶ observed that MRI examination is essential in preoperative anal fistula evaluation, but that structured reporting offers even more benefits. Tuncyurek et al.¹⁷ in a study very similar to the one presented here also obtained from surgeons the conclusion that the structured report is clearer than the conventional one and is more helpful in surgical planning. The present research corroborates the published data, since these results are in full agreement with the literature.

If MRI was already considered the method of choice for preoperative analysis of anal fistulas,^{18,19} with already very robust results of its efficacy, it was still necessary to bring to clinical practice what was observed in the studies, and it is likely that these publications on structured reporting, now corroborated by the present research, may do this link by extracting with better quality what the exam has the potential to offer.

Although some questions were not statistically significant, in many cases there was a change for the better with the structured report and in none the opposite occurred. Observing only those with significance, we highlight the first one of them in which more clarity was seen with the structured report regarding the presence of active fistula or only fibrosis. This is a major point because, postoperatively, patients may often have vague local complaints but no pus discharge, and MRI could indicate fistula when it is really just fibrosis. The same applies to Crohn's disease, when anti-TNF treatment may lead to complete healing and an inadequate MRI interpretation could lead a diagnosis of fistula and, in common cases of cryptoglandular abscesses, fibrosis will result in this region, which cannot be confused with fistula either, because in all the situations mentioned here there is interference in the approach to be taken.

Moreover, the identification of secondary tracts is of paramount importance, as their non-identification is a frequent cause of recurrence, as surgical treatment is incomplete.²⁰ Therefore, if this information is clear, the proctologist will be better prepared for the surgery and the outcome will probably be better. The structured report also made it more clear in the opinion of those surveyed whether MRI indicated the presence or absence of fistula, which might seem obvious at first, but sometimes extensive reports addressing several aspects that seem important to the radiologist may not be clear about the primary information for the surgeon. Finally, the last question showed that there was greater satisfaction of respondents with the structured versus conventional report. It should be noted that this is not a satisfaction regarding personal preferences, but based on the information gathered and the form of presentation. As we said initially, both MRI and radiologist qualifications were the same, what made the difference was the mode of presentation, obtaining higher quality with the same resources only through dialogue and interaction of ideas between the specialties.

The limitations of this study include the relatively small number of the medical population interviewed from a single center. Also, the evaluation criteria of the conventional and structured reports presented here are a proposal of the

authors, which they elaborated without validation and without direct method of comparison with the literature because the other two publications on the subject do not have exactly the same method used here. Further multicenter studies and a more expressive cohort are needed to reinforce our hypothesis.

Thus, based on the results obtained here and the review of publications on structured or unstructured MRI reports, it is evident that we should move towards standardizing the analysis and description of the findings, in order to facilitate the interpretation by the requester and comparisons with previous examinations, a very useful situation for the treatment of anal fistulas.

Conclusion

The magnetic resonance structured report presented clearer information and was better evaluated compared to the conventional one in the analysis of proctologists in the study of anal fistulas.

Conflicts of interest

The authors declare no conflicts of interest.

REFERENCES

- Sahnan K, Askari A, Adegbola SO, Warusavitarnae J, Lung PFC, Hart A, et al. Persistent fistula after anorectal abscess drainage: local experience of 11 years. *Dis Colon Rectum*. 2019;62:327–32.
- Bakhtawar N, Usman M. Factors increasing the risk of recurrence in fistula-in-ano. *Cureus*. 2019;11:e4200.
- Feng ST, Huang M, Dong Z, Xu L, Li Y, Jia Y, et al. MRI T2-weighted imaging and fat-suppressed t2-weighted imaging image fusion technology improves image discriminability for the evaluation of anal fistulas. *Korean J Radiol*. 2019;20:429–37.
- Almeida IS, Jayarajah U, Wickramasinghe DP, Samarasekera DN. Value of three-dimensional endoanal ultrasound scan (3D-EAUS) in preoperative assessment of fistula-in-ano. *BMC Res Notes*. 2019;12:66.
- Regadas FS, Murad-Regadas SM. Commentary on 'Impact of 3-dimensional endoanal ultrasound on the outcome of anal fistulasurgery: a prospective cohort study'. *Colorectal Dis*. 2015;17:1112–3.
- Balcı S, Onur MR, Karaosmanoğlu AD, Karçaaltıncaba M, Akata D, Konan A, et al. MRI evaluation of anal and perianal diseases. *Diagn Interv Radiol*. 2019;25:21–7.
- Gassenmaier S, Armbruster M, Haasters F, Helfen T, Henzler T, Alibek S, et al. Structured reporting of MRI of the shoulder — improvement of report quality? *Eur Radiol*. 2017;27:4110–9.
- KSAR Study Group for Rectal Cancer. Essential items for structured reporting of rectal cancer MRI: 2016 consensus recommendation from the Korean society of abdominal radiology. *Korean J Radiol*. 2017;18:132–51.
- Alessandrino F, Pichiecchio A, Mallucci G, Ghione E, Romani A, Bergamaschi R, et al. Do MRI structured reports for multiple sclerosis contain adequate information for clinical decision making? *AJR Am J Roentgenol*. 2018;210:24–9.
- Liu Y, Feng Z, Qin S, Yang J, Han C, Wang X. Structured reports of pelvic magnetic resonance imaging in primary endometrial cancer: potential benefits for clinical decision-making. *PLoS One*. 2019;14:e0213928.
- Mattos LA, Goncalves MO, Andres MP, Young SW, Feldman M, Abrão MS, et al. Structured ultrasound and magnetic resonance imaging reports for patients with suspected endometriosis: guide for imagers and clinicians. *J Minim Invasive Gynecol*. 2019;26:1016–25.
- Gomez AA, Nunes TF, Santos CHM, Rissato DM, Tibana TK, Adôrno IE, et al. Comparison of conventional and structured report in the evaluation of Crohn's disease through enterography. *J Coloproctol*. 2018;38:290–4.
- Bosmans JM, Weyler JJ, Parizel PM. Structure and content of radiology reports, a quantitative and qualitative study in eight medical centers. *Eur J Radiol*. 2009;72:354–8.
- Brook OR, Brook A, Vollmer CM, Kent TS, Sanchez N, Pedrosa I. Structured reporting of multiphasic CT for pancreatic cancer: potential effect on staging and surgical planning. *Radiology*. 2015;274:464–72.
- Marcal LP, Fox PS, Evans DB, Fleming JB, Varadhachary GR, Katz MH, et al. Analysis of free-form radiology dictations for completeness and clarity for pancreatic cancer staging. *Abdom Imaging*. 2015;40:2391–7.
- Thippavong S, Costa AF, Ali HA, Wang DC, Brar MS, Jhaveri KS. Structured reporting of MRI for perianal fistula. *Abdom Radiol (NY)*. 2019;44:1295–305.
- Tuncyurek O, Garces-Descovich A, Jaramillo-Cardoso A, Durán EE, Cataldo TE, Poylin VY, et al. Structured versus narrative reporting of pelvic MRI in perianal fistulizing disease: impact on clarity, completeness, and surgical planning. *Abdom Radiol (NY)*. 2019;44:811–20.
- Tolan DJ. Magnetic resonance imaging for perianal fistula. *Semin Ultrasound CT MR*. 2016;37:313–22.
- Ho E, Rickard MJFX, Suen M, Keshava A, Kwik C, Ong YY, et al. Perianal sepsis: surgical perspective and practical MRI reporting for radiologists. *Abdom Radiol (NY)*. 2019;44:1744–55.
- Li J, Yang W, Huang Z, Mei Z, Yang D, Wu H, et al. Clinical characteristics and risk factors for recurrence of anal fistula patients. *Zhonghua Wei Chang Wai Ke Za Zhi*. 2016;19:1370–4.