



Case Report

Chagasic megacolon in Venezuela – case report

Victoria Dowling Enez *, Carla Izarra Henriquez

Hospital Central Universitario Antonio María Pineda, General Surgeon & Coloproctologist, Barquisimeto, Lara, Venezuela

ARTICLE INFO

Article history:

Received 2 August 2019

Accepted 6 October 2019

Available online 30 October 2019

Keywords:

Chagasic megacolon

Chronic constipation

Surgery

Trypanosoma cruzi

Palavras-chave:

Megacólon chagásico

Constipação crônica

Cirurgia

Trypanosoma cruzi

ABSTRACT

Chagasic megacolon is the second most frequent cause of manifestation of the digestive forms of Chagas disease (*trypanosoma cruzi* parasitosis), characterized by progressive pseudo-occlusive symptoms or chronic constipation, caused by an alteration in the functioning of the colonic wall musculature. In Venezuela, cases of chagasic disease reported in the past are referred to chagasic heart disease, this being the first documented case of chagasic megacolon. We broach herein a case of chagasic megacolon in which early diagnosis and prompt surgical treatment led to a successful outcome.

© 2019 Sociedade Brasileira de Coloproctologia. Published by Elsevier Editora Ltda. This is an open access article under the CC BY-NC-ND license (<http://creativecommons.org/licenses/by-nc-nd/4.0/>).

Megacólon chagásico na Venezuela

RESUMO

O megacólon chagásico é a segunda causa mais frequente de manifestação das formas digestivas da doença de Chagas (parasitose do *Trypanosoma cruzi*), caracterizado por sintomas pseudo-oclusivos progressivos ou constipação crônica, causado por uma alteração no funcionamento da musculatura da parede do cólon. Na Venezuela, os casos da doença chagásica relatados no passado são referidos como doença cardíaca chagásica, sendo este o primeiro caso documentado de megacólon chagásico. Neste artigo, abordamos um caso de megacólon chagásico no qual o diagnóstico precoce e o tratamento cirúrgico imediato levaram a um resultado bem-sucedido.

© 2019 Sociedade Brasileira de Coloproctologia. Publicado por Elsevier Editora Ltda. Este é um artigo Open Access sob uma licença CC BY-NC-ND (<http://creativecommons.org/licenses/by-nc-nd/4.0/>).

Introduction

Chagas disease has several types of manifestations, including cardiac and digestive. Chagasic megacolon is the second most frequent cause of manifestation of the digestive forms of Chagas disease (*trypanosoma cruzi* parasitosis),¹ characterized by progressive pseudo-occlusive symptoms or chronic constipa-

* Corresponding author.

E-mail: v.dowling@hotmail.com (V. Dowling Enez).

<https://doi.org/10.1016/j.jcol.2019.10.001>

2237-9363/© 2019 Sociedade Brasileira de Coloproctologia. Published by Elsevier Editora Ltda. This is an open access article under the CC BY-NC-ND license (<http://creativecommons.org/licenses/by-nc-nd/4.0/>).

tion, caused by an alteration in the functioning of the colonic wall musculature, as a result of the destruction of the neurons of the myenteric plexus.

The World Health Organization (WHO) estimates that this disease affects between 16 and 18 million individuals around the world. In Latin America there are about 35 million infected and 100 million who would be at risk of contracting it (25% of the population). In fact, about 50,000 people die annually.²

Chagas disease is currently considered a public health problem in Latin America despite the effectiveness of preventive and hygienic measures, among which are: eliminating transmitting insects.

With the increase in population migration, the probability of transmission by blood transfusion has become substantial in the United States; In fact, approximately 500,000 infected people live in the US. To this is added that the *Trypanosoma cruzi* has infected marsupials and raccoons in regions that extend to North Carolina.³

In Brazil, Chagas disease is considered a priority problem, with the central, southern, eastern and northwest regions of the country being the most affected, with areas where patients have severe heart damage or sudden death, prevailing young people. In the states of Minas Gerais, Sao Paulo and Goiás, megacolon and megaesophagus are often observed with significant frequency.⁴

In Venezuela, cases of chagasic disease reported in the past are referred to chagasic heart disease, this being the first documented case of chagasic megacolon.

Clinical case

50 year-old male patient, a native of upper Humocaró, Lara state, Venezuela, with no previous surgical history, or a history of blood transfusions, referred to a Coloproctology consultation from Digestive Medicine due to progressive pseudo-occlusive symptoms, 3 months evolution, expressed in progressive diffuse abdominal pain, absence of bowel movements, which increased intermittently together with weight loss (Fig. 1).

After a preliminary evaluation in our medical consultation, the following studies were requested:

Abdominal ultrasound: at the level of the abdominal cavity, in both hypochondria and flanks, presence of dilated intestinal loops with echoes inside in constant movement. Conclusion: Image suggestive of intestinal obstruction.

Intestinal transit: normal mucous pattern. In 6h period, contrast advances to the ascending colon. Conclusion: no alterations,

Colonoscopy: Mucosa without lesions. Advance without difficulty.

CT abdomen and pelvis: Distension of intestinal loops and rectum. Free liquid in abdominal cavity (Fig. 2).

In view of the results, patient was scheduled for diagnostic laparoscopy, where the following findings were evidenced: (1) 100 cc of free cetrine fluid in cavity; (2) Dilation of the ascending, transverse and descending colon double diameter; (3) Sigmoid and rectum without dilation. Staged biopsy and laparoscopic assisted loop ostomy are performed.

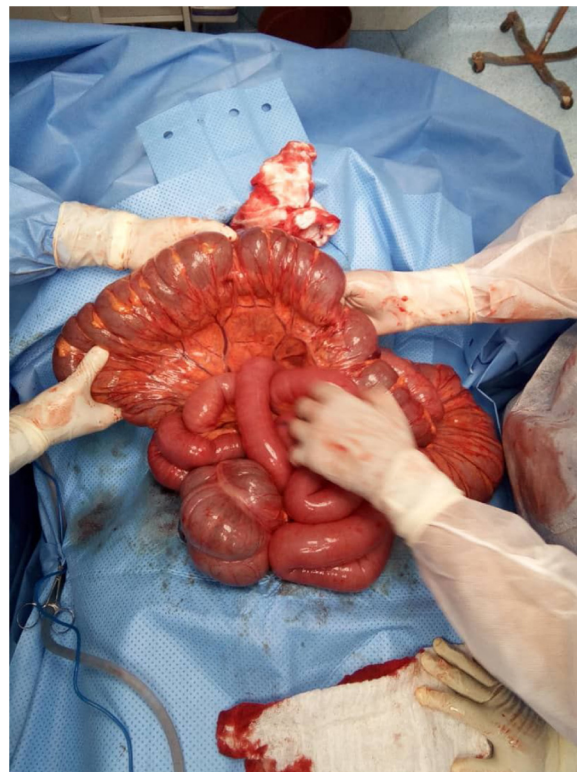


Fig. 1 – Chagasic megacolon.

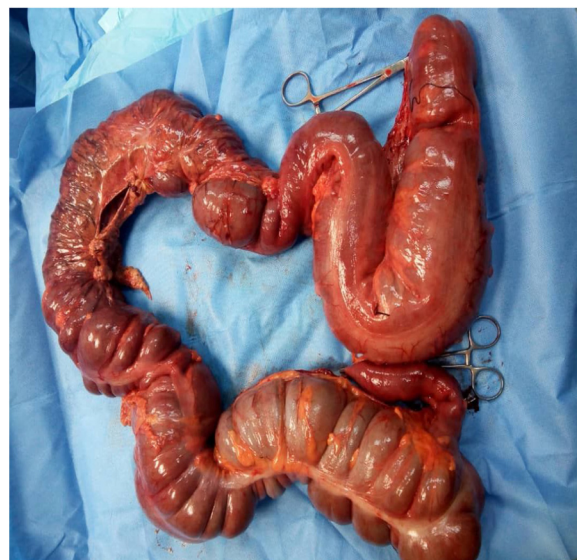

Fig. 2 – Total colectomy.

Biopsy results: 1, 2 and 3 mucosal fragments with exacerbated chronic inflammation. Absence of myenteric plexus in all samples.

Specific immunological tests are requested for the detection of specific antibodies against the parasite in the blood: Complement fixation (machado guerreiro reaction); Elisa IgG; Both positive.

Elective surgery, with total colectomy performed alongside ileo-rectal anastomosis. Pathological anatomy report: chronic myositis with mixed inflammation around myenteric plexuses. Currently in follow-up consultations, asymptomatic, presents almost daily intestinal movement.

Discussion

Treatment of chagasic megacolon is surgical. In spite of the numerous techniques used, the majority have recurrence over time, mainly left hemicolectomy and are not curative of the disease.

Chagas disease is considered a paradigm of autoimmune infectious disease. Current research lines focus on the study of molecules involved in the exchange of information between the neurons of the myenteric plexus. However, measures to prevent transmission are best possible treatments, and in the future, surgical treatments may not even be necessary.

Conflicts of interest

The authors declare no conflicts of interest.

REFERENCES

1. Beatriz Uriarte Vergara, del Hoyo Aretxabala Izaskun, González de Miguel Melania, Gutiérrez Ferreras Ana, Azpiazu Arnaiz Pilar, Vilar Achabal Íñigo. Megacolon Chagásico. CIR ESP. 2016;94(Espec Congr):729.
2. Health Secretary. Manual of Diagnosis and Treatment of Chagas Disease. Health Secretary; 2014.
3. Karsten V, Davis C, Kuhn R. Trypanosoma cruzi in wild raccoons and opossums in North Carolina. J Parasitol. 1992;78(3):547-9.
4. Dra. Farah María Kindelán Merceroçon, Dr. Jorge Luis Pérez León II y Dra. Olga Lén León Quindemil. Policlínico Docente "30 de Noviembre", Universidad de Ciencias Médicas, Santiago de Cuba, Cuba. Chagasic megacolon in older adults.