




Original Article

Tansanal total mesorectal excision (TaTME): systematization and mediated results in 10 patients



Guilherme Inácio Bertoldo de Melo e Patriarca da Silva Neiva *, Fábio Alves Soares, Silvana Marques e Silva, Pedro Wilson Diniz Viana, Mário Nóbrega de Araújo Neto, Olane Marquez de Oliveira, Mauricio Cotrim Nascimento

Hospital de Base do Distrito Federal, Unidade de Coloproctologia, Brasília, DF, Brazil

ARTICLE INFO

Article history:

Received 18 July 2019

Accepted 15 September 2019

Available online 28 October 2019

Keywords:

TaTME

Total mesorectal excision

Rectal cancer

Colorectal surgery

Transanal surgery

ABSTRACT

Background: Transanal total mesorectal excision is a surgical technique for minimally invasive resection of the rectum and perirectal tissues. It is indicated for patients with medial and distal rectum cancer confined to the mesorectal envelope. This study describes a series of patients undergoing transanal total mesorectal excision.

Methods: Ten patients were selected to undergo transanal total mesorectal excision using the SILS-Port® platform. All patients included here had middle or low rectal cancer. Abdominal access for proximal colon mobilization was performed by laparoscopy in all cases. As a rule, in 9 of the 10 cases, the surgical specimen was removed transanally.

Results: During a 41-month period, 10 patients underwent transanal total mesorectal excision based on curative intent. The first indication for transanal total mesorectum excision was medial and distal rectal cancer, locally invasive and confined to the mesorectal envelope. The median age of patients with rectal cancer at the time of surgery was 61 years (mean 59.4 years, range 22–78 years), with 80% (8) female and 20% (2) male. The median surgical time was 305' (mean 314', range 260–420'). The median postoperative length of stay was five days (average of 7.3 days, interval of 3–23 days). There was no postoperative mortality. Surgical complications included postoperative ileus (n = 1), bladder paresis (n = 1), and ileostomy stenosis (n = 1). All patients had negative surgical margins for neoplasia and more than 12 resected lymph nodes. The tumors were between 1 and 9 cm from the anal margin.

Conclusion: Total transanal mesorectal excision has been shown to be a viable method for oncologic resection of locally advanced rectal cancer with curative intent.

© 2019 Sociedade Brasileira de Coloproctologia. Published by Elsevier Editora Ltda. This is an open access article under the CC BY-NC-ND license (<http://creativecommons.org/licenses/by-nc-nd/4.0/>).

* Corresponding author.

E-mail: guiinacioneiva@hotmail.com (G.I. Neiva).

<https://doi.org/10.1016/j.jcol.2019.09.004>

2237-9363/© 2019 Sociedade Brasileira de Coloproctologia. Published by Elsevier Editora Ltda. This is an open access article under the CC BY-NC-ND license (<http://creativecommons.org/licenses/by-nc-nd/4.0/>).

Excisão total do mesorreto por via transanal (TaTME): sistematização e resultados mediatos em dez pacientes

R E S U M O

Palavras-chave:

TaTME

Excisão total do mesorreto

Cancer retal

Cirurgia colorretal

Cirurgia transanal

Contexto: A excisão total do mesorreto por via transanal é uma abordagem crânio-caudal para a realização de ressecção minimamente invasiva do reto e tecidos perirretais em monobloco. É adequada para pacientes com câncer de reto médio e distal confinados ao envelope mesorretal. Aqui relatamos uma série de pacientes submetidos à excisão total do mesorreto por via transanal.

Métodos: Dez pacientes foram selecionados para serem submetidos à excisão total do mesorreto por via transanal utilizando a plataforma SILS-Port[®]. Todos os pacientes eram portadores de câncer retal de localização extraperitoneal. O acesso abdominal para mobilização do cólon proximal, em todos os casos, foi realizado por laparoscopia. Como regra, a retirada do espécime cirúrgico, em nove casos, ocorreu por via transanal.

Resultados: Durante um período de 41 meses, 10 pacientes foram submetidos à excisão total do mesorreto por via transanal com intenção curativa. A indicação primária para excisão total do mesorreto transanal foi o câncer de reto médio e distal, localmente invasor, mas confinado ao envelope mesorretal. A mediana de idade dos pacientes com câncer de reto no momento da cirurgia foi de 61 anos (média de 59,4 anos, faixa de 22–78 anos), sendo 80% (8) do sexo feminino e 20% (2) do sexo masculino. A mediana do tempo cirúrgico foi de 305' (média de 314', intervalo de 260–420'). A mediana do tempo de permanência pós-operatória foi de cinco dias (média de 7,3 dias, intervalo de 3–23 dias). Não houve mortalidade pós-operatória. As complicações cirúrgicas incluíram íleo paralítico (n = 1), paresia vesical (n = 1) e estenose de ileostomia (n = 1). Todos os pacientes tiveram margens cirúrgicas negativas para neoplasia e mais de 12 linfonodos ressecados. Os tumores distavam de 1 a 9 cm da margem anal.

Conclusão: A excisão total do mesorreto transanal demonstrou-se um método viável para a ressecção oncológica de câncer de reto localmente avançado com intenção curativa.

© 2019 Sociedade Brasileira de Coloproctologia. Publicado por Elsevier Editora Ltda. Este é um artigo Open Access sob uma licença CC BY-NC-ND (<http://creativecommons.org/licenses/by-nc-nd/4.0/>).

Introduction

Colorectal cancer is the third most common type of cancer in the world¹ and, considering only the extraperitoneal compartment, it presents unique surgical challenges. Total Mesorectal Excision (TME) is the gold standard for surgical management of rectal cancer.² Neoadjuvant therapy, combined with quality surgical resection of rectal cancer with neoplasia-free distal and circumferential resection margins, can improve the recurrence rate and disease-free survival.^{3,4} These oncological benefits were primarily shown with open surgery and are currently established with laparoscopy.⁴⁻⁶

Pelvic dissection and mobilization of the rectum and the entire mesorectal envelope can be a challenging procedure due to patient and tumor variables.⁷ Male patients, obese patients, anteriorly located tumors, large tumors with advanced T Stage, as well as instrumentation and pelvic exposure limitations may affect dissection during open or laparoscopic TME. Inadequate dissection increases the risk of surgical margin involvement.^{8,9} Although some groups have successfully used the robotic approach to reduce these risks, there is a paucity of data on the superiority of robotics regarding cancer outcomes to date.¹⁰

The need to overcome these challenges motivated surgeons to develop alternative techniques in order to successfully perform rectal oncologic dissection.¹¹ TaTME is not a recent surgical approach, but rather a combination of established techniques, including Transanal Endoscopic Microsurgery (TEM), Transabdominal-Transanal (TATA) operation, and Transanal minimally invasive surgery (TAMIS).¹¹ The first case of laparoscopy-guided TaTME was published in 2010.¹² Since then, several studies have shown that this technique can be safely performed and preserves the TME oncologic principles.¹³⁻¹⁵ Similarly, we report our series of 10 patients undergoing TaTME, demonstrating the safety and viability of TaTME in extraperitoneal rectal tumors.

Methods

Between January 2015 and December 2018, 10 patients with histological diagnosis of rectal adenocarcinoma, located within 10 cm of the anal margin, underwent TaTME in our institution. Only one patient did not undergo neoadjuvant therapy, as she presented with Stage I lesion, but with indication for total proctocolectomy due to Familial Adenomatous Polyposis (FAP).

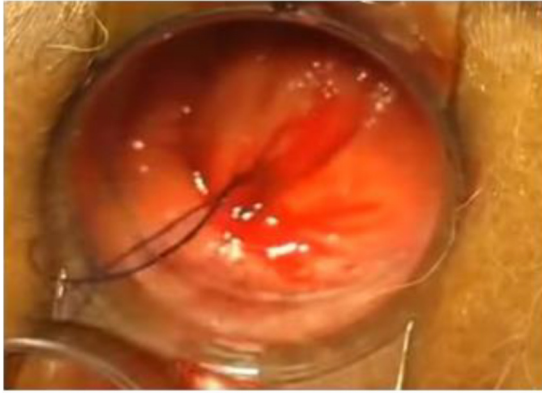

Fig. 1 – Rectal closure above the pectineal line.

Thoracoabdominal Computed Tomography (CT) and pelvic Magnetic Resonance Imaging (MRI) were routinely used for patient staging. In the Stage I patient, anorectal ultrasound was also used for assessment of anal canal morphology. All subjects underwent complete videocolonoscopy examination, with synchronous lesions found in one patient. Serum Carcinoembryonic Antigen (CEA) levels completed the staging process.

Anterograde colon preparation with 10% mannitol solution and adequate antibiotic prophylaxis were used in all patients.

In patients undergoing neoadjuvant therapy, clinical imaging and endoscopic restaging was performed approximately 8 weeks after its completion and surgery was performed between 12 and 16 weeks after the end of radiotherapy.

All surgeries followed the same standardization, and the abdominal and transanal times were performed by the same team in succession. The colorectal surgeon (FAS) was the same for all procedures and the assistants had the same training or were resident in the specialty. Abdominal surgical time always occurred by laparoscopy, with a mid-lateral approach, respecting the oncological parameters of resection and releasing the splenic flexion of the colon in all cases. Pelvic dissection was interrupted at the level of peritoneal reflection.

After the abdominal time, the surgical fields and laparoscopic material were changed, and the patient was placed in the lithotomy position to initiate the transanal time. In all subjects, a purse-string suture was performed about two centimeters above the pectineal line under direct vision, using the portal included in the EEA HEM[®] stapler kit (Fig. 1). Subsequently, the SILS[™] Port platform (Medtronic Inc., Dublin, Ireland) was used for transanal access (Fig. 2), combined with laparoscopic abdominal access.

A CO₂ insufflation pneumoperitoneum was then made at a controlled pressure of 12 mmHg. This maneuver allowed the delimitation of the perirectal avascular planes, which were dissected upwards and circumferentially, freeing the surgical specimen.

After a careful review of hemostasis, the specimen was removed transanally (Fig. 3), except in one case where the tumor was very large and had to be removed by a low transverse abdominal incision (Pfannenstiel incision).

In 8 cases it was possible to perform stapled anastomosis with EEA HEM[®] 33 mm–4.8 mm stapler (Medtronic Inc,

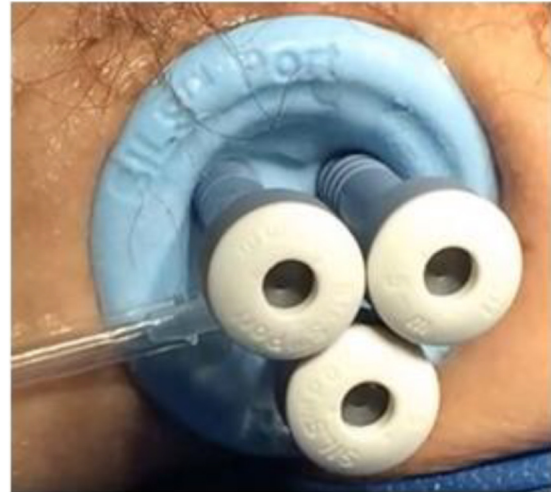

Fig. 2 – SILS[™] Port device inserted.

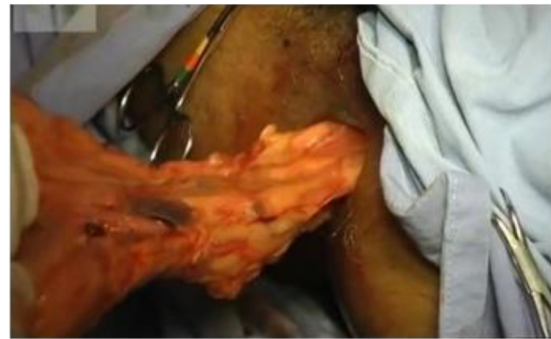

Fig. 3 – Transanal surgical specimen removal.

Dublin, Ireland). In these cases, shortly after the specimen removal, suture in the remnant colon bag was performed and the stapler warhead was fixed. The EEA HEM[®] anoscope portal was then placed and fixed to the skin and the distal stump pouch was sutured. Finally, the warhead was attached, followed by the stapler closure (Fig. 4a-c), and the pneumoperitoneum was redone. The position of the lowered colon was checked and a final revision of the abdominal cavity was performed, as well as the repair of the ileum loop to make a protective ileostomy. Then, pneumoperitoneum was undone, stapling was performed, and stapled line was checked, transanally, in order to make reinforcement and/or hemostatic points whenever necessary.

Finally, in all cases in which the anastomosis could be performed, a loop ileostomy was performed in the right iliac fossa, which was maintained for three months after the procedure.

In one case that required the association of an intersphincteric dissection and partial en-bloc resection of the sphincter, a circumferential incision with a monopolar electrocautery was performed along the pectineal line and dissection extending from the intersphincter space to the perirectal planes, with subsequent placement of the SILS port platform. For intersphincteric resection, a Lone Star[®] retractor (CooperSurgical, Trumbull, Connecticut, USA) was also used. In this case, a manual coloanal anastomosis was performed.

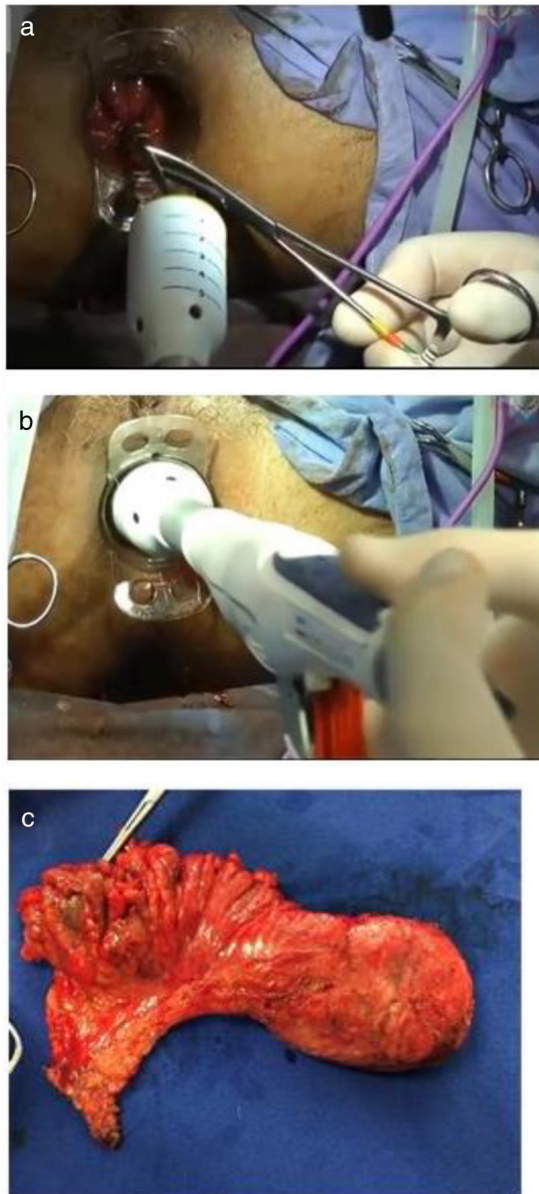


Fig. 4 – (a) Stapler coupling; (b) Stapling; (c) Surgical specimen.

Results

Over a 41-month period, 10 patients underwent TaTME with curative intent. The median age of patients at the time of surgery was 61 years (mean 59.4 years, range 22–78 years), with 80% (8) being female. The median surgical time was 305 min (range 260–420 min). In 8 patients, a stapled colorectal anastomosis was performed, in one case (P2) a definitive ileostomy was performed after total proctocolectomy, as a short intestinal mesentery was observed, which made it impossible to descend the ileal pouch for ileoanal anastomosis.

In one case (P10) requiring intersphincteric resection, manual coloanal anastomosis was performed.

The median postoperative length of stay was five days (mean 7.3 days, range 3–23 days). Surgical complications included paralytic ileus (n=1), bladder paresis (n=1), and ileostomy stenosis (n=1). One patient (P2) had a complication due to anesthetic intervention (left iliac artery thrombosis secondary to femoral artery puncture for invasive blood pressure monitoring – invasive blood pressure catheter), with the longest hospital stay in the series.

All patients had distal, proximal, and circumferential margins free of neoplasia and more than 12 lymph nodes resected in surgical specimens.

Tumors were 1–9 cm from the anal margin. Pathological staging ranged from Stage I to III, with 60% of the lesions related to parietal invasion and classified as T3 lesions.

Mean blood loss was not assessed, but no patient required perioperative blood transfusion.

There were no cases of conversion to open surgery, and one patient had ileostomy stenosis in the sixth postoperative week, which was redone.

Table 1 shows the perioperative and postoperative parameters of all patients.

Discussion

In recent years, the treatment of lower rectal cancer has been modified in order to increase the rate of sphincter preservation.^{16,17} Since the publication by Heald and Ryall,² TME has been accepted worldwide as the gold standard surgical technique for rectal cancer resection. Although the standardization of TME surgery is well established and widespread, some studies still report incomplete mesorectum after pathological examination of rectal specimens in patients undergoing rectal cancer surgery performed with this technique.^{18,19} Even in experienced hands, rectal resection with TME may be a challenge, especially in male patients with narrow pelvis, obese patients, and in large tumors.^{8,9,11}

Under these circumstances, the distal rectum dissection through the abdomen (by laparotomy or laparoscopy) is a difficult task, with an increased risk of incomplete resection and involvement of circumferential and distal margins. The main difficulty lies in the exposure of the surgical field and plane of dissection, which is at an angle to the plane of surgical view, often inaccessible.²⁰ In the transanal approach, this dissection is simplified because the surgeon's vision is on the same axis as the lower-middle rectum, allowing resection under direct vision, better identification of the mesorectal anatomical planes, and accurate determination of the distal resection margin.²⁰

In this series, we addressed the abdominal and transanal approach times with the same team due to the unavailability of equipment and other surgeons that would allow the simultaneous approach, which has the benefit of shorter operating time, early ligation of the vascular pedicle, and early clamping of the colon to prevent pneumocolon. The downside is that it needs more investment in equipment and a second trained staff available. Even so, the median time to surgery was 305 min, similar to the time in other studies with concomitant resection.²⁰⁻²³

Table 1 – Perioperative and postoperative parameters of patients undergoing TaTME.

Patient, gender, and age	Tumor location (distance from anal margin)	Postoperative staging	Surgical time	Complications	Hospitalization (days)
P1/F, 63a	6 cm	pT3N1	360 min	Adynamic ileus	6
P2/F, 22a	3 cm	pT2N0	420 min	Left iliac artery thrombosis	23
P3/F, 57a	7 cm	pT3N0	320 min	–	5
P4/F, 72a	5 cm	pT2N0	300 min	–	6
P5/F, 73a	7 cm	pT3N1	310 min	–	5
P6/F, 56a	7 cm	pT2N0	290 min	–	5
P7/F, 62a	4 cm	pT3N0	330 min	–	5
P8/F, 78a	9 cm	pT3N0	270 min	–	4
P9/M, 51a	8 cm	pT3N1	260 min	Ileostomy stenosis	11
P10/M, 60a	3 cm	pT1N0	280 min	Bladder paresis	3
Median 61a	6,5 cm	–	305 min	–	5

In this study, we demonstrated that the use of this new approach led to mortality and morbidity rates of 0% and 33%, respectively associated with the surgical procedure. These findings are consistent with the mortality and morbidity rates following rectal cancer resection reported in the literature. In a meta-analysis of 23 studies comparing open and laparoscopic resection for rectal cancer (4539 patients), Arezo et al.²⁴ reported a 1% mortality rate in the laparoscopic group and 2.4% in the open group and a global complication rate of 31.8% in the laparoscopic group and 35.4% in the open group. According to Tuech et al.²⁰ and Lee et al.,²¹ the cumulative rate of postoperative complications was around 30%–35%.

A point of concern in laparoscopic rectal surgery is the rectal transection stage, which is quite difficult in lower rectal lesions and may hinder cancer outcome in cases of inadequate distal margin, increasing the likelihood of local recurrence. It is noteworthy that, in TaTME, the first step is to close the rectal lumen distally to the tumor, thus having direct control of the distal margin. In our series, distal and circumferential resection margins were adequate in all patients.^{25–27} This data, despite the small number of cases in our study, is in line with the rates of 88% and 75% reported in the studies by Muratore et al.²⁸ (TaTME) and COREAN trial (transabdominal TEM),²⁹ respectively. Sixty percent of our patients had T3 tumors and we did not observed any T4 tumors. Although advanced tumors (T4) are not a contraindication to TaTME, there is a tendency to avoid such an approach in those types of lesions, which are associated with a higher conversion rate and positive resection margins.^{31,32}

The dehiscence rate of stapled or manual coloanal anastomosis after TEM ranges from 5% to 11%.^{16,17} In the present series there were no reports of such complication. The median length of hospital stay after TaTME was five days and there was no 30-day mortality after surgery, similar to other studies evaluated.^{20,21,23}

In our study, after TaTME procedure, no patient complained of severe postoperative fecal incontinence, even after intestinal transit reconstruction in the 9 cases where it was possible. However, preoperative and postoperative functional assessment was not systematically performed in the study population. Previous manometric analyzes of the effects of anal dilation after TEM indicated a decrease in sphincter tone ranging from 2.5% to 37%, compared with preoperative

manometric data, with complete postoperative recovery from clinical continence within 6–16 weeks.³⁰

We are aware of some limitations of the study. Our case series has a small sample. However, TaTME has proven to be a safe, feasible and reproducible procedure, providing good dissection quality and satisfactory oncologic results.

Conflicts of interest

The authors declare no conflicts of interest.

REFERENCES

- World Cancer Research Fund. Colorectal Cancer Statistics. <http://www.wcrf.org/int/cancer-facts-figures/data-specific-cancers/colorectal-cancer-statistics>. Accessed February 2, 2016.
- Heald RJ, Ryall RD. Recurrence and survival after total mesorectal excision for rectal cancer. *Lancet*. 1986;1:1479–82.
- MERCURY Study Group. Diagnostic accuracy of preoperative magnetic resonance imaging in predicting curative resection of rectal cancer: prospective observational study. *BMJ*. 2006;333:779–83.
- Martling A, Singnomklo T, Holm T, Rutqvist LE, Cedermark B. Prognostic significance of both surgical and pathological assessment of curative resection for rectal cancer. *Br J Surg*. 2004;91:1040–5.
- Jeong SY, Park JW, Nam BH, Kim S, Kang SB, Lim SB, et al. Open versus laparoscopic surgery for midrectal or low-rectal cancer after neoadjuvant chemoradiotherapy (COREAN trial): survival outcomes of an open-label, non-inferiority, randomized controlled trial. *Lancet Oncol*. 2014;15:767–74.
- van der Pas MH, Haglind E, Cuesta MA, Fürst A, Lacy AM, Hop WC, et al. Colorectal cancer Laparoscopic or Open Resection II (COLOR II) Study Group. Laparoscopic versus open surgery for rectal cancer (COLOR II): short-term outcomes of a randomised, phase 3 trial. *Lancet Oncol*. 2013;14:210–8.
- Araújo SE, Seid VE, Bertoncini A, Campos FG, Sousa A Jr, Nahas SC, et al. Laparoscopic total mesorectal excision for rectal cancer after neoadjuvant treatment: targeting sphincter-pre-serving surgery. *Hepatogastroenterology*. 2011;58:1545–54.
- Velthuis S, van den Boezem PB, van der Peet DL, Cuesta MA, Sietes C. Feasibility study of transanal total mesorectal excision. *Br J Surg*. 2013;100:828–31.

9. Rouanet P, Mourregot A, Azar CC, Carrere S, Gutowski M, Quenet F, et al. Transanal endoscopic proctectomy: an innovative procedure for difficult resection of rectal tumors in men with narrow pelvis. *Dis Colon Rectum*. 2013;56:408-15.
10. Halabi WJ, Kang CY, Jafari MD, Nguyen VQ, Carmichael JC, Mills S, et al. Robotic-assisted colorectal surgery in the United States: a nationwide analysis of trends and outcomes. *World J Surg*. 2013;37:2782-90.
11. Araujo SE, Crawshaw B, Mendes CR, Delaney CP. Transanal total mesorectal excision: a systematic review of the experimental and clinical evidence. *Tech Coloproctol*. 2015;19:69-82.
12. Sylla P, Rattner DW, Delgado S, Lacy AM. NOTES transanal rectal cancer resection using transanal endoscopic microsurgery and laparoscopic assistance. *Surg Endosc*. 2010;24:1205-10.
13. de Lacy AM, Rattner DW, Adelsdorfer C, Tasende MM, Fernández M, Delgado S, et al. Transanal natural orifice transluminal endoscopic surgery (NOTES) rectal resection: "down-to-up" total mesorectal excision (TME) - short-term outcomes in the first 20 cases. *Surg Endosc*. 2013;27:3165-72.
14. Dumont F, Goéré D, Honoré C, Elias D. Transanal endoscopic total mesorectal excision combined with single-port laparoscopy. *Dis Colon Rectum*. 2012;55:996-1001.
15. Leroy J, Barry BD, Melani A, Mutter D, Marescaux J. No-scar transanal total mesorectal excision: the last step to pure NOTES for colorectal surgery. *JAMA Surg*. 2013;148:226-30.
16. Rullier E, Denost Q, Vendrely V, Rullier A, Laurent C. Low rectal cancer: classification and standardization of surgery. *Dis Colon Rectum*. 2013;56:560-7.
17. Park JS, Choi GS, Jun SH, Hasegawa S, Sakai Y. Laparoscopic versus open intersphincteric resection and coloanal anastomosis for low rectal cancer. *Ann Surg*. 2011;254:941-6.
18. Maslekar S, Sharma A, Macdonald A, Gunn J, Monson JR, Hartley JE. Mesorectal grades predict recurrences after curative resection for rectal cancer. *Dis Colon Rectum*. 2007;50:168-75.
19. Baik SH, Kim NK, Lee KY, Sohn SK, Cho CH, Kim MJ, et al. Factors influencing pathologic results after total mesorectal excision for rectal cancer: analysis of consecutive 100 cases. *Ann Surg Oncol*. 2008;15:721-8.
20. Tuech JJ, Karoui M, Lelong B, De Chaisemartin C, Bridoux V, Manceau G, et al. A step toward NOTES total mesorectal excision for rectal cancer endoscopic transanal proctectomy. *Ann Surg*. 2015;261:228-33.
21. Lee GC, Sylla P. Shifting paradigms in minimally invasive surgery: applications of transanal natural orifice transluminal endoscopic surgery in colorectal surgery. *Clin Colon Rectal Surg*. 2015;28:181-93.
22. Deijen CL, Tsai A, Koedam TW, Veltcamp Helbach M, Sietes C, Lacy AM, et al. Clinical outcomes and case volume effect of transanal total mesorectal excision for rectal cancer: a systematic review. *Tech Coloproctol*. 2016;20:811-24.
23. Foo DC, Choi HK, Wei R, Yip J, Law WL. Transanal total mesorectal excision with single-incision laparoscopy for rectal cancer. *JLS*. 2016;20, e2016.00007.
24. Arezzo A, Passera R, Scozzari G, Verra M, Morino M. Laparoscopy for rectal cancer reduces short-term mortality and morbidity: results of a systematic review and meta-analysis. *Surg Endosc*. 2013;27:1485-502.
25. Targarona EM, Balague C, Pernas JC, Martinez C, Berindoague R, Gich I, et al. Can we predict immediate outcome after laparoscopic rectal surgery? Multivariate analysis of clinical, anatomic, and pathologic features after 3-dimensional reconstruction of the pelvic anatomy. *Ann Surg*. 2008;247:642-9.
26. Atallah S, Albert M, DeBeche-Adams T, Nassif G, Polavarapu H, Larach S. Transanal minimally invasive surgery for total mesorectal excision (TAMIS-TME): a stepwise description of the surgical technique with video demonstration. *Tech Coloproctol*. 2013;17:321-5.
27. Fernandez-Hevia M, Delgado S, Castells A, Tasende M, Momblan D, Díaz del Gobbo G, et al. Transanal total mesorectal excision in rectal cancer: short term outcomes in comparison with laparoscopic surgery. *Ann Surg*. 2015;261:221-7.
28. Muratore A, Mellano A, Marsanic P, De Simone M. Transanal total mesorectal excision (taTME) for cancer located in the lower rectum: short- and mid-term results. *Eur J Surg Oncol*. 2015;41:478-83.
29. Kang SB, Park JW, Jeong SY, Nam BH, Choi HS, Kim DW, et al. Open versus laparoscopic surgery for mid or low rectal cancer after neoadjuvant chemoradiotherapy (COREAN trial): short-term outcomes of an open-label randomized controlled trial. *Lancet Oncol*. 2010;11:637-45.
30. Herman RM, Richter P, Walega P, Popiela T. Anorectal sphincter function and rectal barostat study in patients following transanal endoscopic microsurgery. *Int Colorectal Dis*. 2001;16:370-6.
31. Rouanet P, Mourregot A, Azar CC, Carrere S, Gutowski M, Quenet F, et al. Transanal endoscopic proctectomy: an innovative procedure for difficult resection of rectal tumors in men with narrow pelvis. *Dis Colon Rectum*. 2013;56:408-15.
32. Björn MX, Perdawood SK. Transanal total mesorectal excision - a systematic review. *Dan Med J*. 2015;62:A5105.